



UKS
Universitätsklinikum
des Saarlandes

09.09.2022

How to Start Aortic Cusp Repair

H.-J. Schäfers

Dept. of Thoracic and Cardiovascular Surgery
Saarland University Medical Center

When to repair

Titel des Vortrags und Verfasser (bitte im Folienmaster anpassen)



reasonable

tricuspid/bicuspid valve, prolapse of 1 or 2 cusps

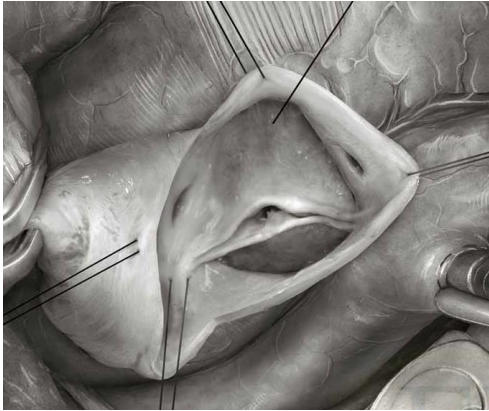
prolapse of 3 cusps, fenestrations, unicuspid av, retraction, active endocarditis

relevant retraction/calcium

?

!

uncertain



Operative Steps:

1. Patient Selection:

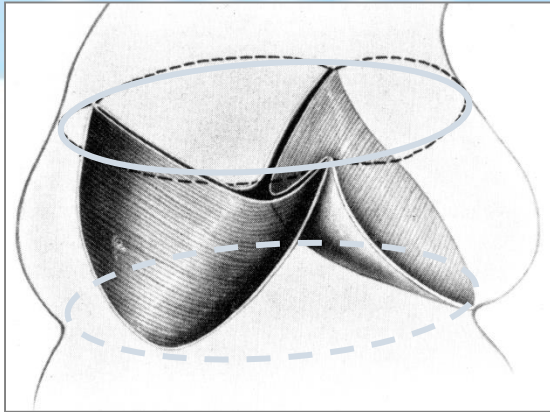
Bicuspid aortic valve

Normal root size

Orientation of commissures $> 150^\circ$

Minimal or absent calcification

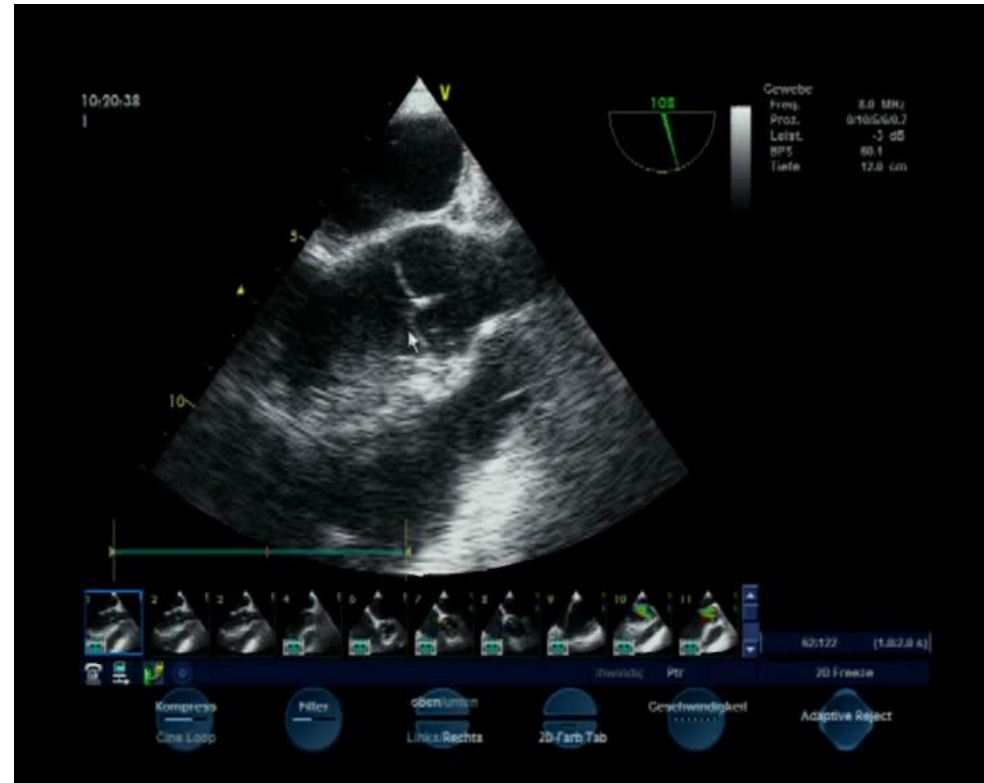
Complete fusion



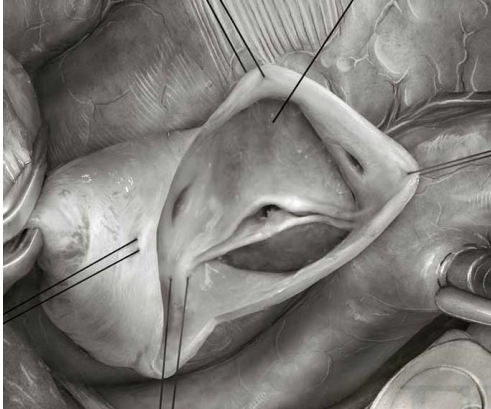
m Folienmaster anpassen)

Operative Steps:

Assessment:



Operative Steps:



2. Exposure:

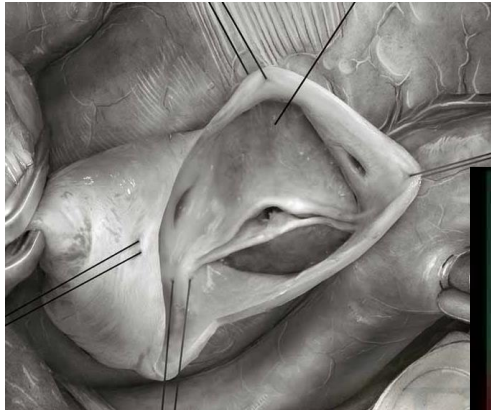
Standard cannulation

Transverse aortotomy (10 mm
above ST junction

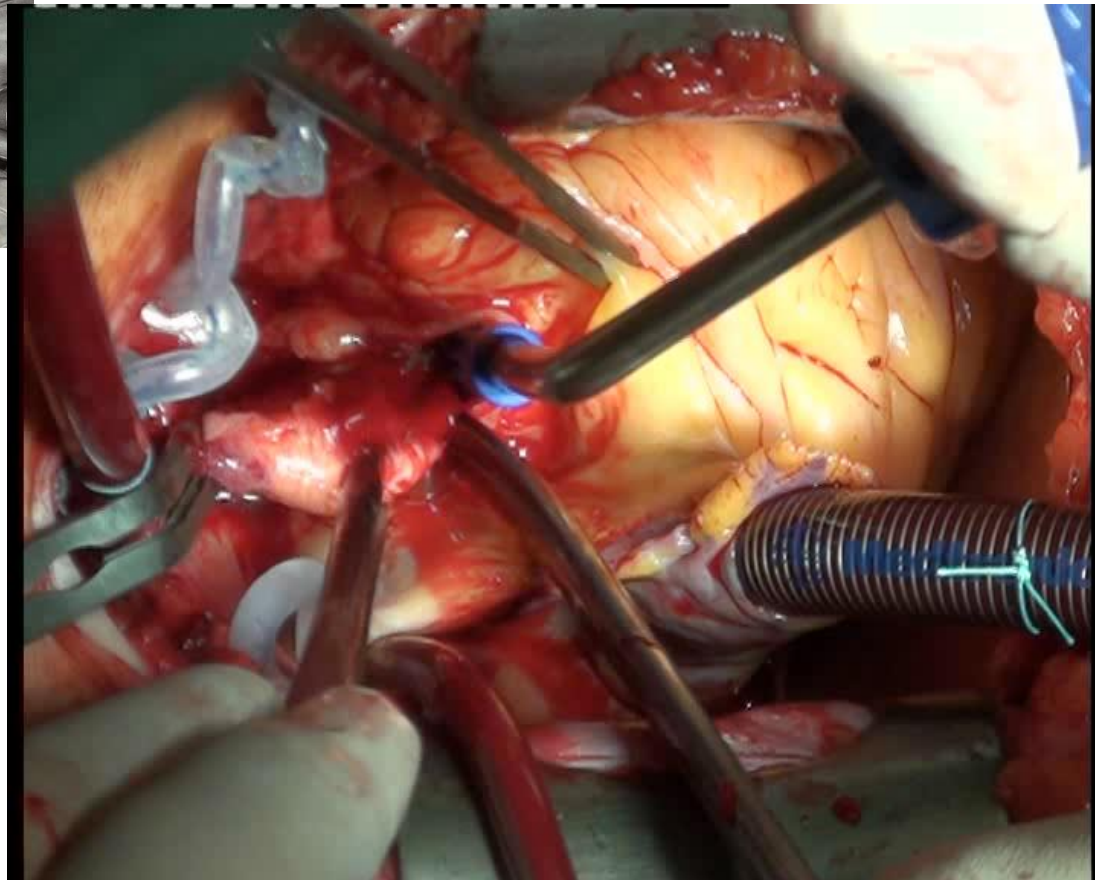
Traction sutures on commissures
in direction of commissures &
under tension

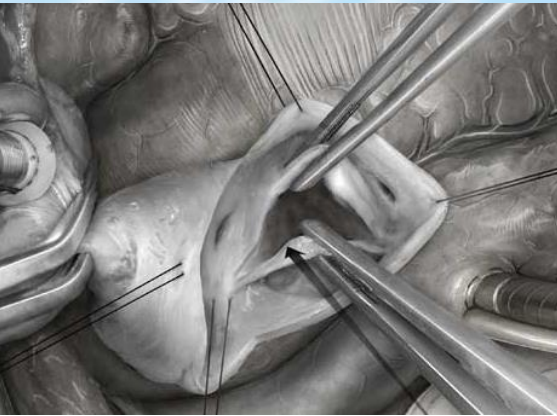
Titel des Vortrags und Verfasser (bitte im Folienmaske eingeben)

Operative Steps:



Exposure:





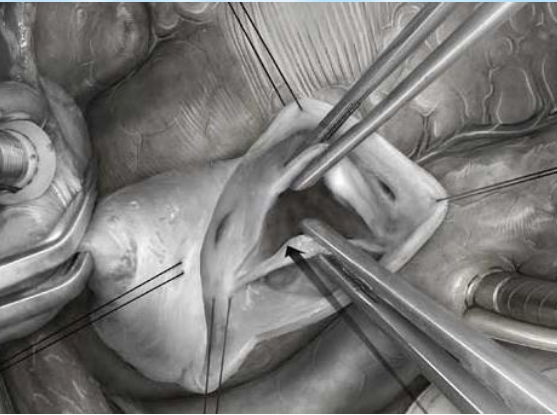
im Folienmaster anpassen)

Operative Steps:

4. Assessment of large (NC) cusp:

Geometric height (how much tissue?)

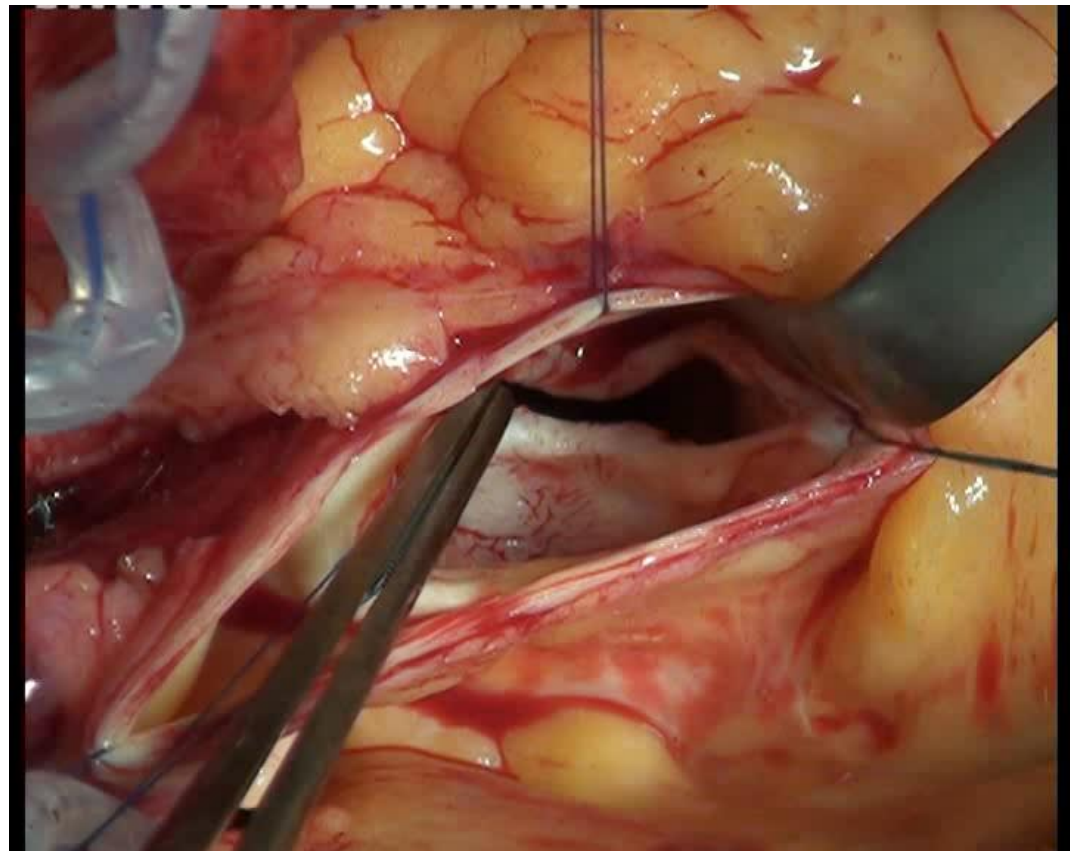
Effective height (cusp configuration)



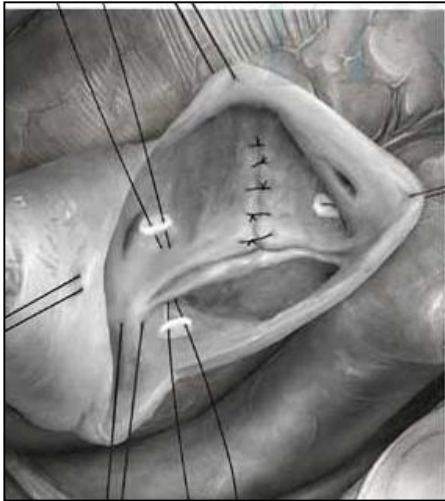im Folienmaster anpassen)

Operative Steps:

Assessment of large (NC) cusp:



Titel des Vortrags und Verfasser (bitte im Folienmaster anpassen)

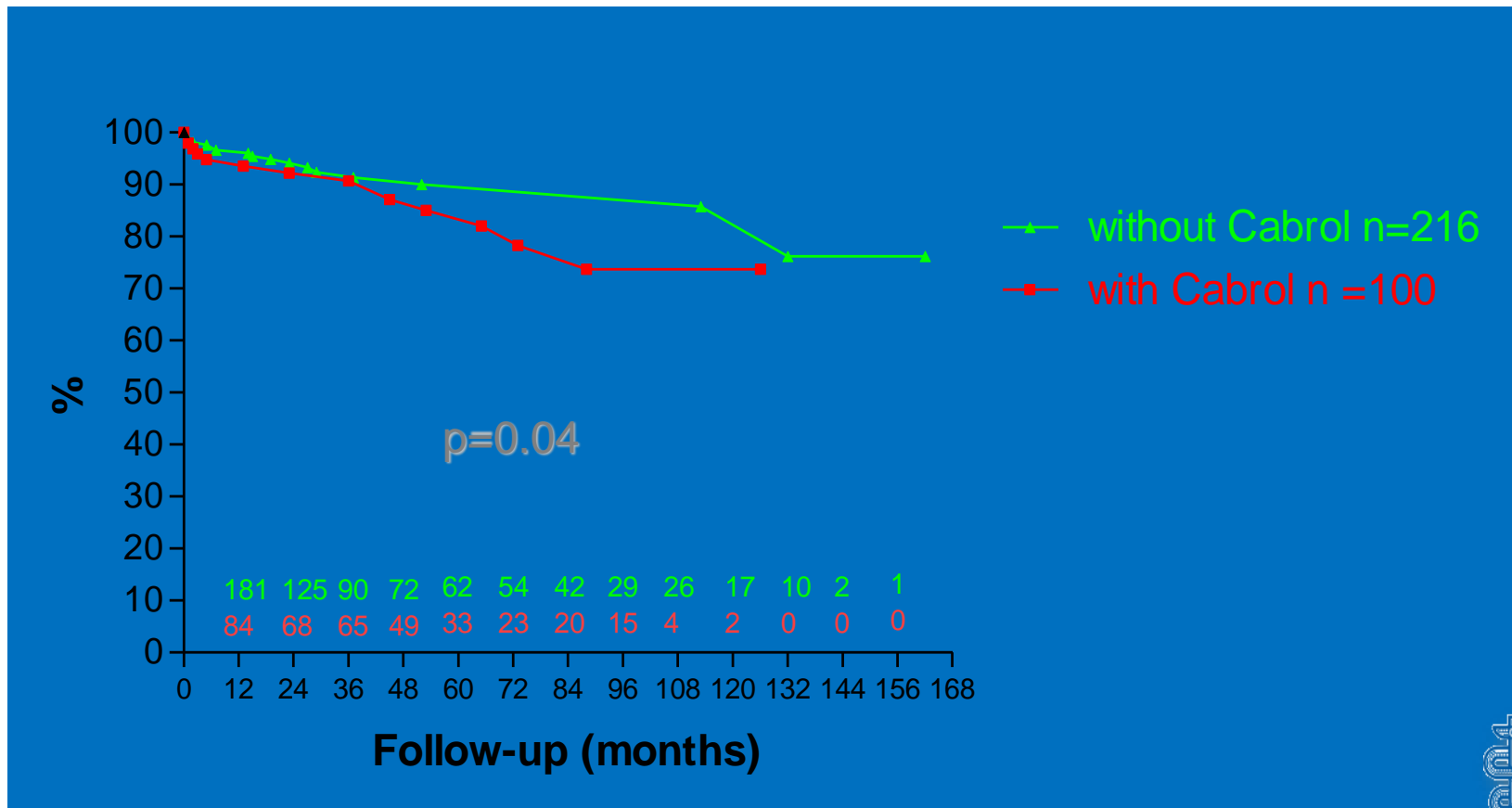


Operative Steps:

5. Correction of AV dilatation:

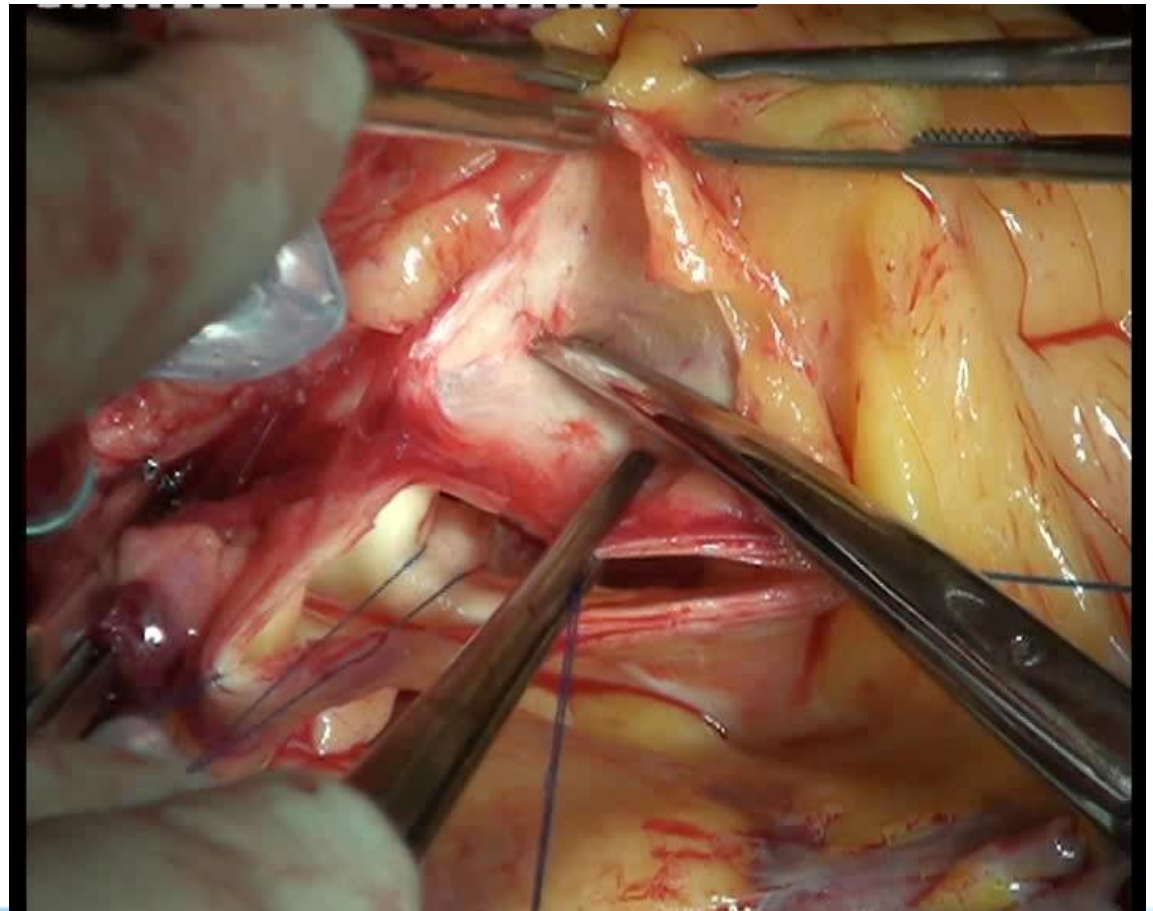
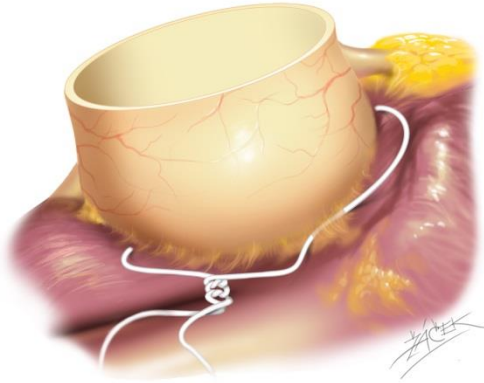
- ~~- Cabrol sutures (subcommissural plication)~~
- suture annuloplasty
- ring annuloplasty

Effect of Cabrol Sutures

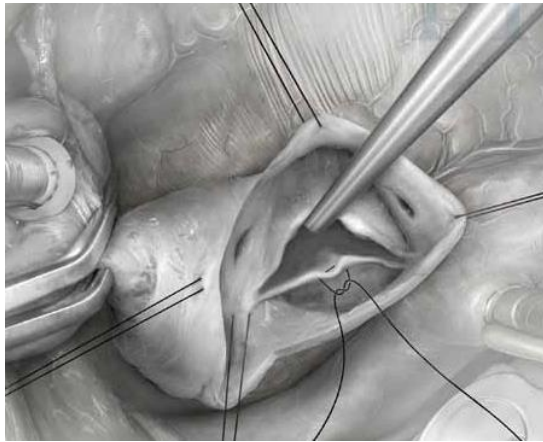


Titel des Vortrags und Verfasser (bitte im Folienmaster anpassen)

Operative Steps:



Operative Steps:



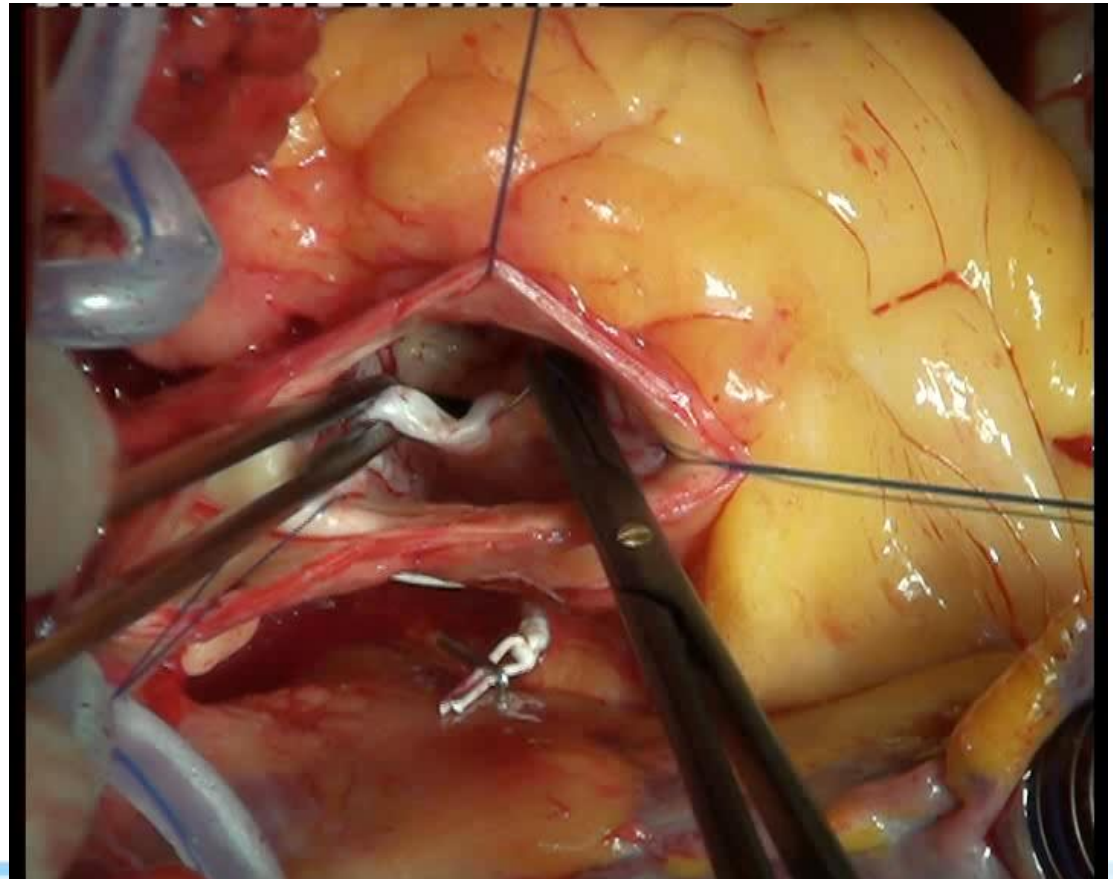
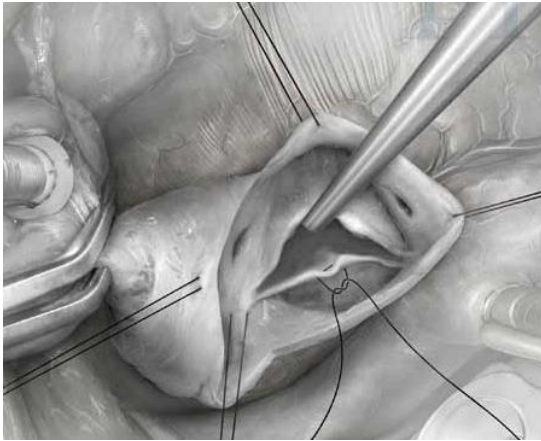
6. Correction of NC cusp prolapse:

- measure effective height
- plicate free margin
- ??

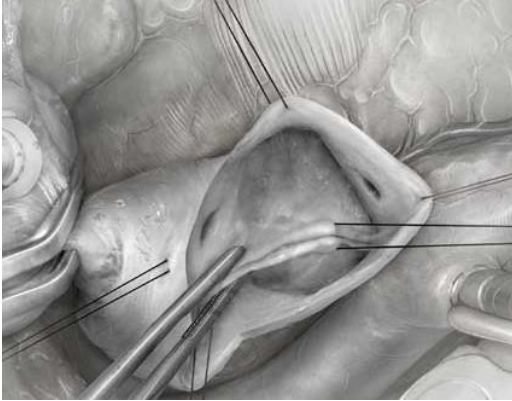
Titel des Vortrags und Verfasser (bitte im Folienmaster anpassen)

Operative Steps:

Correction of NC cusp prolapse:



Operative Steps:

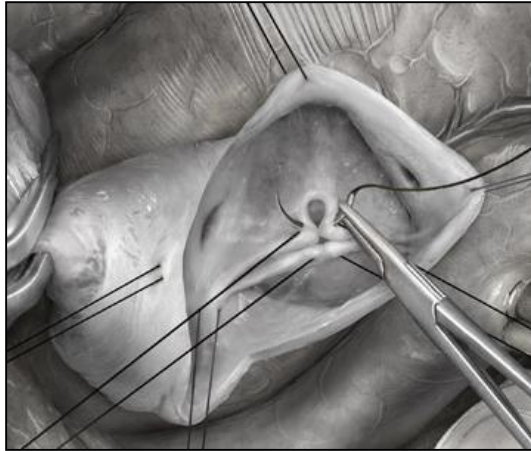


Assessment of fused cusp geometry (prolapse):

- stay sutures with equidistant lengths of NC/fused margins from each commissure

Titel des Vortrags und Verfasser (bitte im Folienmaster anpassen)

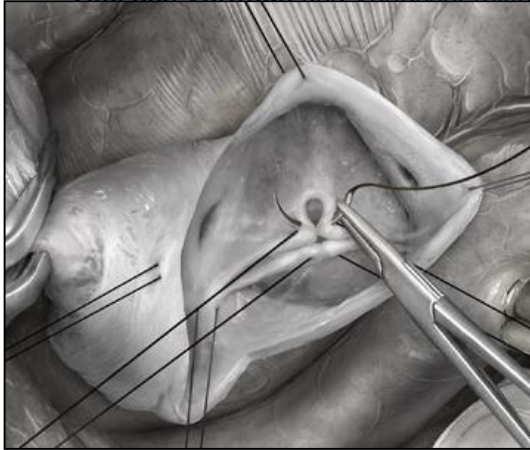
Operative Steps:



9. Correction of fused cusp geometry (prolapse):

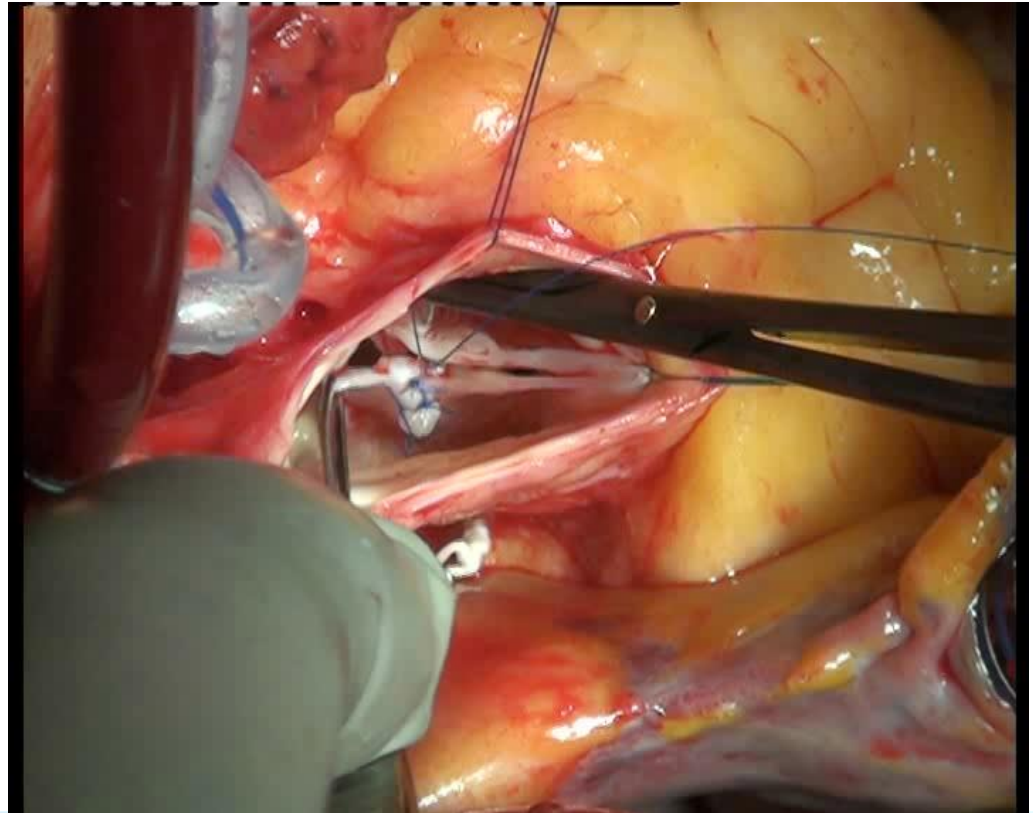
- plication of free margin
- triangular resection

Titel des Vortrags und Verfasser (bitte im Folienmaster anpassen)

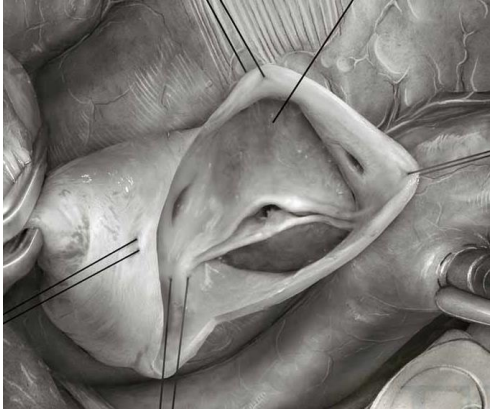


Operative Steps:

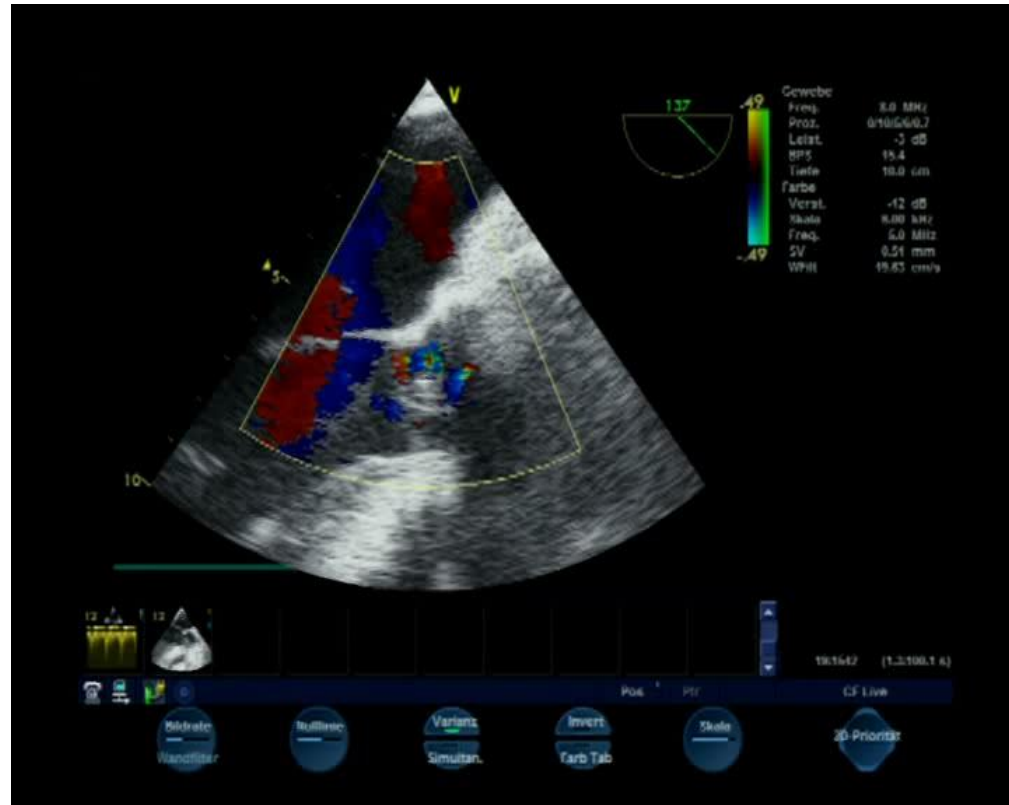
Correction of fused cusp geometry (prolapse):



Titel des Vortrags und Verfasser (bitte im Folienmaster anpassen)




Final check



Titel des Vortrags und Verfasser (bitte im Folienmaster anpassen)

Thank you for your attention



aortic-repair@uks.eu