Reconstrucion of the Aortic Valve and Root: A practical approach, September 18, 2019, Homburg-Saar, Germany

Echo assessment of AR and its mechanisms

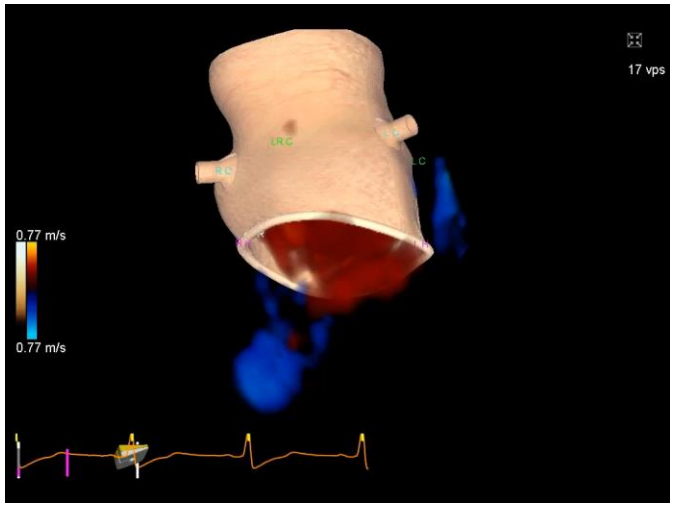

Nina Wunderlich

Kardiovaskuläres Zentrum Darmstadt

Echo assessment of AR and its mechanisms

- Anatomy of the AV/Ao root complex
- AV abnormalities
- Echo evaluation of the AV/Ao root complex

Echo assessment of AR and its mechanisms

- Anatomy of the AV/Ao root complex
- AV abnormalities
- Echo evaluation of the AV/Ao root complex

Anatomy of the AV/Ao root complex

Normal AV

Aortic valve

- 3 cusps of similar dimensions & 3 commissures of equal height
- The commissures nearly reach the STJ
- The number of commissures of normal height determines the number of cusps

Anatomy of the AV/Ao root complex

A functional unit

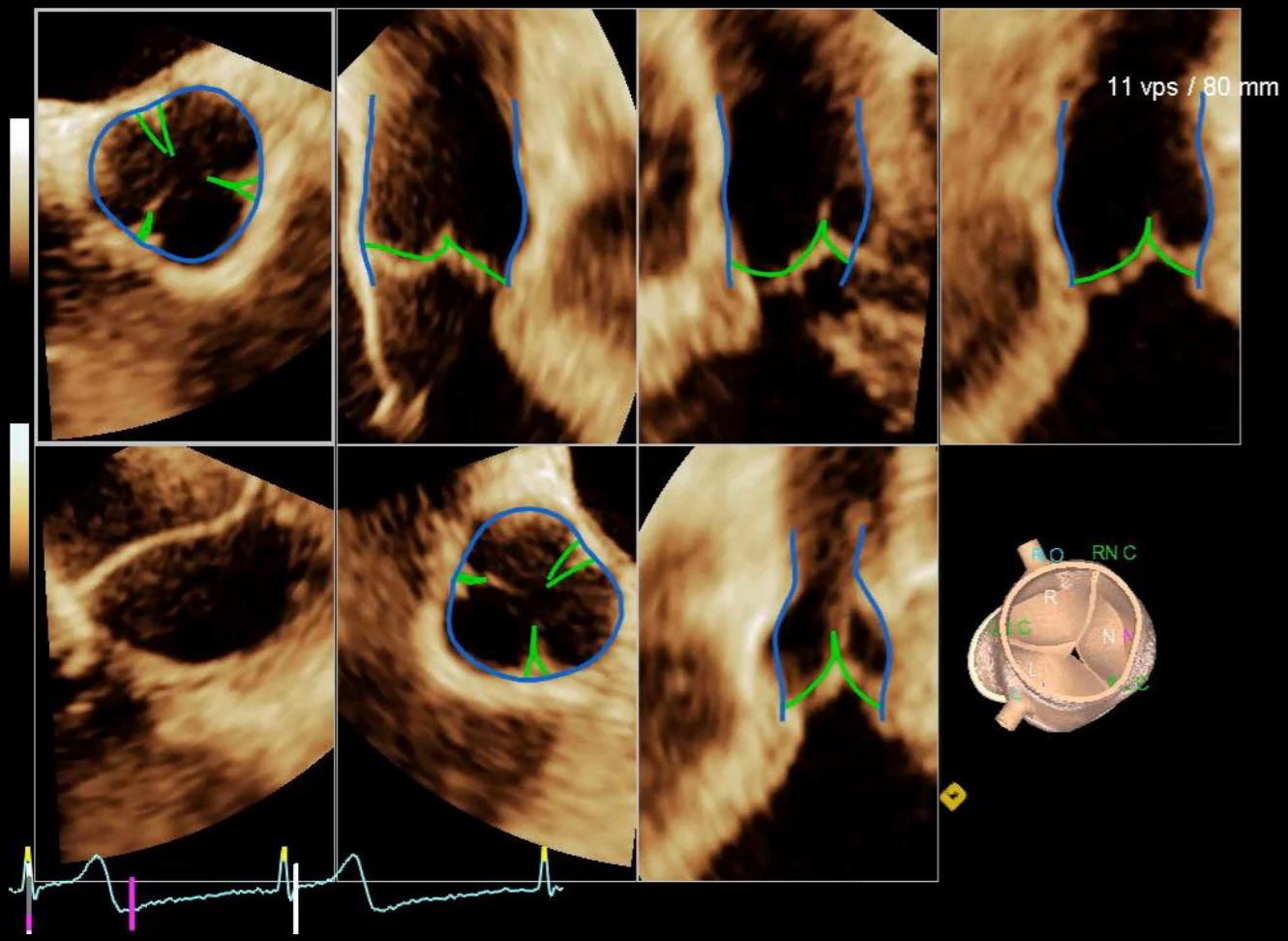

Anatomy of the AV/Ao root complex
A complex structure

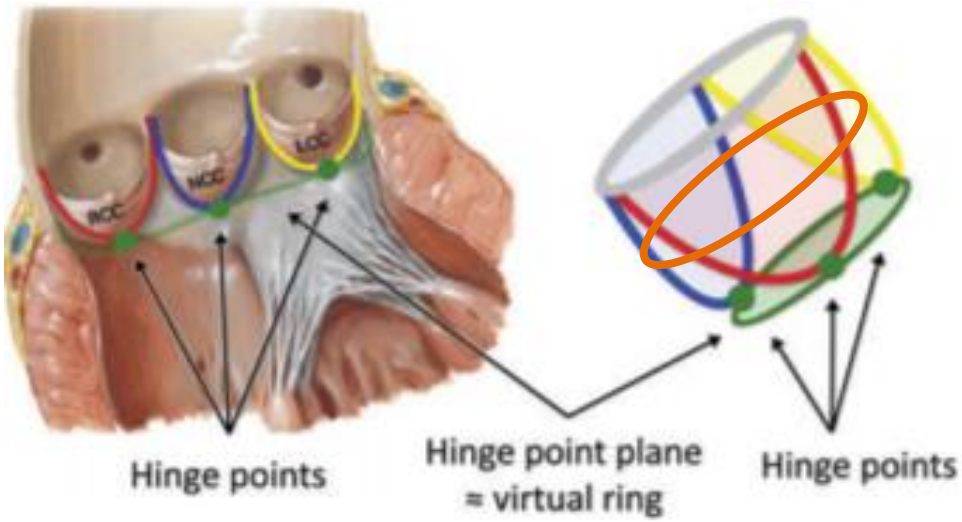

- The hinge points (nadirs of the cusps) define the plane of the virtual ring = basal aortic annulus = ventricular aortic junction
- The 3 cusps form a crown-like structure; the tips of the commissures nearly reach the STJ
- Circle with the max. diameter of the Sinus of Valsalva

Lang RM et al. EHJ-Cardiovascular Imaging (2015) 16, 233–271.

Anatomy of the AV/Ao root complex

The „virtual“ basal ring

The ventricular-aortic junction is the
transition of ventricular structures to the aortic wall

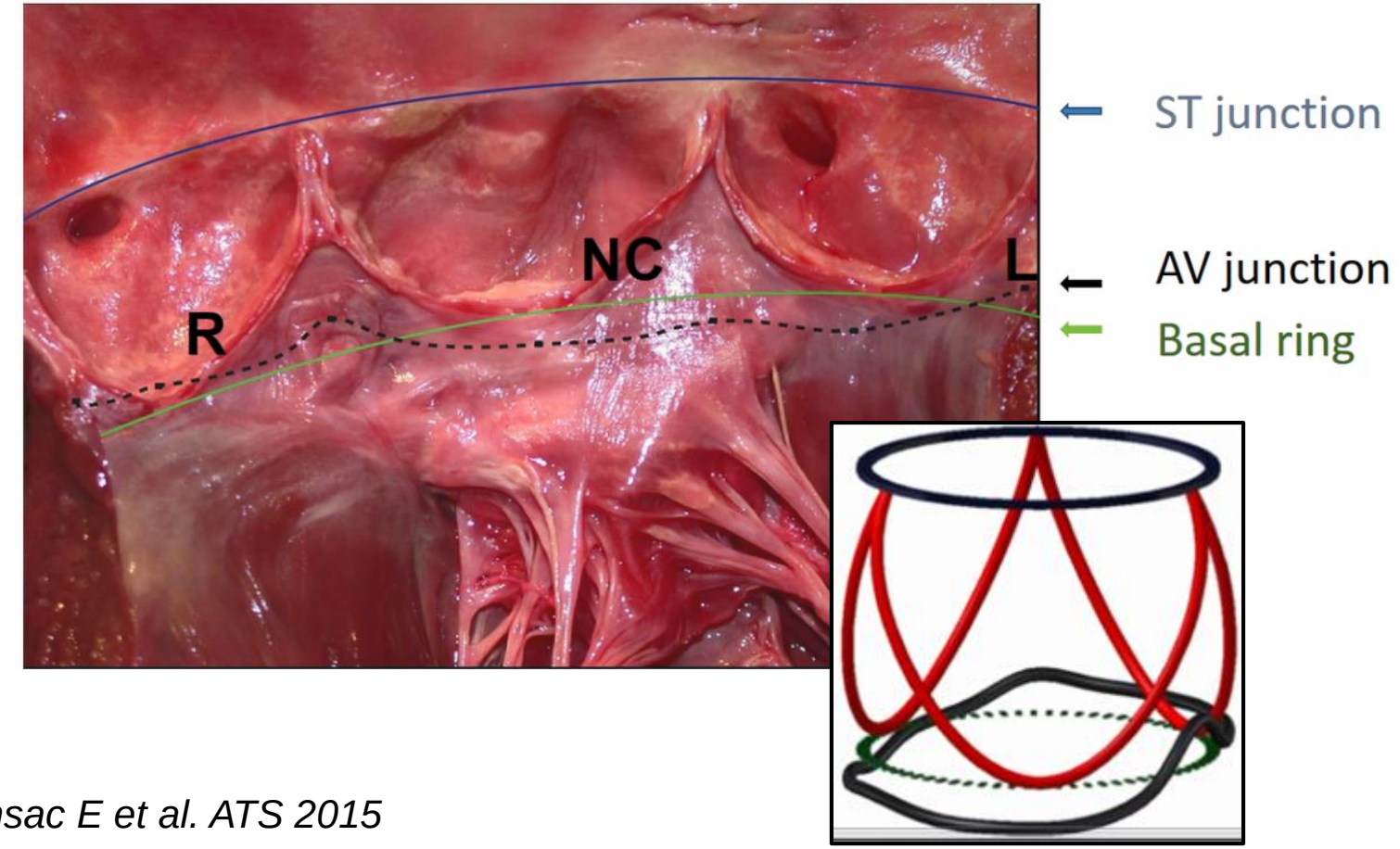

Lansac E et al. ATS 2015

Anatomy of the AV/Ao root complex
Characterizsation of cusp configuration

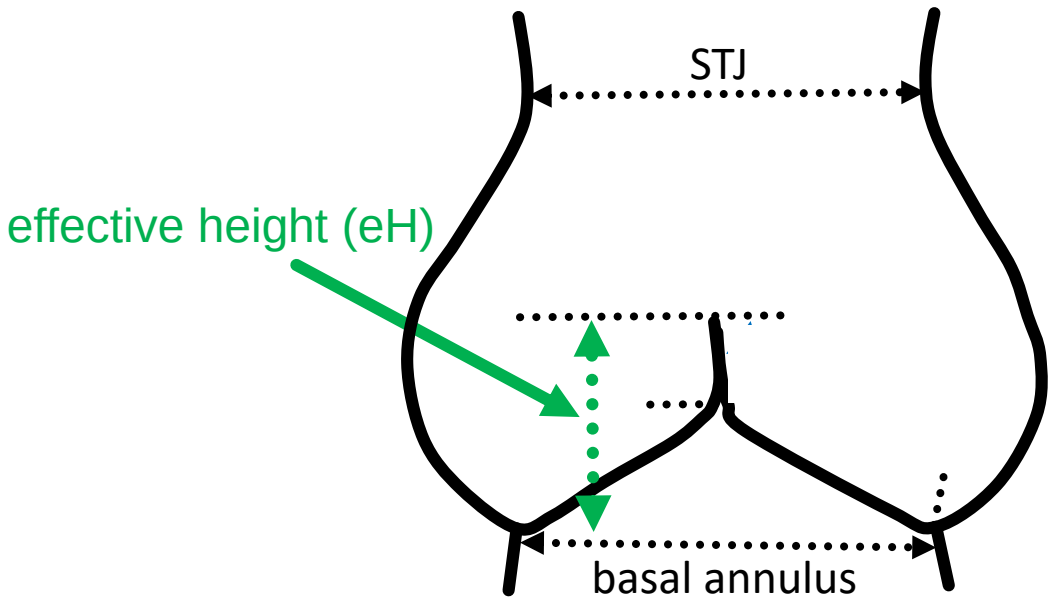

Cusp configuration is characterized by a height difference between the annular plane and the free margin of each cusp in diastole, termed “effective height” (eH),

Anatomy of the AV/Ao root complex
Characterizsation of cusp configuration

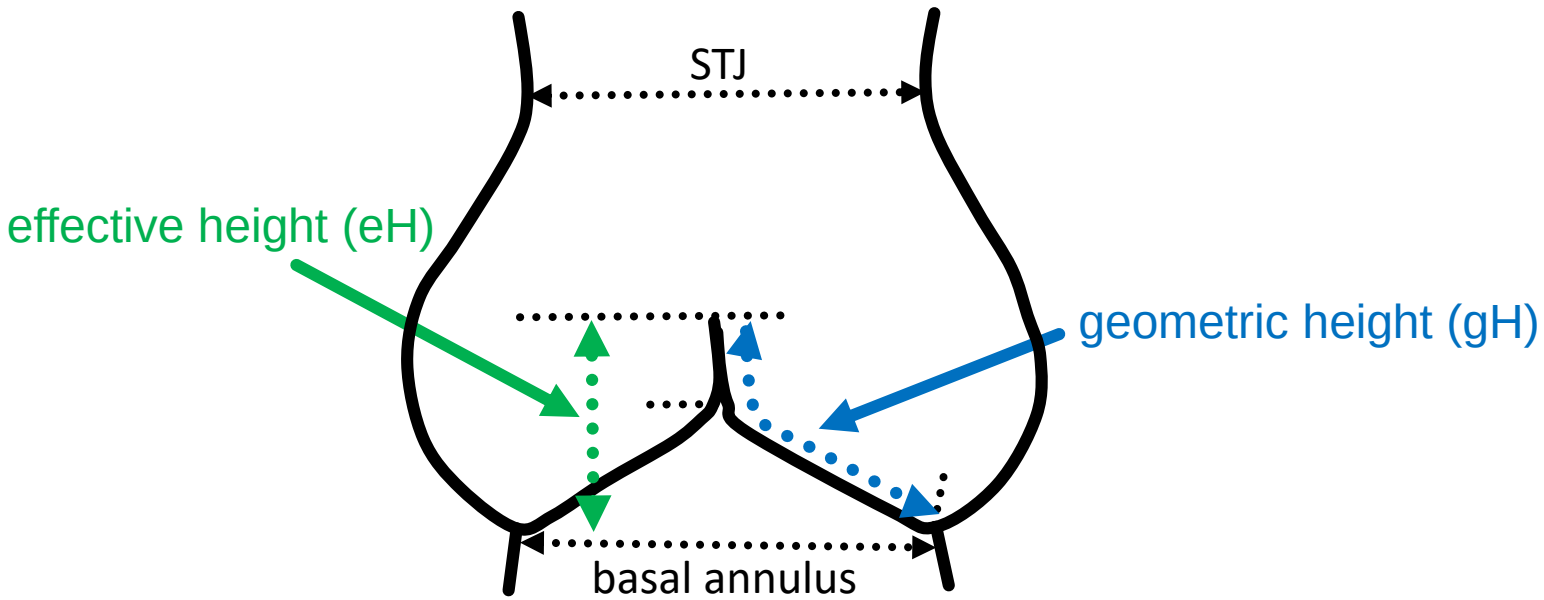

… and by the distance of the curved length of the respective cusp during diastole from the aortic insertion in the nadir of the sinus to the central part of the free margin, termed “geometric height” (gH).

Anatomy of the AV/Ao root complex

Characterizsation of cusp configuration

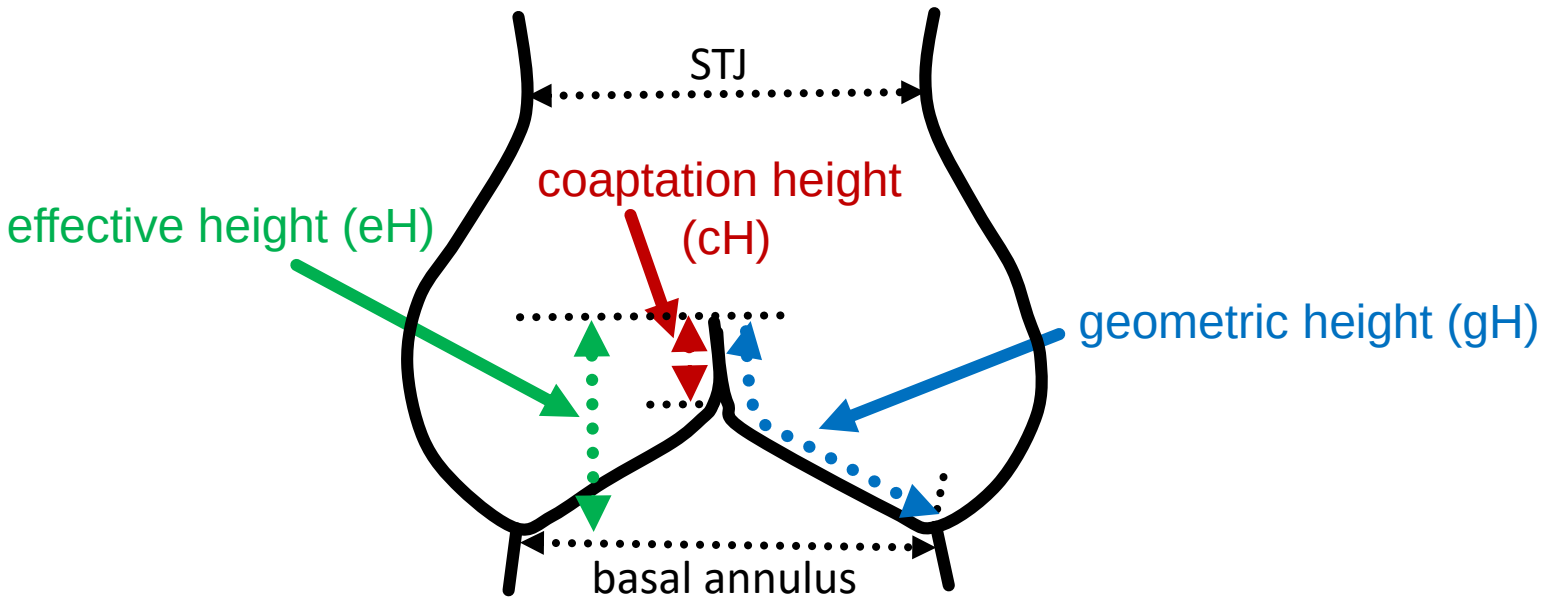

The coaptation of the cusps is also defined by coaptation length (=coaptation heighth: normally 2-4mm)

Echo assessment of AR and its mechanisms

- Anatomy of the AV/Ao root complex
- AV abnormalities
- Echo evaluation of the AV/Ao root complex

AV abnormalities- bicuspid AV

Classification of phenotypes

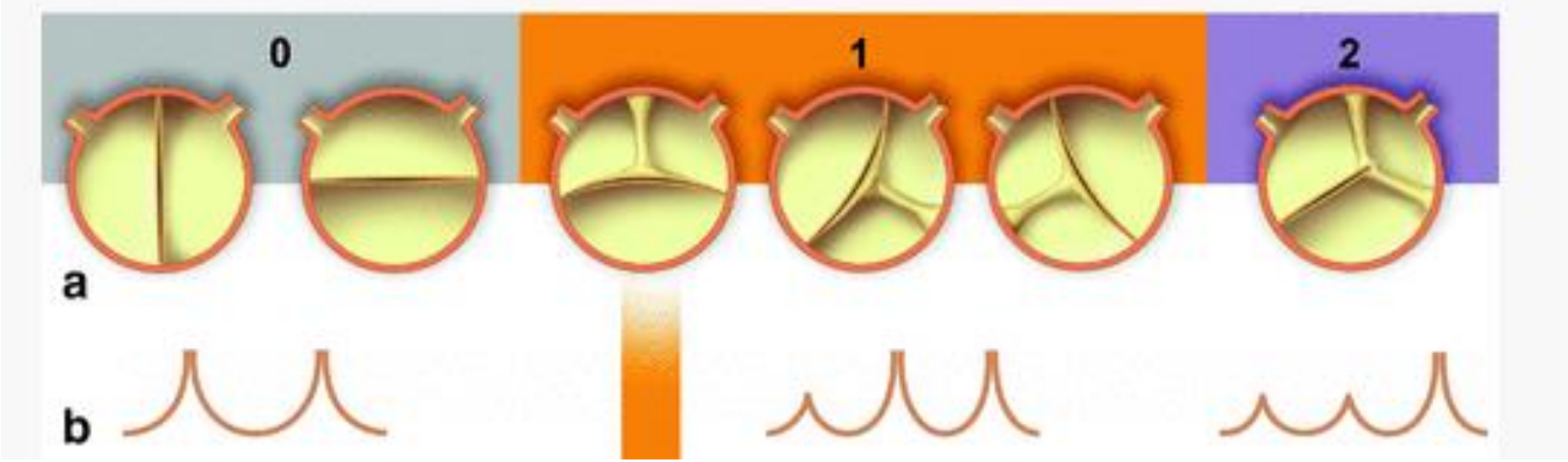

a.) Sievers classification:
Groups 0,1 and 2 are discriminated according to the number of raphes

b.) Vertically, the raphes are lower than functional commissures and do not reach the height of coronary ostia

- 2 opening commissures are present
- Most common : Type 1 (in 80% fusion of the LCC & RCC)
- Functional leaflets usually of unequl size

AV abnormalities- bicuspid AV

True bicuspid aortic valve

AV abnormalities- bicuspid AV

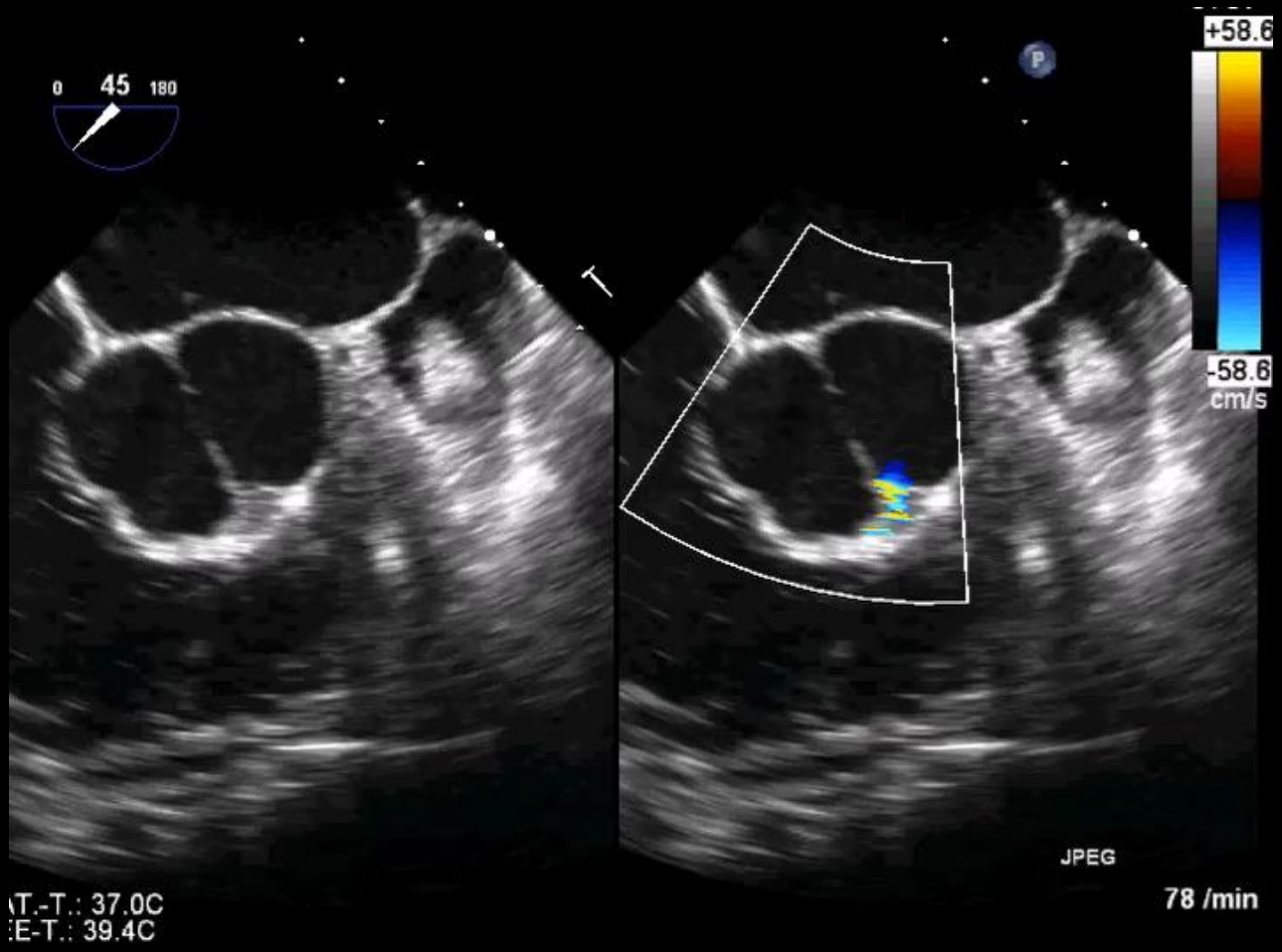

True bicuspid aortic valve

AV abnortmalities- bicuspid AV

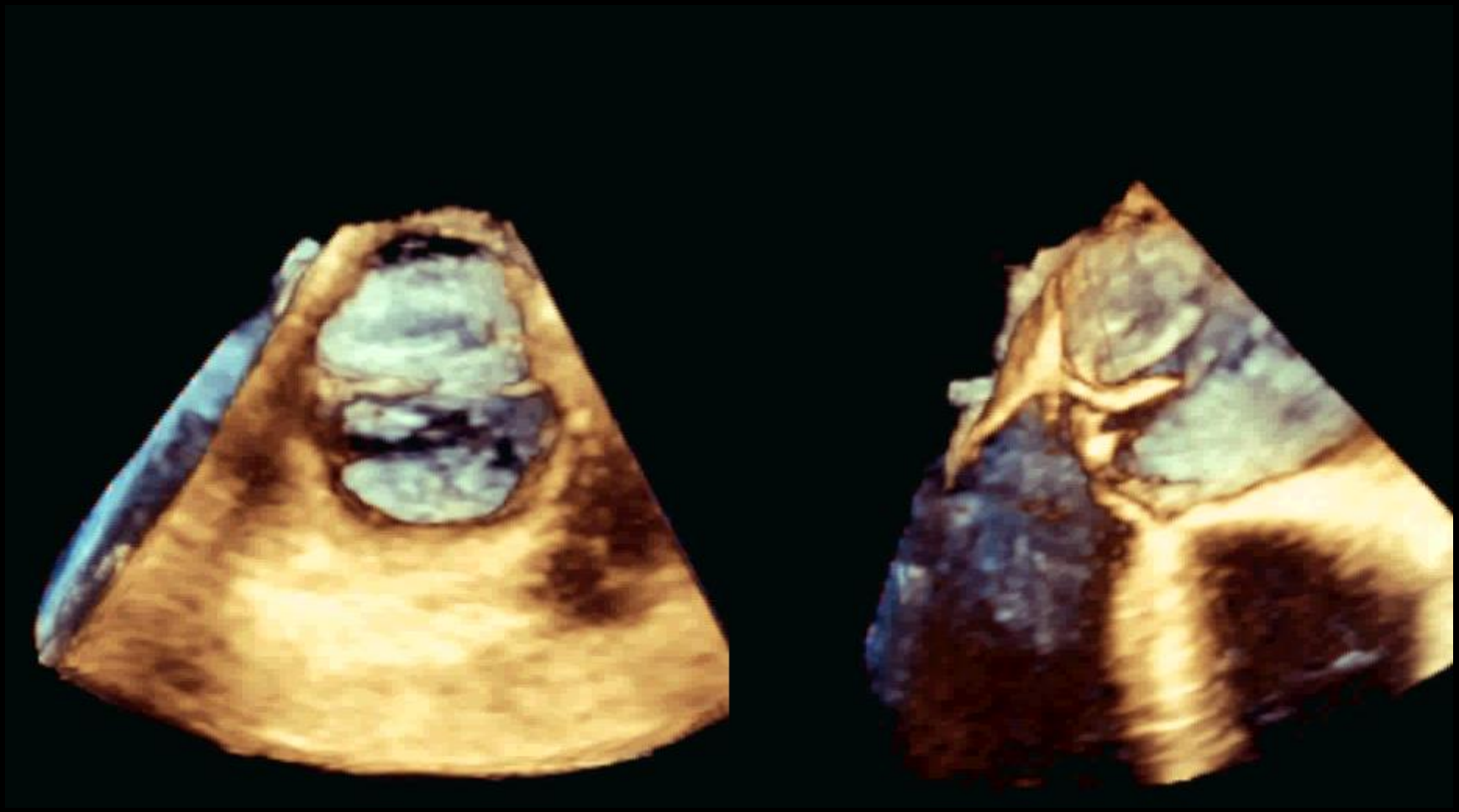

also an aortic root disease

AV abnormalities- bicuspid AV

- 15% of pts with biscuspid AV have additional coarctation
- Pts with coarctation have a bicuspid aortic valve in ~ 80%

AV abnormalities

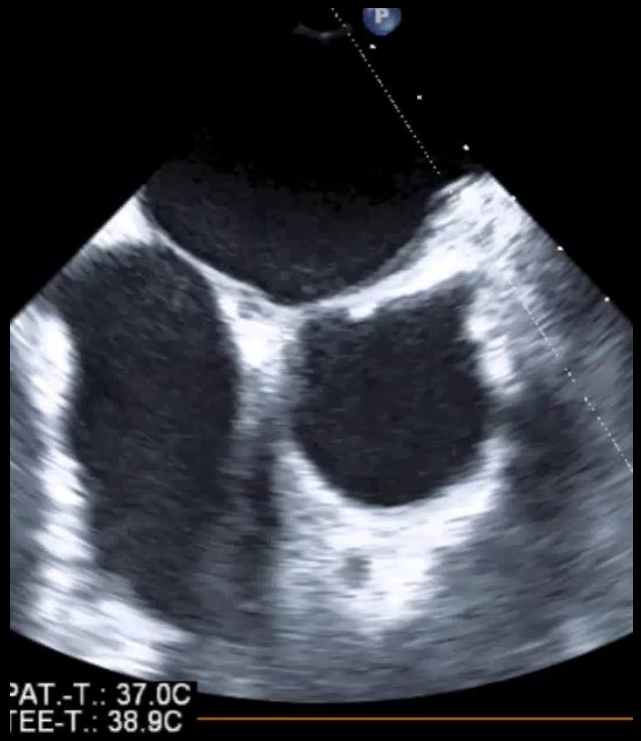

Uniscupid unicommissural AV

AV abnormalities

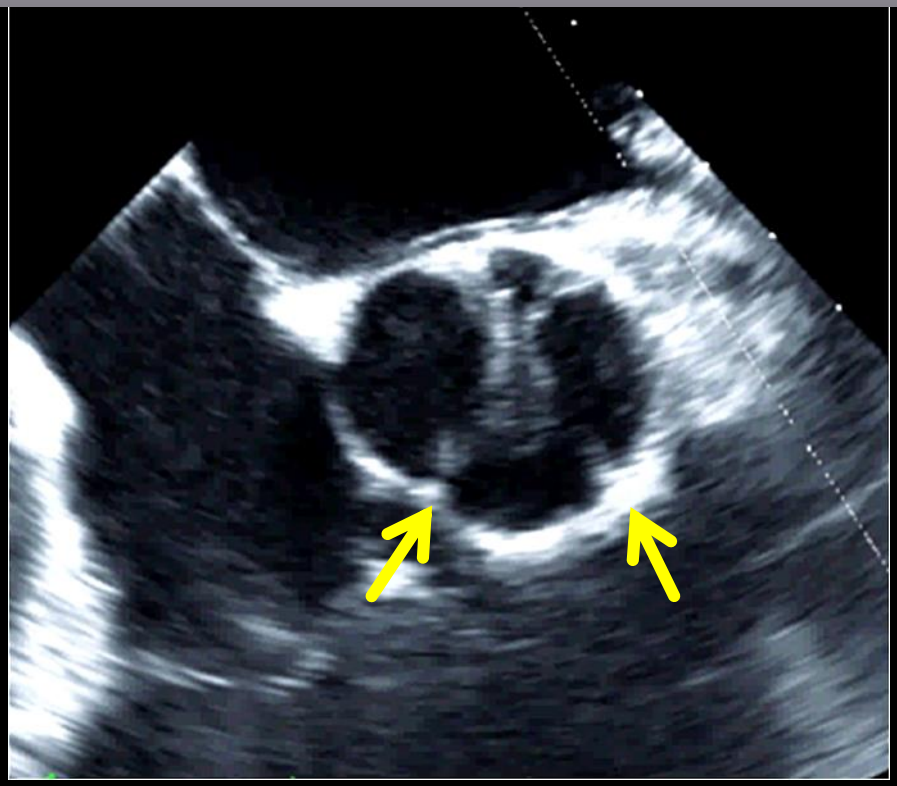

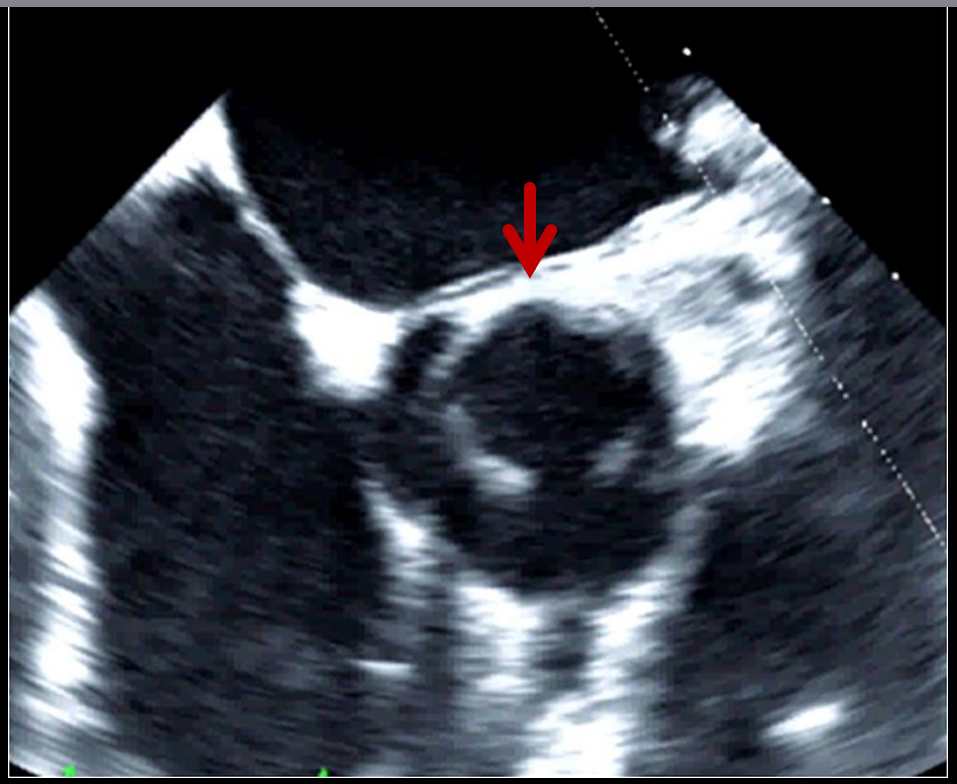

2D TEE : SAX view (60°) of the AV in diastole and systole

yellow arrows→ 2 raphes
red arrow→ 1 functional commissure
= unicommissural uniscupid AV

AV abnormalities

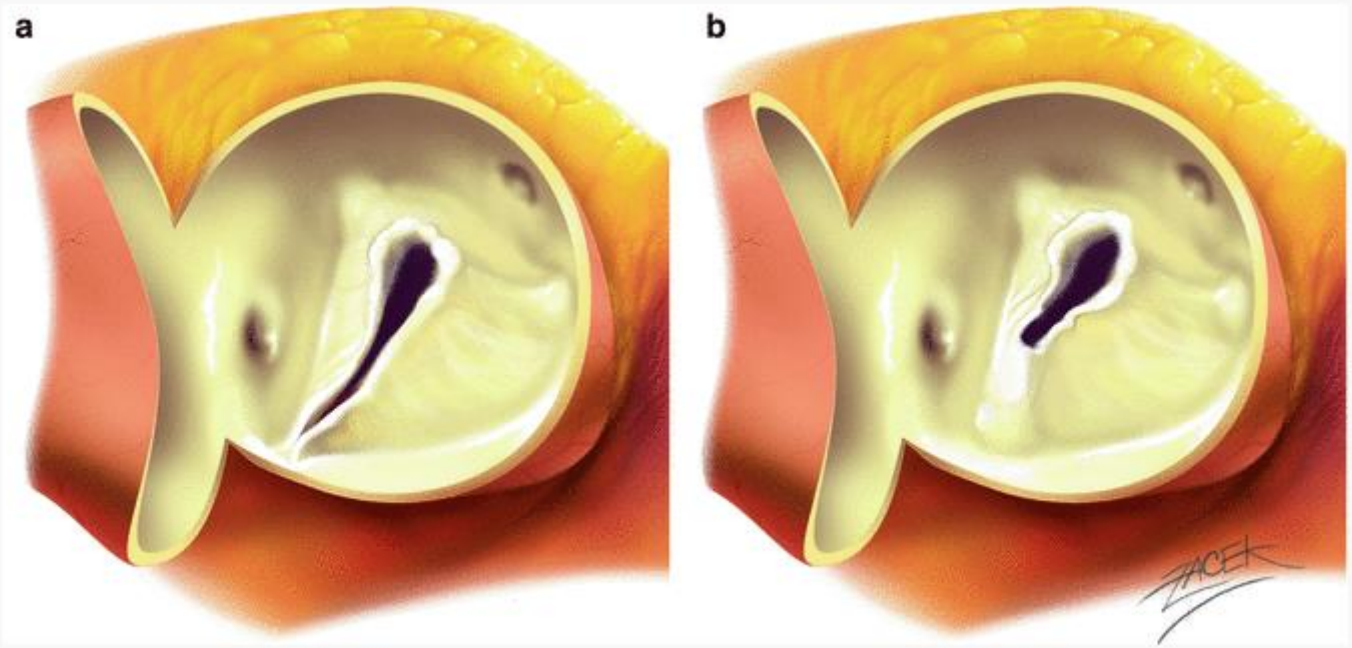

Fig. 6.15

Unicommissural Acommissural

Vojacek J., Zacek P., Dominik J., Holubec T. (2018) Congenital Anomalies of the Aortic Valve. In: Vojacek J., Zacek P., Dominik J. (eds) Aortic Regurgitation. Springer, Cham

AV abnormalities

Quadriscupid AV: rare→ usually associated with AR

Echo assessment of AR and its mechanisms

- Anatomy of the AV/Ao root complex
- AV abnormalities
- Echo evaluation of the AV/Ao root complex

Echo evaluation of the AV/aortic root complex *TTE / TEE*

- Advantages /limitations
- Evaluation of mechanisms
  - Root assessment
  - Valve and cusp assessment
- Grading of AR severity
- Evaluation of AV repairibility

Echo evaluation of the AV/aortic root complex
TTE / TEE

- Advantages /limitations
- Evaluation of mechanisms
  - Root assesment
  - Valve and cusp assessment
- Grading of AR severity
- Evaluation of AV repairibility

Echo evaluation of the AV/aortic root complex
TTE/ TEE→ Advantages /Limitations

Advantages:

- Real-time imaging in a blood-pressurized dynamic state (surgeon has to deal with a non-pressurized state)
- 3D: enface views from aortic and LV side
- 3D: adequate cutting planes can be defined by using MPR
- Wide spread availability

Limitations

- No pure morphological evaluation
- Underestiamtion of aortic root dimensions with 2D is unavoidable
- Insensitive in defining cusp prolapse in the presence of marked aortic dilation
- Distal part of ascending aorta before the arch usually not visible
- 3D has limited temporal/spatial resolution
- No gold standard for measurements!

Echo evaluation of the AV/aortic root complex

- Advantages /limitations
- Evaluation of mechanisms
  - Root assessment
  - Valve and cusp assessment
- Grading of AR severity
- Evaluation of AV repairibility

Echo evaluation of the AV/aortic root complex

Recommendations for measuring root dimensions- 2D

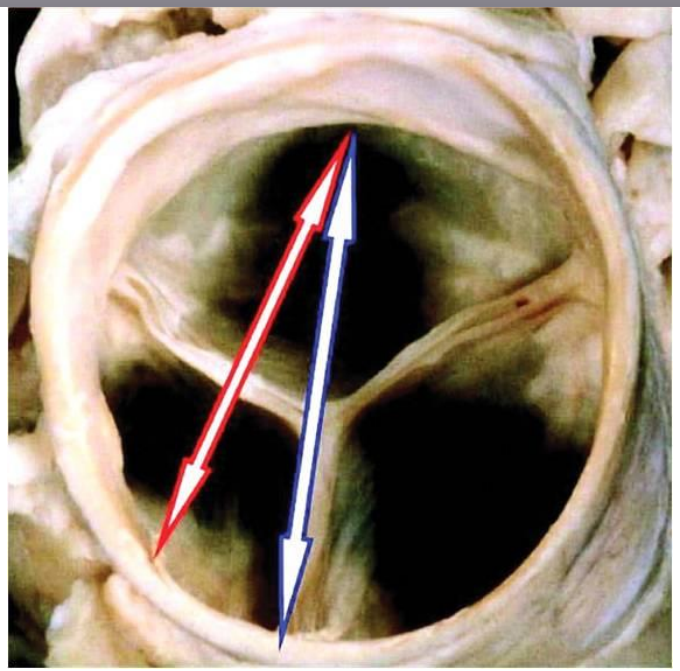

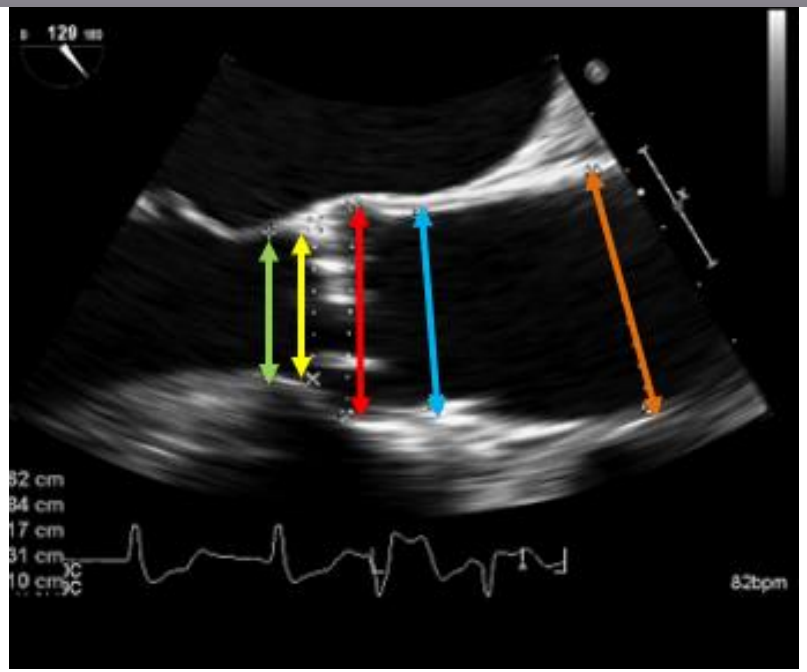

Zamorano JL

- Aortic annulus, at mid-systole from inner edge to inner edge
- L-

There is no gold standard yet!

- Root dimensions are usually largest in mid-systole
- inner-to-inner method seems more reproducible

Lang RM et al. EHJ- Cardiovascular Imaging (2015) 16, 233–271.

Echo evaluation of the AV/aortic root complex

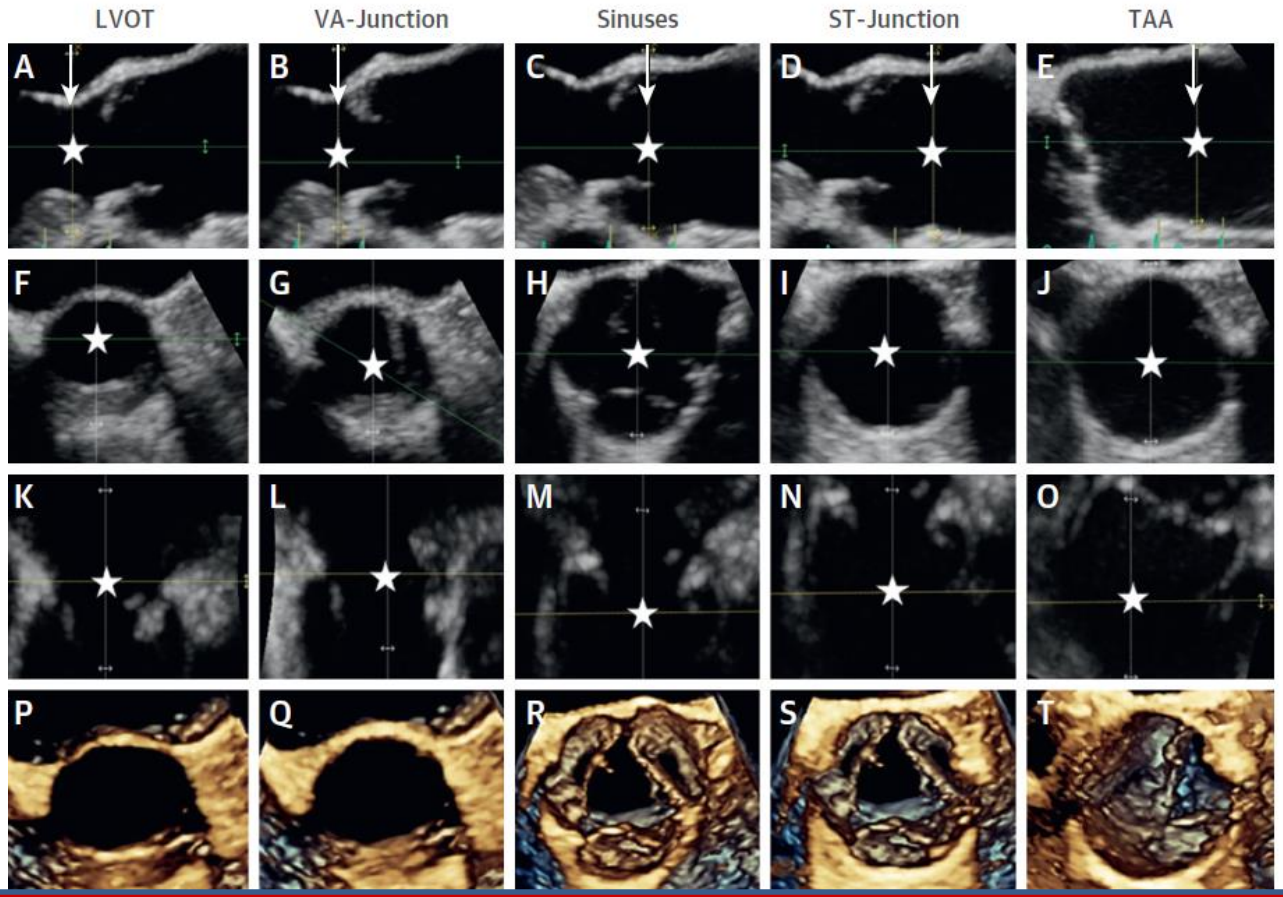

- Perpendicular sectional planes for measurement are only available with 3D echo
- 3D derived measurements correlate with CT derived
- Inner-to-inner edge method.: better reproducble

Echo evaluation of the AV/aortic root complex

Aortic root dimensions in normal adults

Aortic root	Absolute values (cm)		Indexed values (cm/m^2)	
	Men	Women	Men	Women
Annulus	2.6 ± 0.3	2.3 ± 0.2	1.3 ± 0.1	1.3 ± 0.1
Sinuses of Valsalva	3.4 ± 0.3	3.0 ± 0.3	1.7 ± 0.2	1.8 ± 0.2
Sinotubular junction	2.9 ± 0.3	2.6 ± 0.3	1.5 ± 0.2	1.5 ± 0.2
Proximal ascending aorta	3.0 ± 0.4	2.7 ± 0.4	1.5 ± 0.2	1.6 ± 0.3

- Nomograms for sinuses of Valsalva relating size to age & BSA

STJ dimensions are usually 15-20% larger than basal ring dimensions

Lang RM et al. EHJ-Cardiovascular Imaging (2015) 16, 233–271.

Echo evaluation of the AV/aortic root complex

When to intervene at the aortic root in the presence of relevant AR?

Echo measurements:

- Maximum sinus diameter > 42-45mm
- STJ diameter > 30-35mm
- Annular diamter > 25-28mm

Echo evaluation of the AV/aortic root complex

- Advantages /limitations
- Evaluation of mechanisms
  - Root assesment
  - Valve and cusp assessment
- Grading of AR severity
- Evaluation of AV repairibility

Echo Evaluation of cusp pathology

Causes of cusp pathology

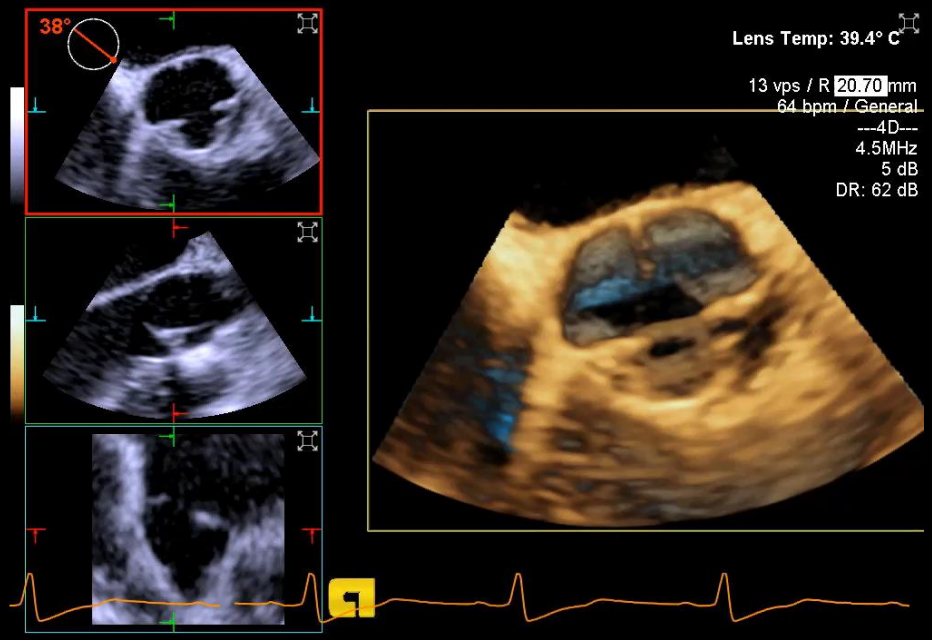

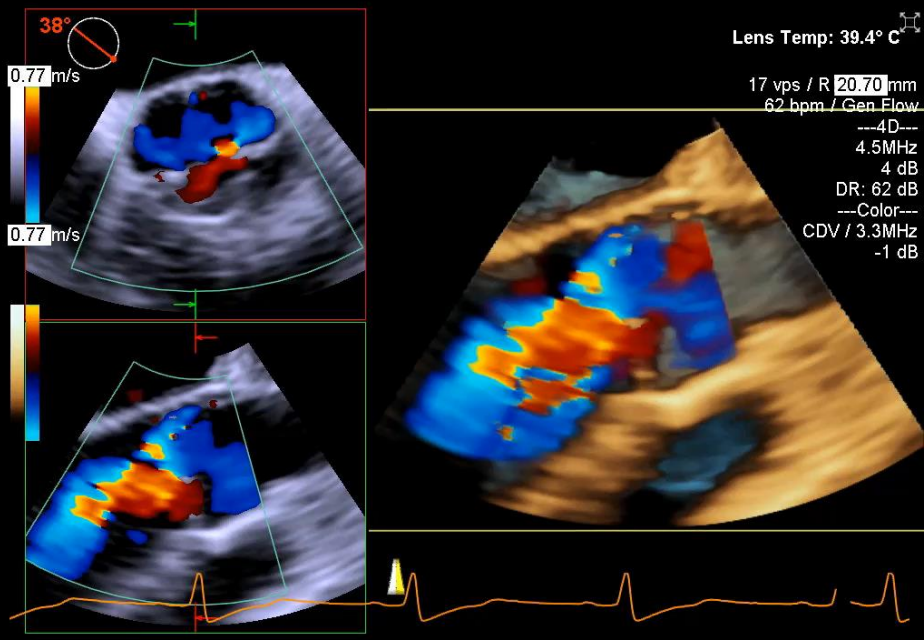

- AV morphology (bi-tricuspid)?
- Prolapse?
- Calcification?
- Perforations/ fenestrations?

Evaluation of cusp pathology
Causes of cusp pathology (n= 826)

- Prolapse n= 606 (73%)
  (right > non > left coronary cusp)
- Congenital malformation
  - bicuspid n= 276
  - uniscupid n= 50
  - quadriscupid n= 3
- Retraction/Calcium n=42

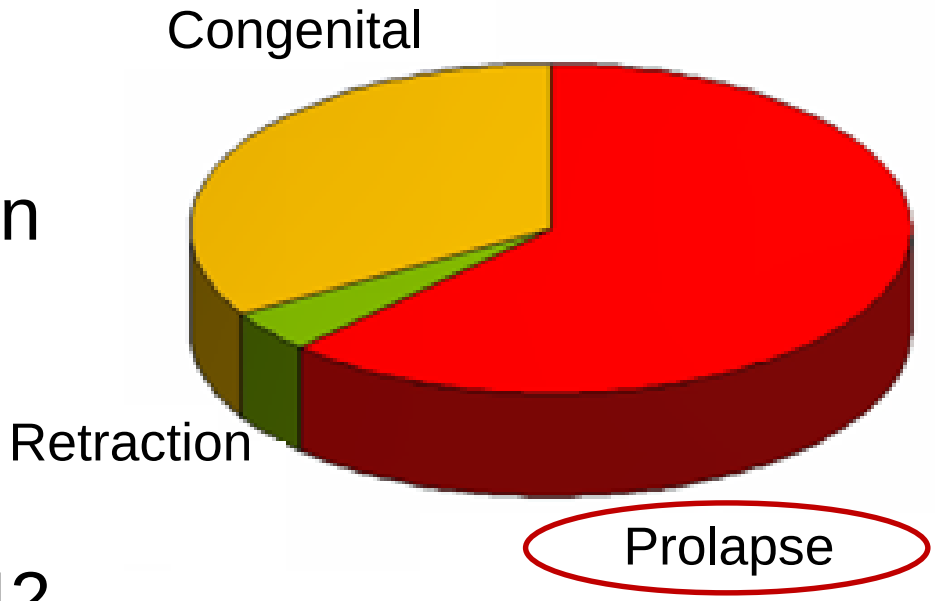

Courtesy of HJ Schäfers

Echo evaluatio of the AV/aortic root complex

What to measure?

Geometric determinants of AV form

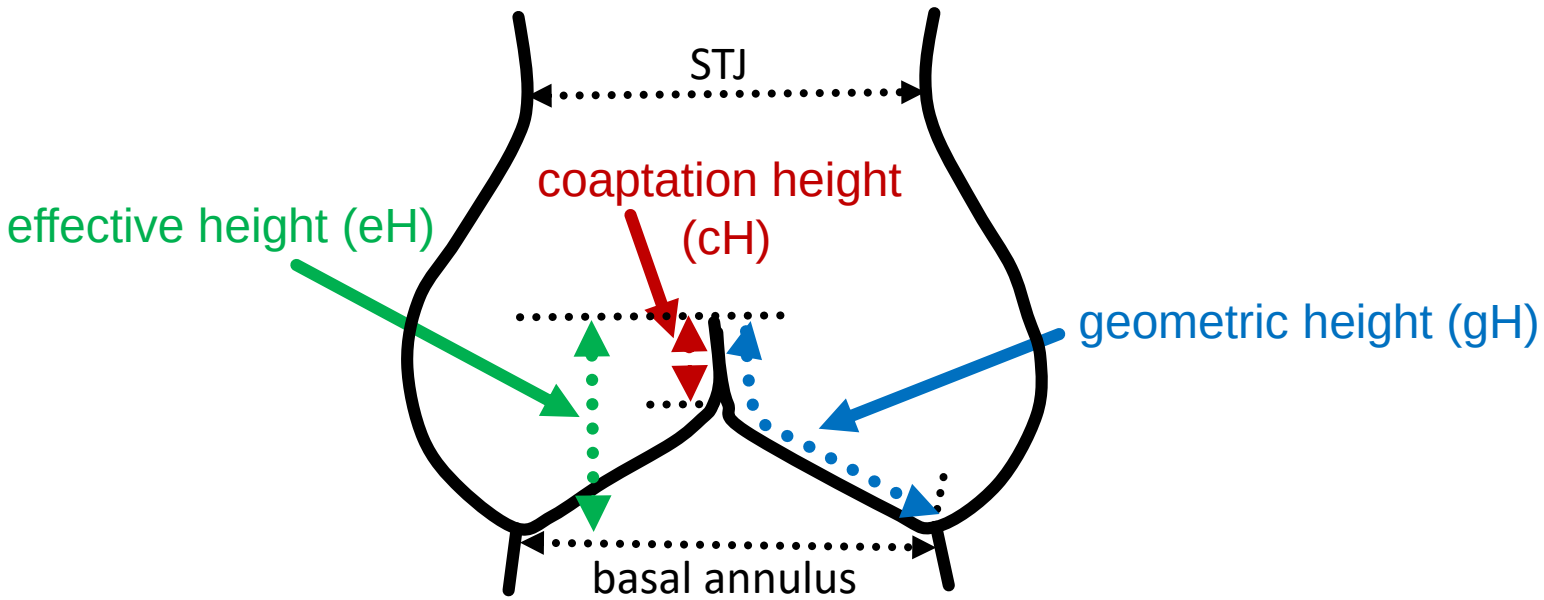

All cusp measurements are performed in diastole

Echo evaluatioin of the AV/aortic root complex

Effective height & coaptation length

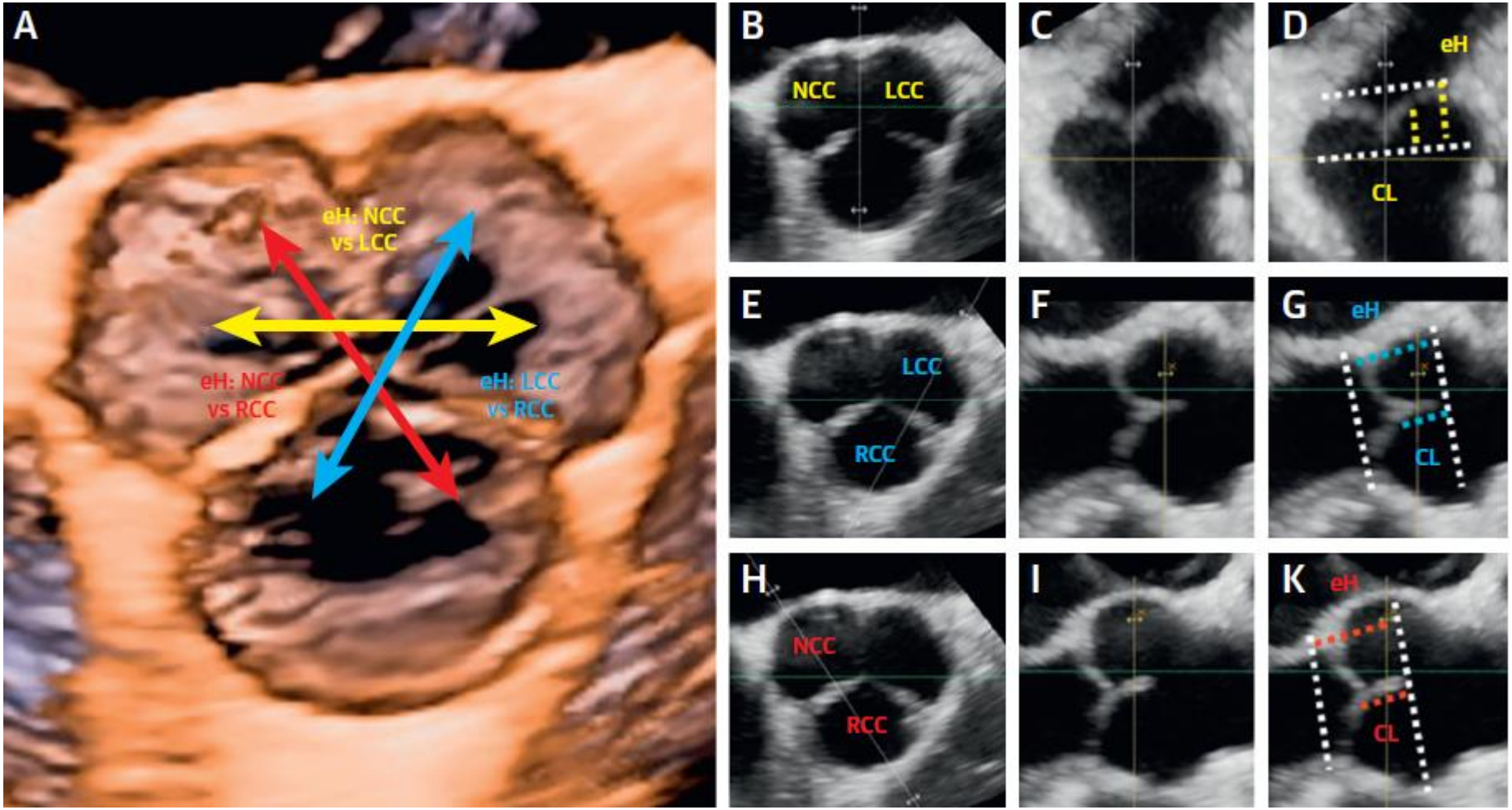

Hagendorff A, ….Schäfers HJ. J. Am Coll Cardiol Img 2019; in press

Echo evaluatioin of the AV/aortic root complex

Geometric height

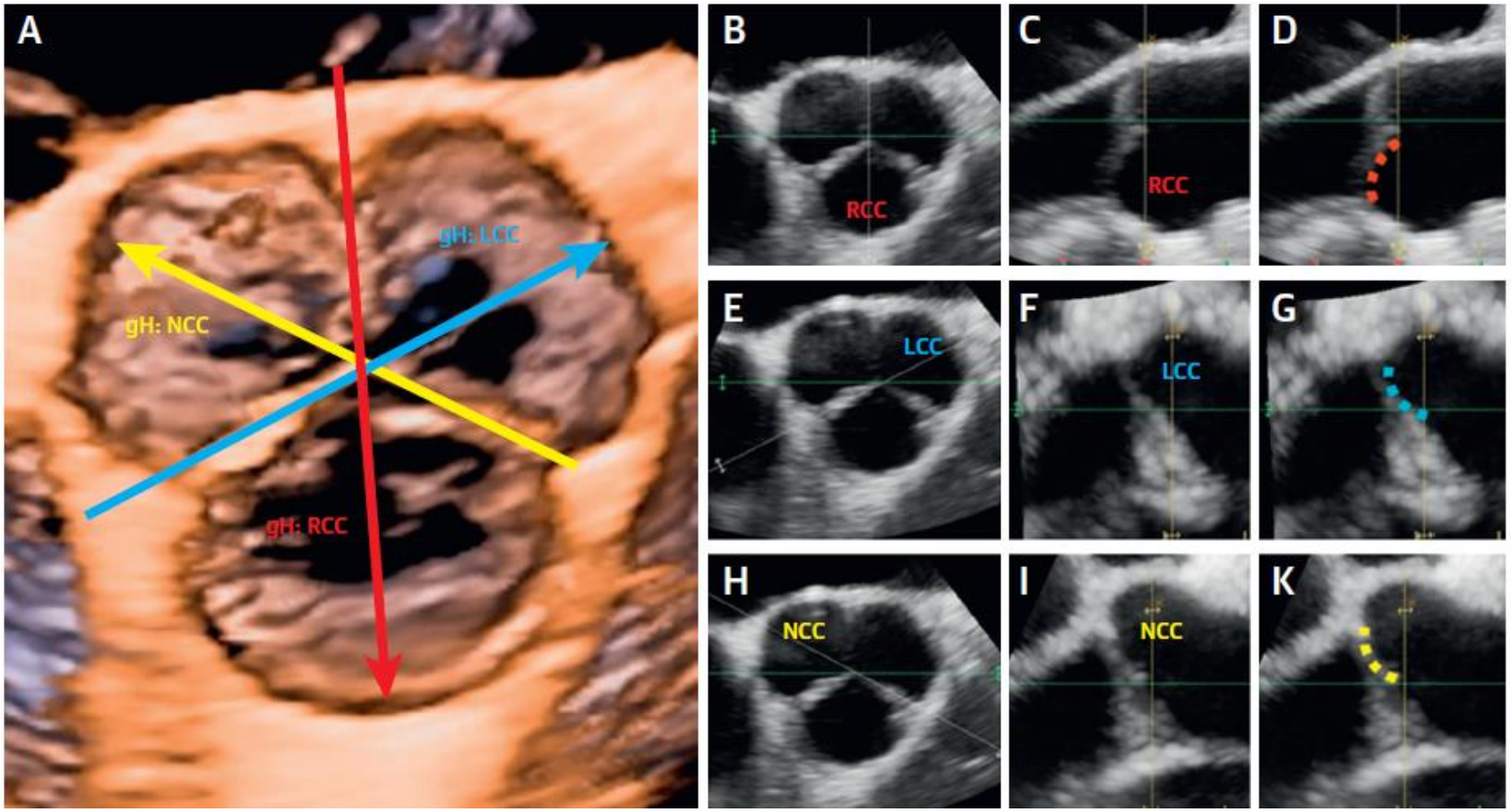

Hagendorff A, ….Schäfers HJ. J. Am Coll Cardiol Img 2019; in press

Echo evaluatioin of the AV/aortic root complex
Rientation of the commissure in bicupid AV

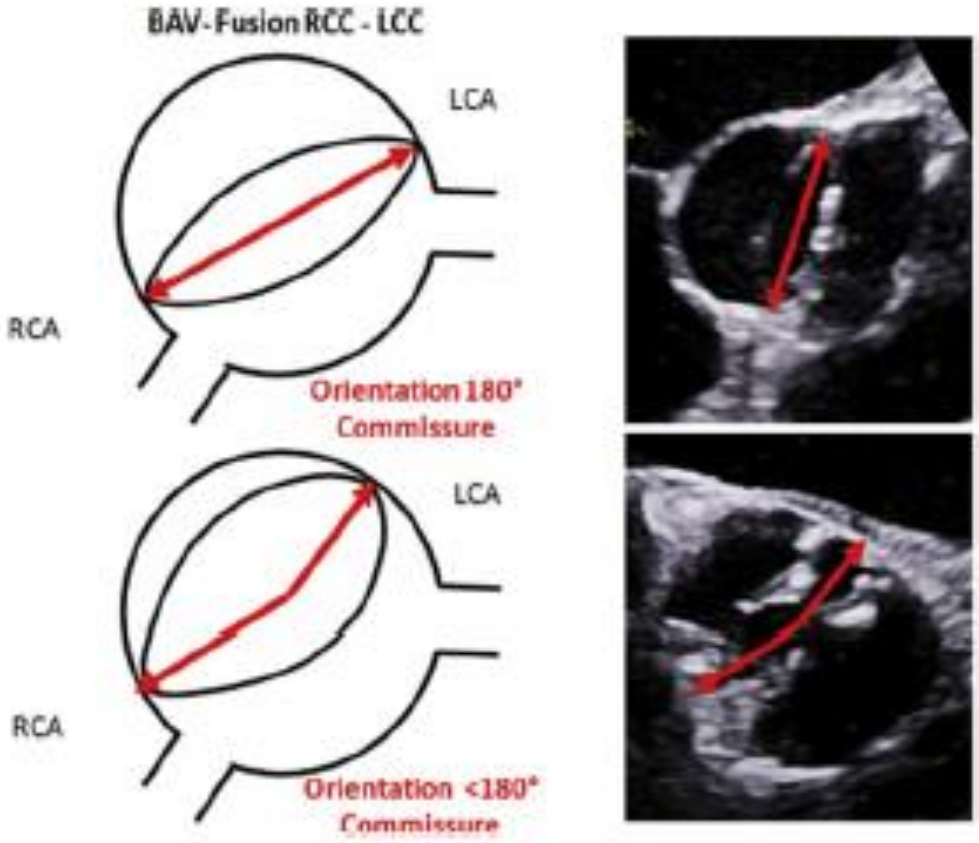

Orientation < 160 degree → asymmetric→ needs symmetrization of functional commissures

Hagendorff A, ….Schäfers HJ. J. Am Coll Cardiol Img 2019; in press

Echo evaluation of the AV/aortic root complex

Functional assessment

Mechanisms of AI Classification

Type I
Normal cusp movements
related to aortic root
or ascending aorta dilation
with central jet

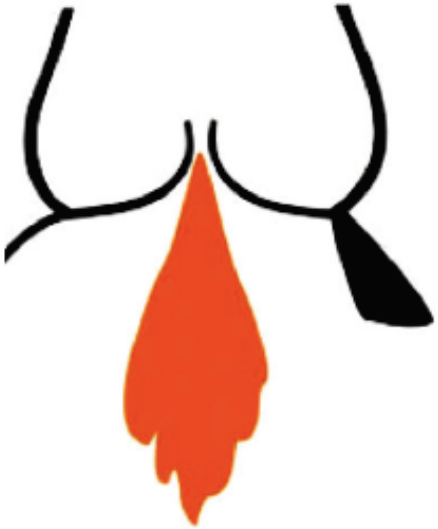

Type II
Cusp prolapse
with eccentric jet

Type III
Cusp retraction
with poor tissue quality or quantity
with large central
and/or eccentric jet

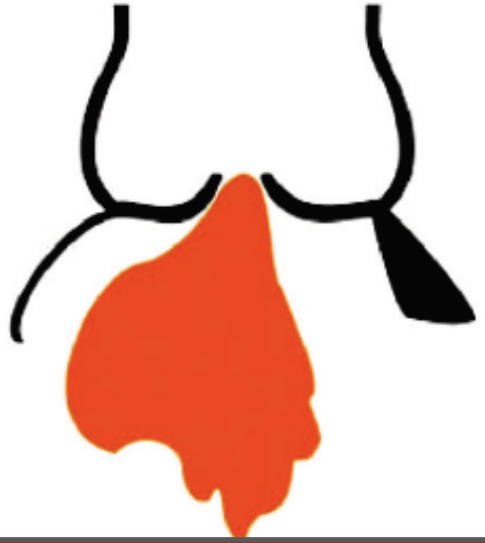

Descibed with eH:

- eH < 0 = complete
- 0 > eH < 9mm = incomplete

Doesn`t differentiate between restriction due to annular dialtion or cusp degeneration/restrcition

Berrebi A et al. Annals of cardiothorac

Echo evaluation of the AV/aortic root complex

- Advantages /limitations
- Evaluation of mechanisms
  - Root assesment
  - Valve and cusp assessment
- Grading of AR severity
- Evaluation of AV repairibility

ESC guidelines- AR grading

Table 4 **Grading the severity of AR**

Parameters	Mild	Moderate	Severe
Qualitative			
Aortic valve morphology	Normal/abnormal	Normal/abnormal	Abnormal/flail/large coaptation defect
Colour flow AR jet width[a]	Small in central jets	Intermediate	Large in central jet, variable in eccentric jets
CW signal of AR jet	Incomplete/faint	Dense	Dense
Diastolic flow reversal in the descending aorta	Brief, protodiastolic flow reversal	Intermediate	Holodiastolic flow reversal (end-diastolic velocity >20 cm/s)
Diastolic flow reversal in the abdominal aorta	Absent	Absent	Present
Semi-quantitative			
VC width (mm)	<3	Intermediate	≥6
Pressure half-time (ms)[b]	>500	Intermediate	<200
Quantitative			
EROA (mm^2)	<10	10–19; 20–29[d]	≥30
R Vol (mL)	<30	30–44; 45–59[d]	≥60
+ LV size[c]			

A multi-modal approach!

Baumgartner et al. , ESC guidelines 2017

Case example - summary of most important findings

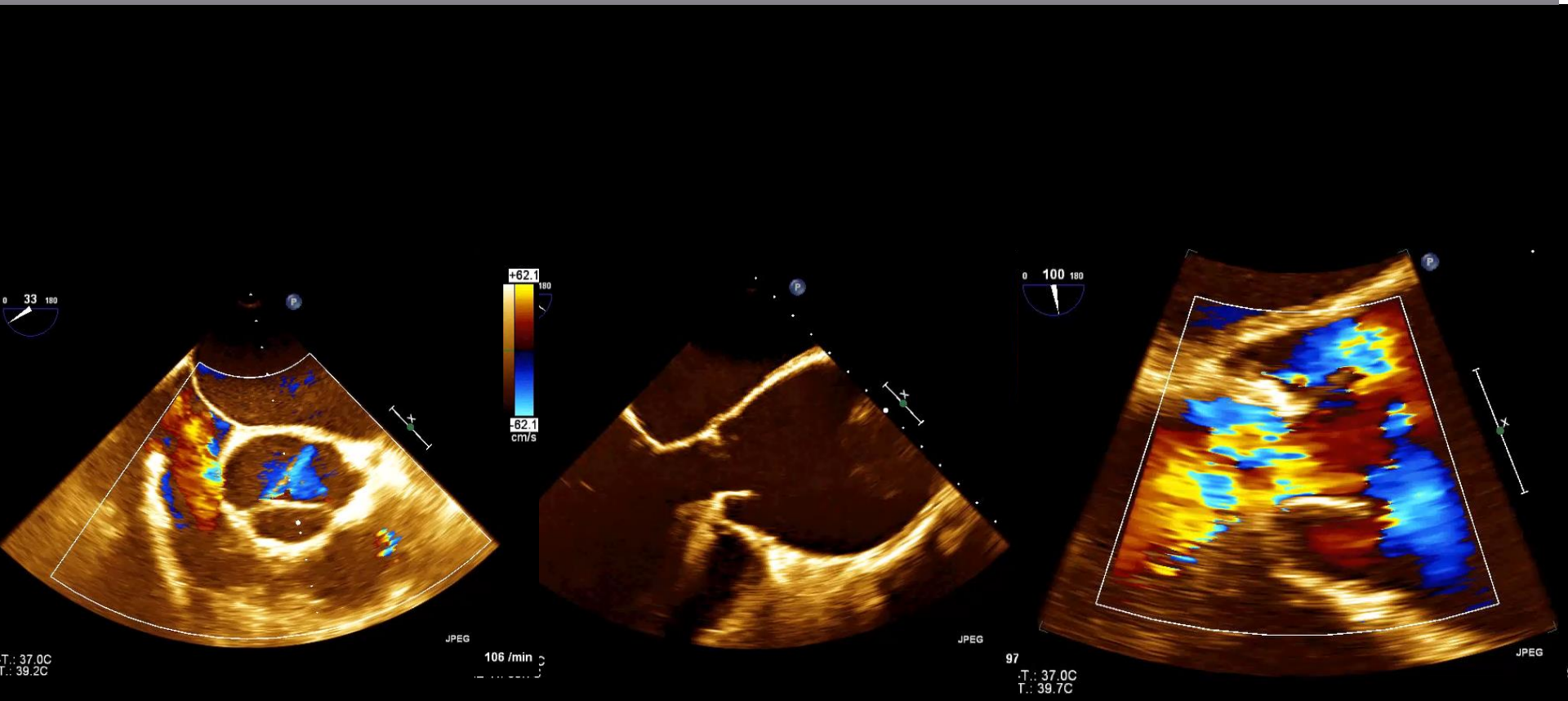

Case example - summary of most important findings

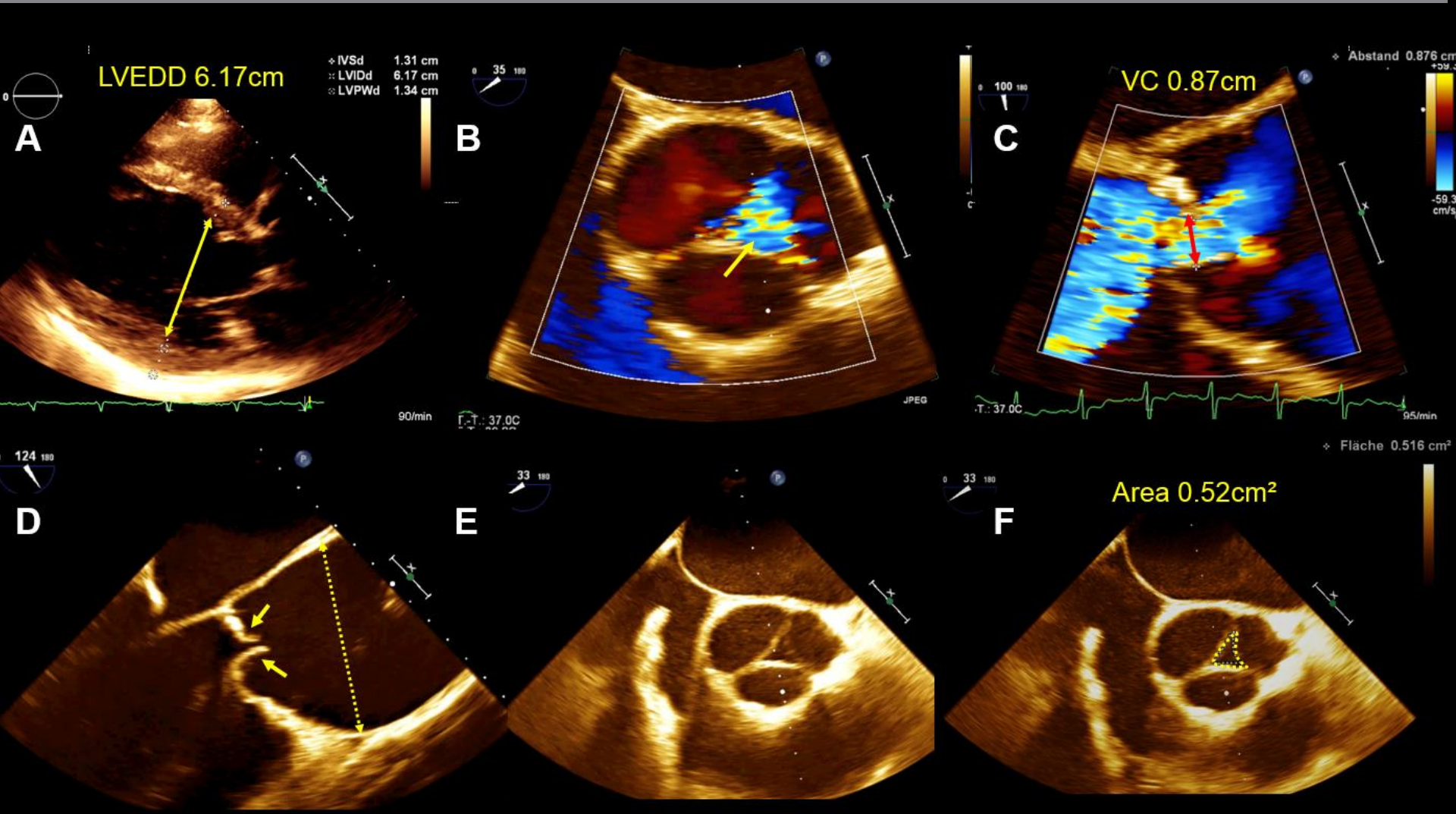

Flint N, Wunderlich N et al. Curr Cardiol Rep. 2019 Jun 3;21(7):65.

Case example - summary of most important findings

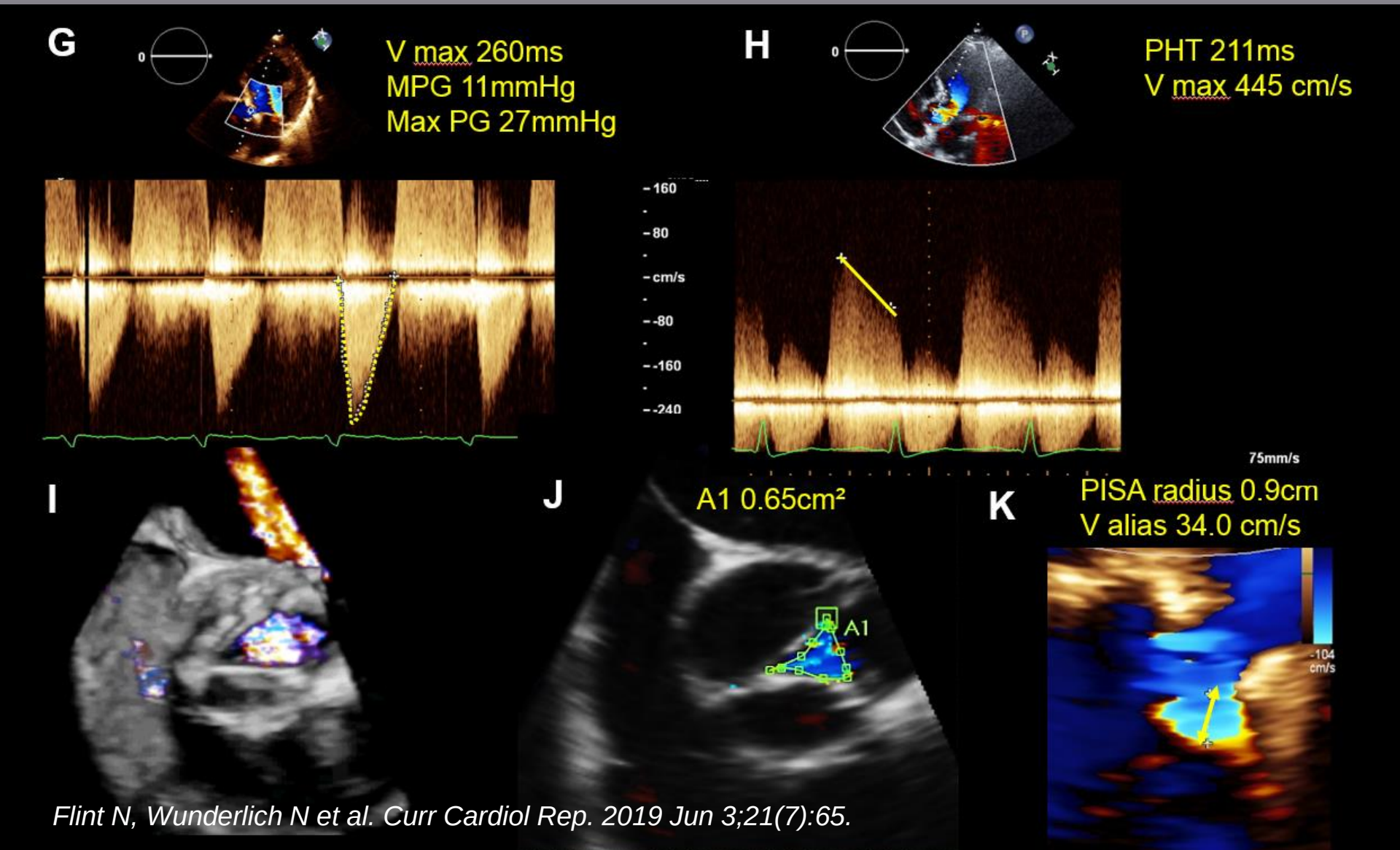

Flint N, Wunderlich N et al. Curr Cardiol Rep. 2019 Jun 3;21(7):65.

Case example- summary of most important findings

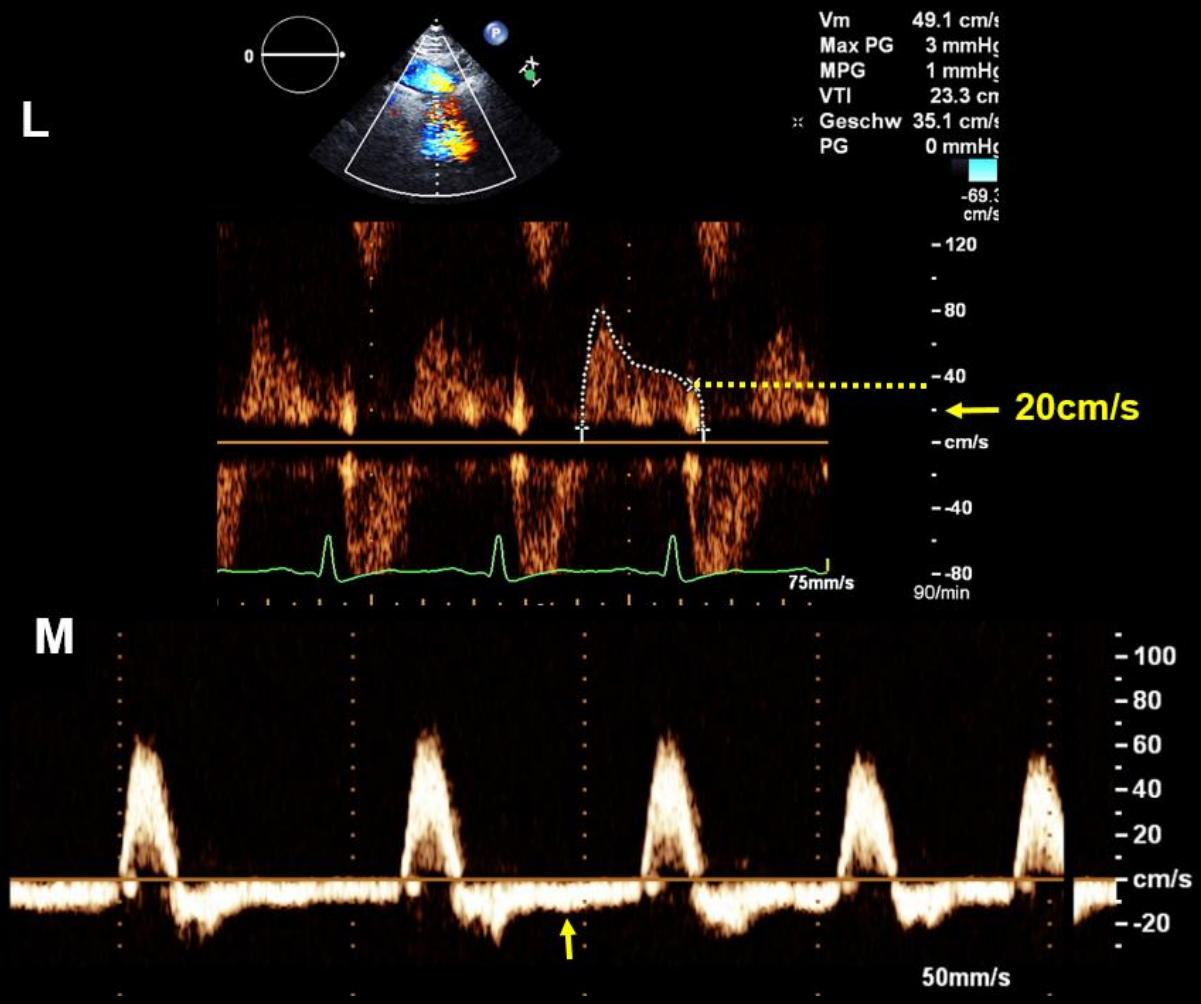

Echo evaluation of the AV/aortic root complex

- Advantages /limitations
- Evaluation of mechanisms
  - Root assesment
  - Valve and cusp assessment
- Grading of AR severity
- Evaluation of AV repairibility

Echo evaluation of AV repairibility

Normalization of aortic root dimensions and restoration of cusp configuration leads to successful AV repair.

- Function follows morphology!

Echo evaluation of the AV/Ao root complex

Echo parameters and surgical impliactions

Measurement	Echo definition	Echo views & modalities	Cut-off value	Echo significance	Surgical implications
Aortic annulus	Distance between hinge of right cusp and commissure L/N (end-systole)	Long axis view	25 mm	If ≥25 mm; dilated annulus	Need for aortic annuloplasty techniques (ring)
Effective height (eH)	Distance between free edge of individual cusp and plane of the annulus (end-diastole)	Long axis or deep transgastric view. X Plane for RCC; Live MPR Multiview or Q Lab post-processing	9 mm	Prolapse definition: eH <0 complete; 0< eH <9 mm incomplete	Pre-op: need for resuspension; post-pump: criteria of effective and durable repair
Geometric height (gH)	Length of individual cusp (origin insertion hinge to free edge, in end-diastole)	Long axis or deep transgastric view. X Plane for RCC; Live MPR Multiview or Q Lab post-processing	16 mm in tricuspid; 19 mm in bicuspid	Cusp retraction if: <16 mm (tricuspid); <19 mm (bicuspid) "surgical cut-off"	Unfavorable lesions for aortic valve repair
Coaptation height (cH)	Distance of coaptation between two cusps (end-diastole)	Long axis or deep transgastric view	5 mm	Good coaptation if >5 mm	Post-pump: criteria of effective and durable repair
Commissural orientation	Angle between two functional commissures in type I bicuspid valve (end-diastole)	Short axis view; alternative: CT	160°	If <160° asymmetric configuration of bicuspid type I	Need for symmetrization of functional commissures

L/N, left/non; RCC, right coronary cusp.

Berrebi A et al. Ann Cardiothorac Surg 2019;8(3):331-341

Conclusions

- The decision making process in the presence of relevant AR relies on an accurate evaluation of AR mechanisms and a precise description of the root/cusp complex
- A standardized echo protocol of root/cusp assessment including 3D imaging is needed in order to obtain reproducible results
- For characterization of AR severity a multimodal approach is essential

Thank you!

Colour Doppler Jet

- Weak correlation with the degree of AR
- Affected by LV diastolic pressure and LV compliance
- Relies on technical factors (PRF, direction of jet; initial visual assessment screening tool)
- Jet width > 65% in the LVOT = severe AR)

Not valid for qunatitative assessment!

Diastolic flow reversal in descending aorta
PW Doppler

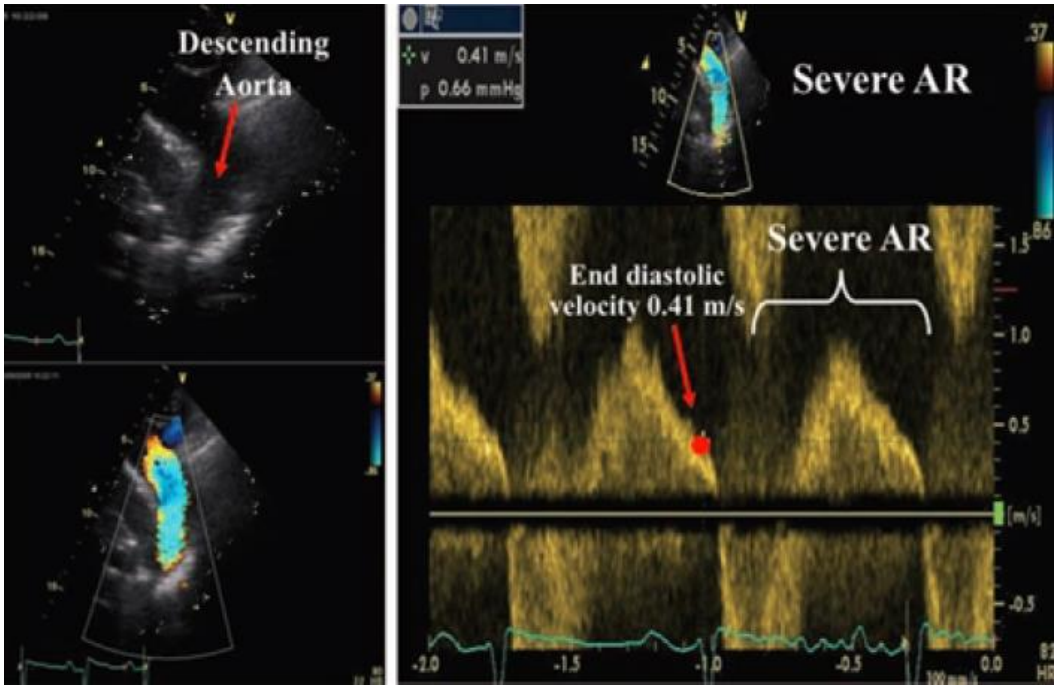

- Sample volume placed just distal to the left subclavian
- As much aligned as possible
- Lower Doppler filter (to detect low velocities)
- Cut-off 20 cm/s Strongest additional parameter!

Vena contracta width

The narrowest portion of the AR jet downstream from the orifice

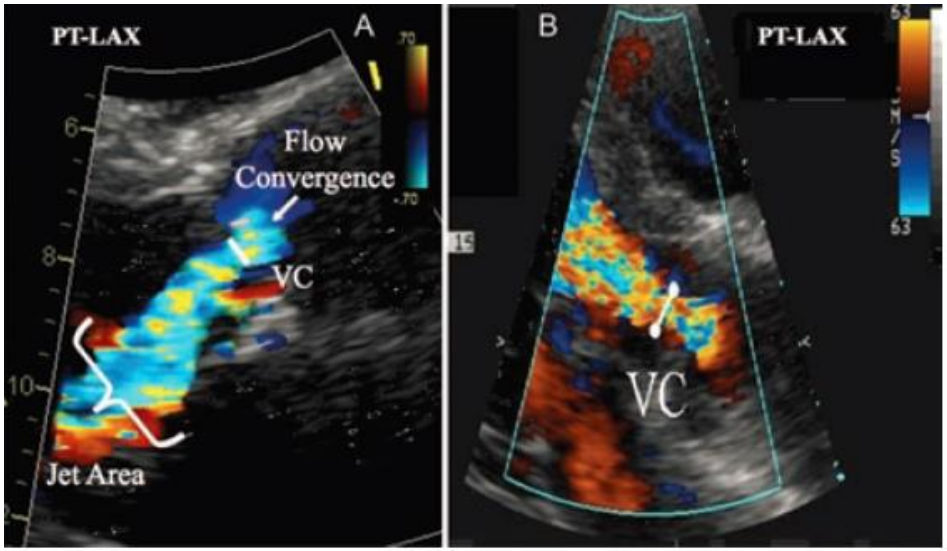

Strengths:
- **Reliable for central & eccentric jets**
- **Independent of flow rate**

Limitatons:
- **Multiple jets**
- **Non- circular orifice**

- 2 orthogonal planes, Color sector as narrow as possible
- Zoom to optimize visualization / Nyquist limit to 50-60cm/s
- Maximal lateral and temporal resolution
  - Mild AR < 3 mm,
  - Severe AR ≥ 6 mm

PISA (proximal isovelocity surface area)

Conservation of mass:
Q1 =Q2

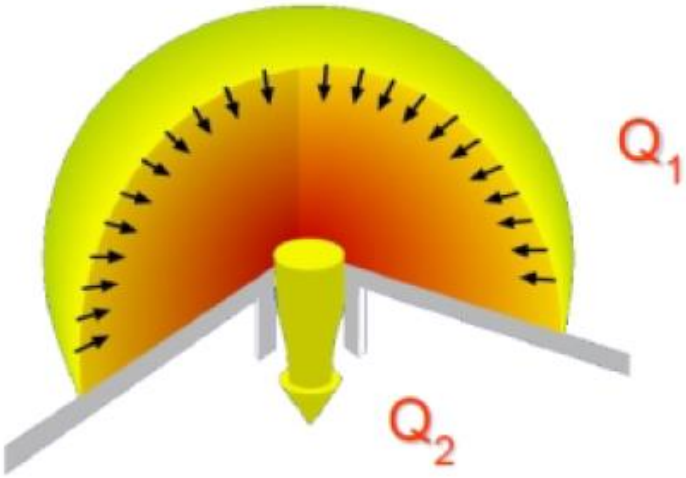

- Assumption: Single orifice surrounded by planar surface
- ERO supposed to be constant
- Instantaneous measurement of ERO (may vary during the cardiac cycle)

PISA (proximal isovelocity surface area)

Tipps for calculation

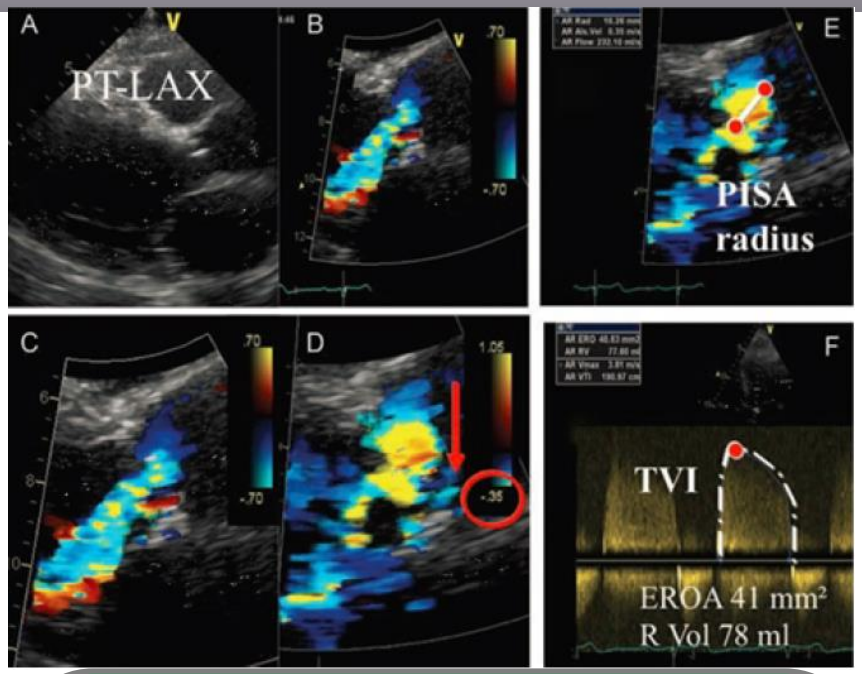

Strengths

1. Less affected by hemodynamic factors

2. Etiology of AR or other valve disease do not affect ERO calculation

3. Can be used with eccentric jets:

- **Zoom** on the AV from an PLAx or apical view.
- **Shift the color baseline** down (in the direction of the regurgitant jet) to increase the PISA hemisphere, facilitating measurement of its radius.
- Obtain multiple beats-per-clip and **choose only a hemispheric PISA "mushroom"** (dome).
- Measure the radius from the valve tips to the first aliased velocity at the red (usually yellow)-blue interface. This occurs in **mid- to late diastole.**
- The Doppler beam should be parallel to AR jet to accurately
- Measure the peak AR velocity.

PISA (proximal isovelocity surface area)

Tipps for calculation

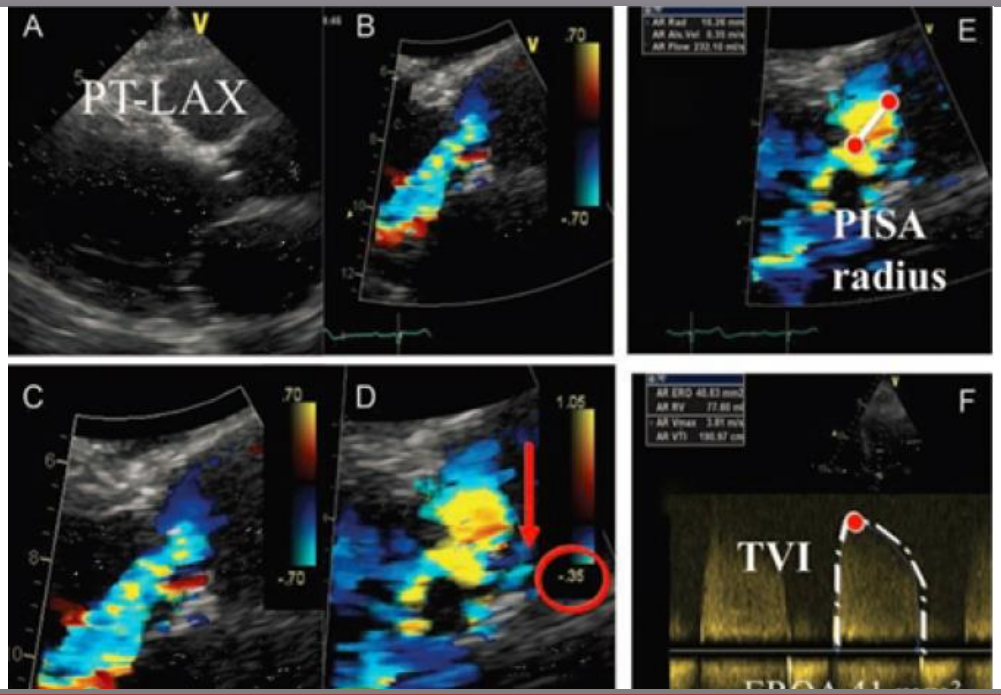

Limitations:

1. Interposition of valve tissue / difficulty in determining flow convergence zone
2. Non-circular orifice
3. Obtuse flow convergence angles

Evaluation of AV repairability

Higher effective height leads to improved coaptation height

Aortic root numeric model: Correlation between intraoperative effective height and diastolic coaptation

Gil Marom, MSc,[a] Rami Haj-Ali, PhD,[a] Moshe Rosenfeld, DSc,[a] Hans Joachim Schäfers, MD,[b] and Ehud Raanani, MD,[c] Tel Aviv and Tel Hashomer, Israel; and Homburg, Germany

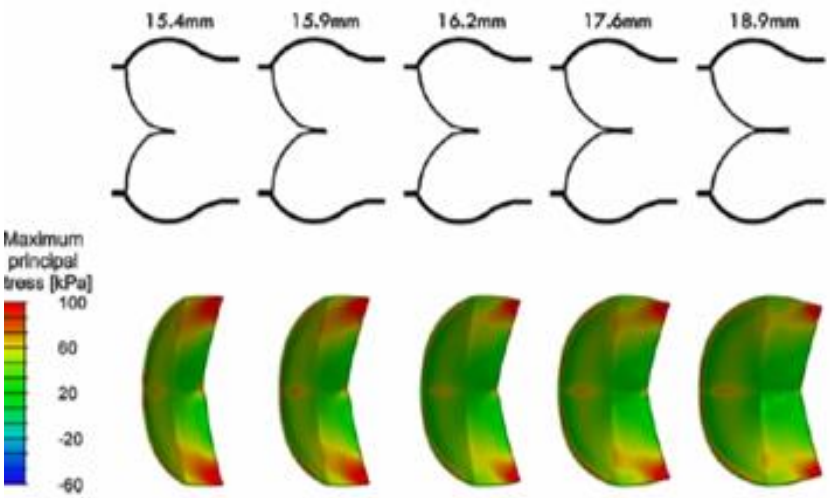

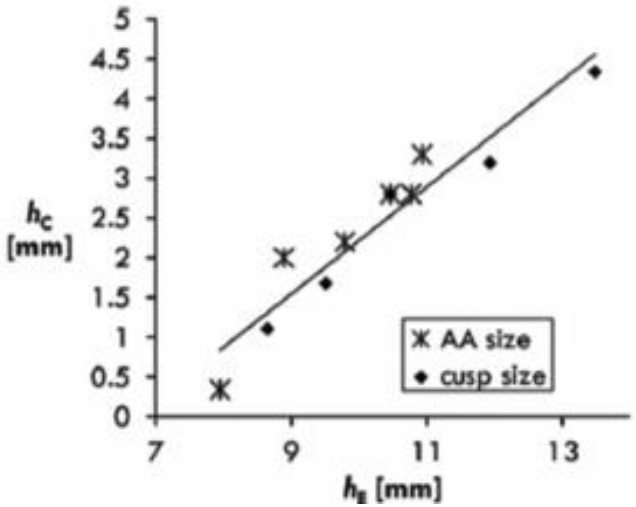

eH > 8mm after surgical repair = higher probability of good AV function

J Thorac Cardiovacs Surg 2013; 145: 303-4

Degenerative AV stenosis

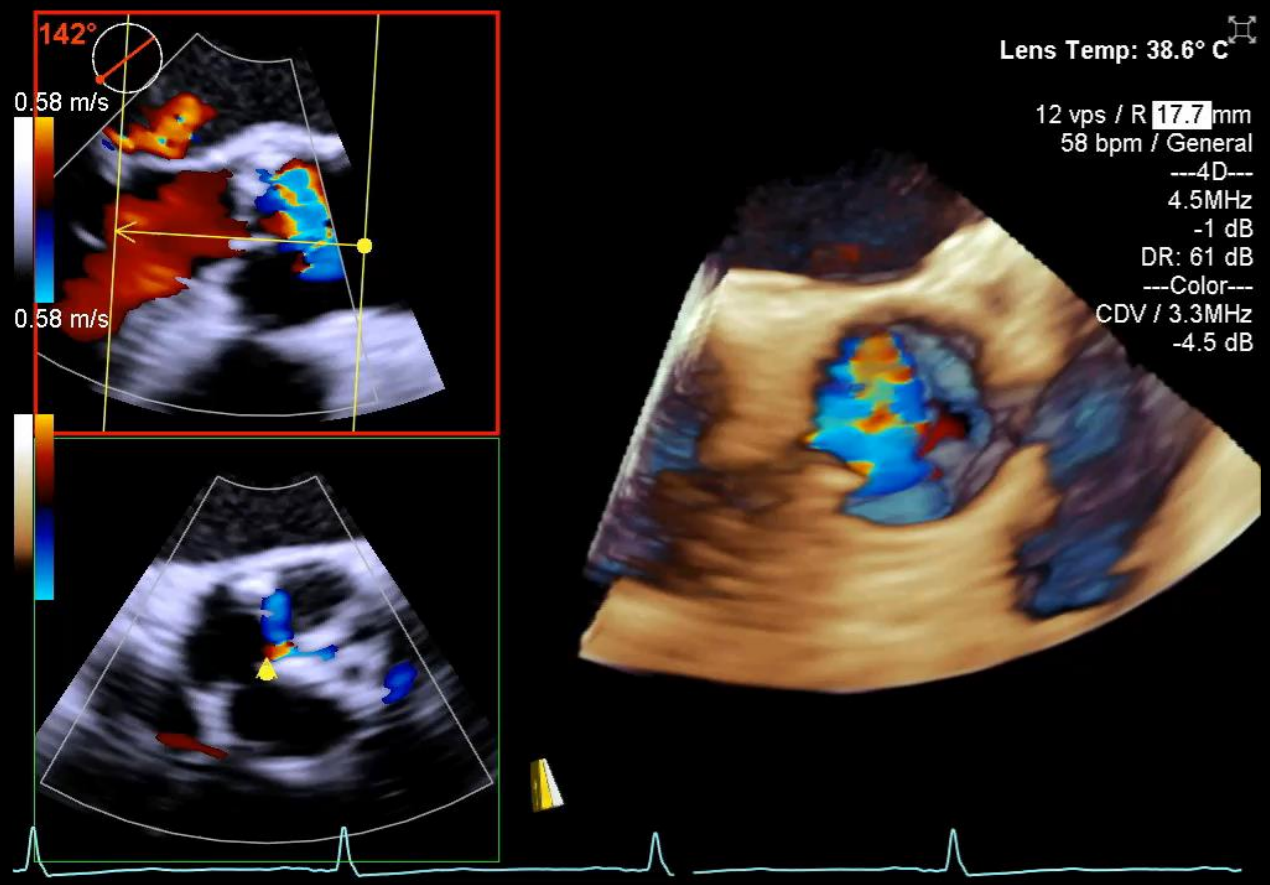

Echo evaluatioin of the AV/aortic root complex

What to measure?

Definition of measurements