UKS
Universitätsklinikum
des Saarlandes

20.09.2019

How to Start Aortic Cusp Repair

H.-J. Schäfers
Dept. of Thoracic and Cardiovascular Surgery
Saarland University Medical Center

When to repair

reasonable

tricuspid/bicuspid valve, prolapse of 1 or 2 cusps

prolapse of 3 cusps, fenestrations, unicuspid av, retraction, active endocarditis

?

relevant retraction/calcium

!

uncertain

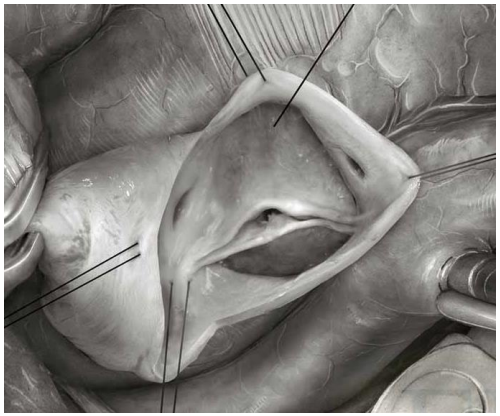

Operative Steps:

1. Patient Selection:

Bicuspid aortic valve
Normal root size
Orientation of commissures > 150°
Minimal or absent calcification
Complete fusion

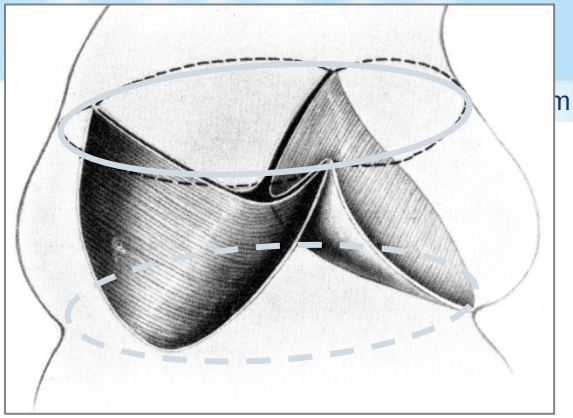

m Folienmaster anpassen)

Operative Steps:

Assessment:

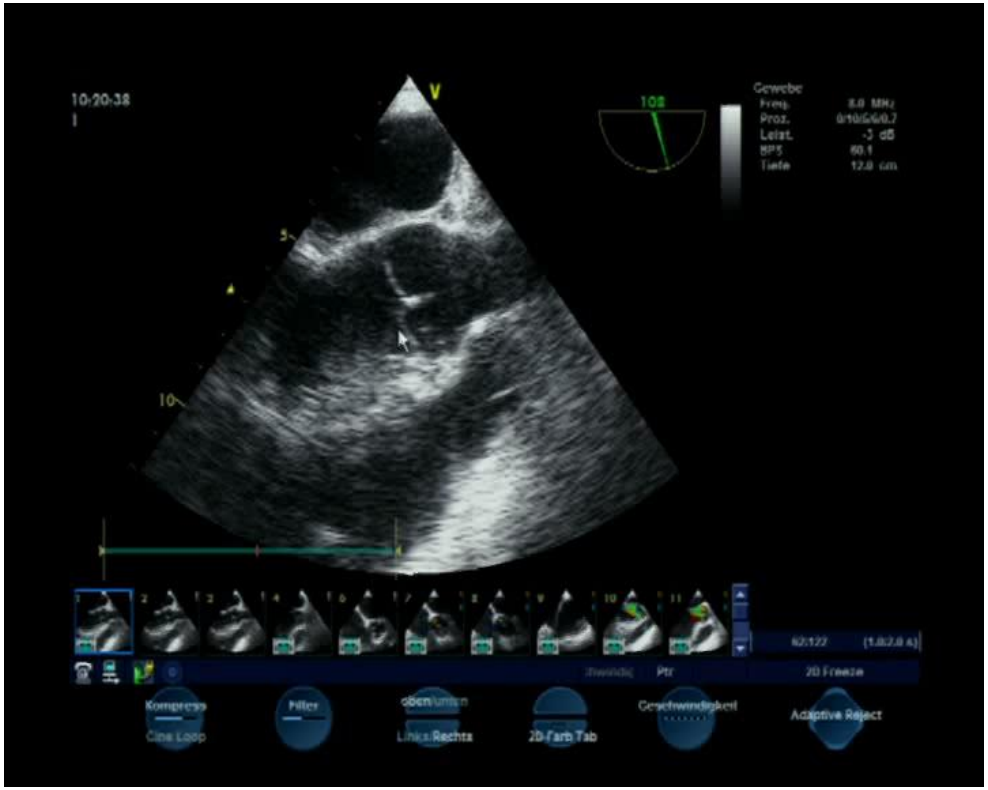

Operative Steps:

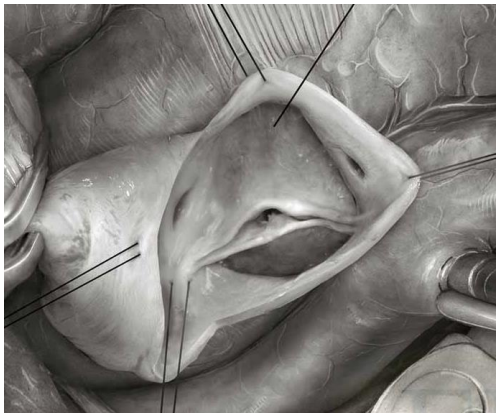

2. Exposure:

Standard cannulation

Transverse aortotomy (10 mm above ST junction

Traction sutures on commissures in direction of commissures & under tension

Operative Steps:

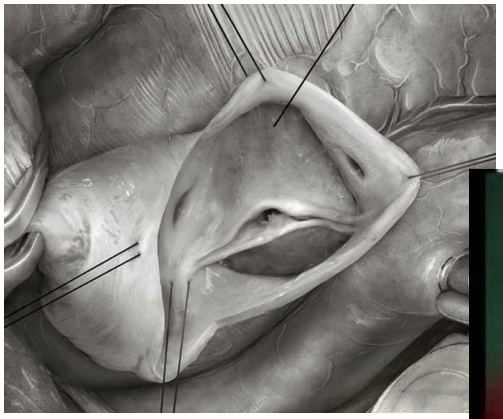

Exposure:

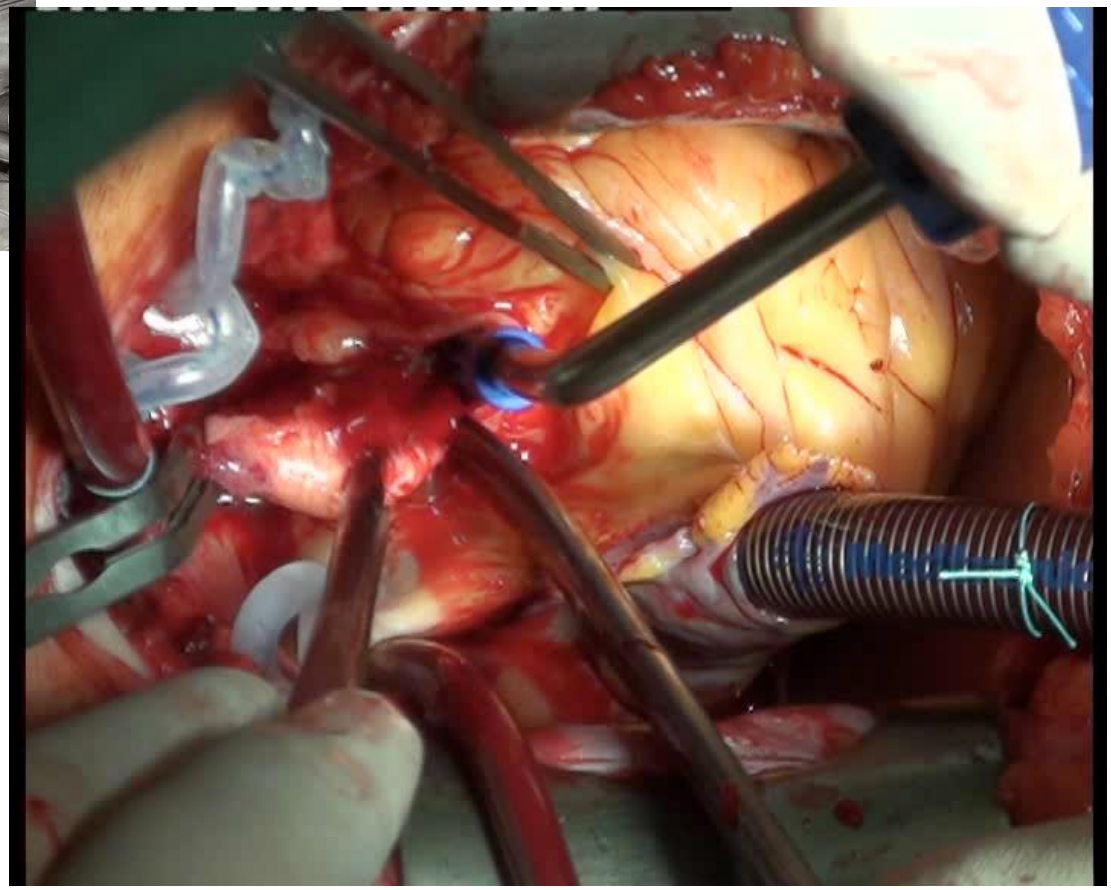

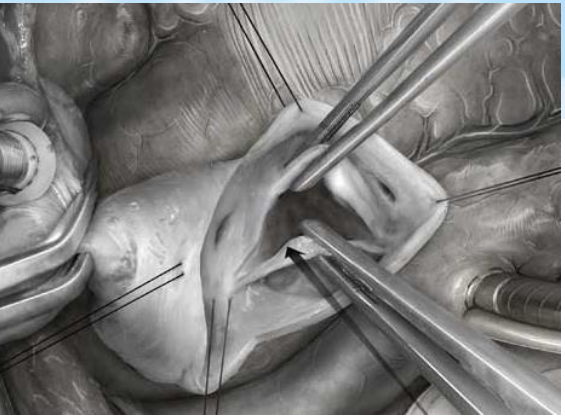

Operative Steps:

4. Assessment of large (NC) cusp:

Geometric height (how much tissue?)

Effective height (cusp configuration)

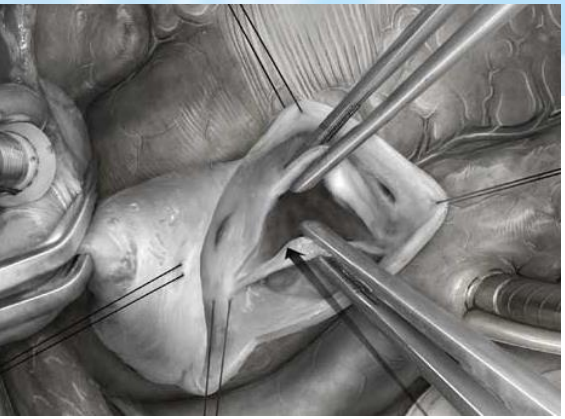

Operative Steps:

Assessment of large (NC) cusp:

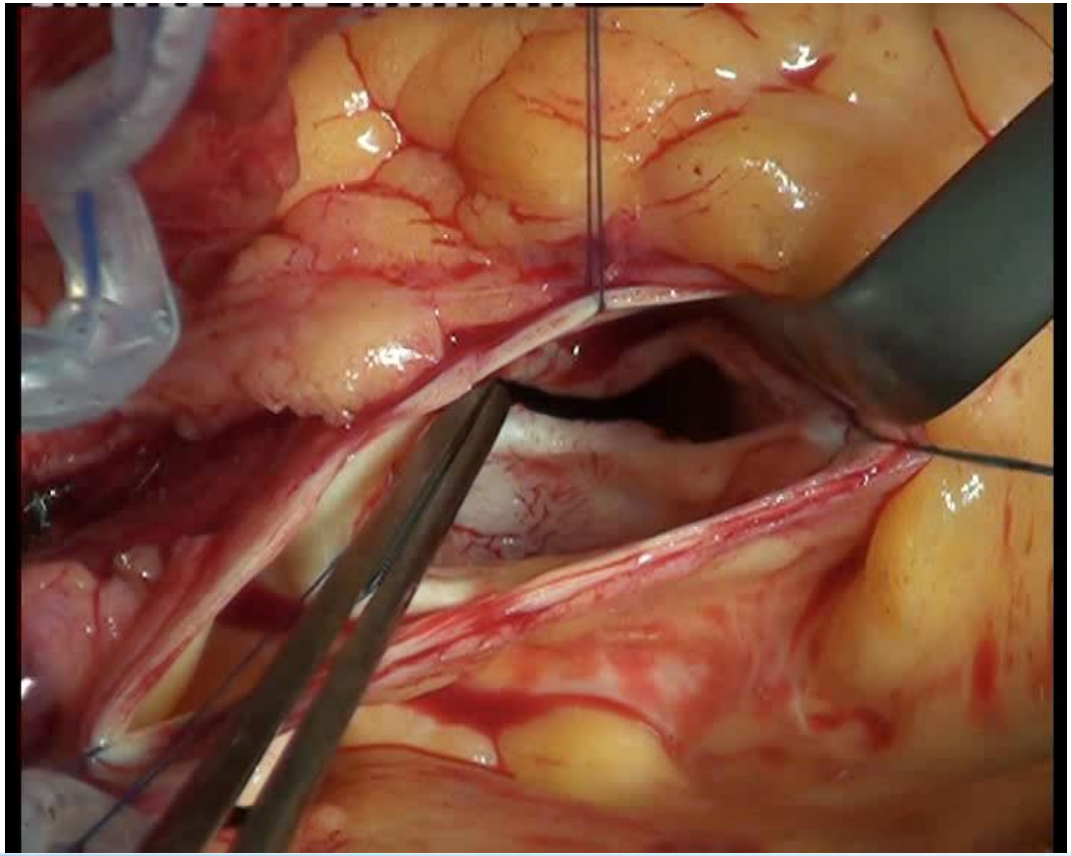

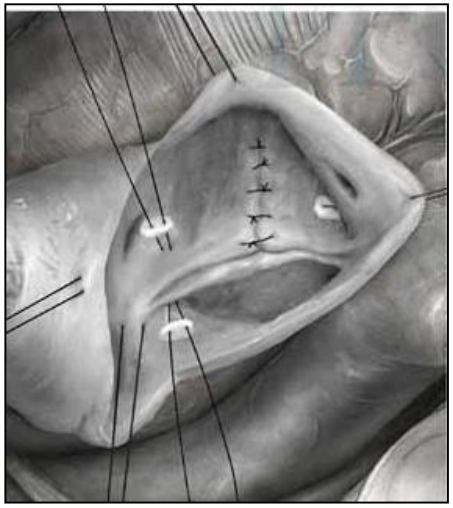

Operative Steps:

5. Correction of AV dilatation:

- ~~Cabrol sutures (subcommissural plication)~~

- suture annuloplasty

- ring annuloplasty

Freedom from Reoperation – all BAV

Effect of Cabrol Sutures

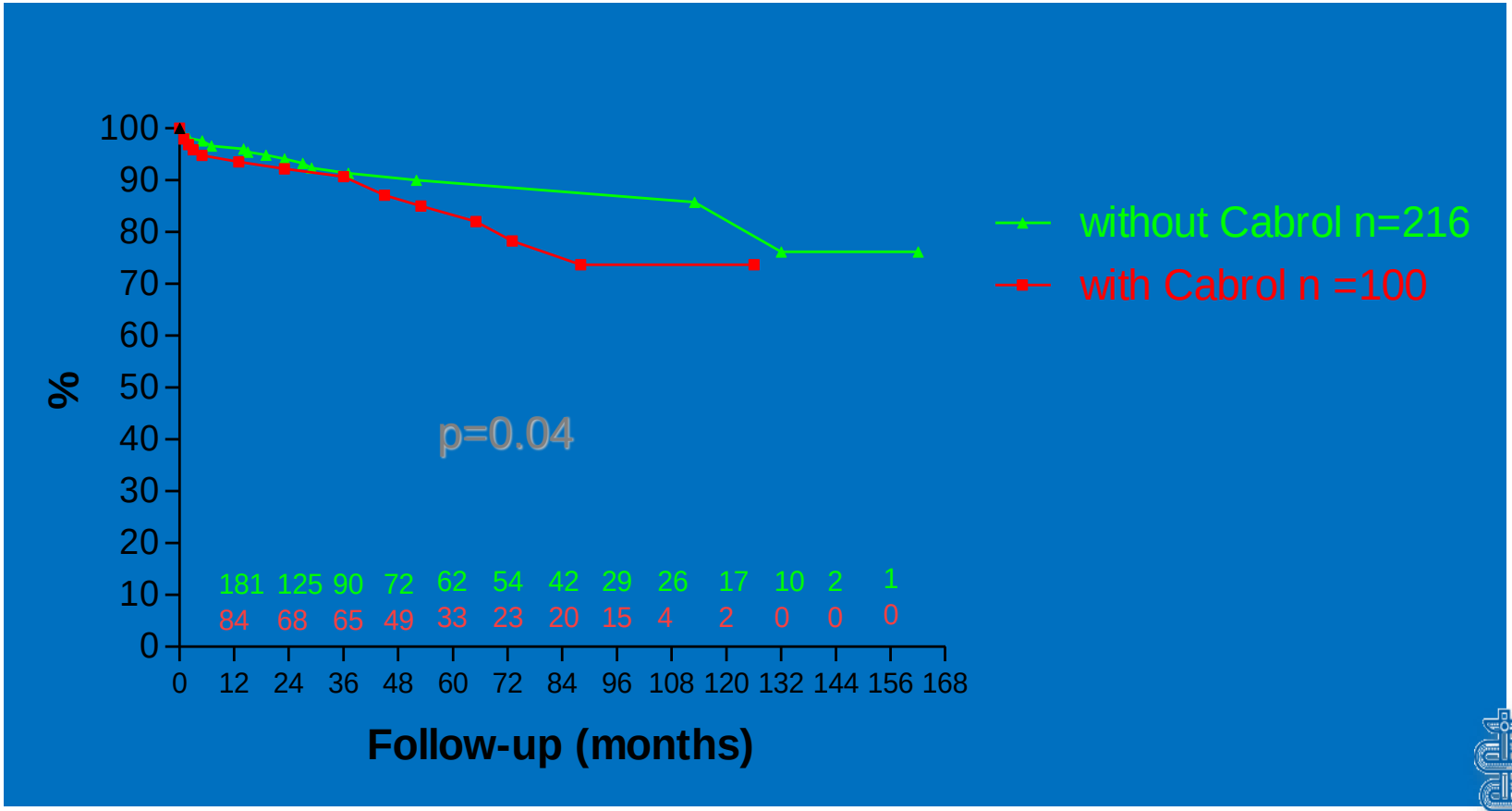

Operative Steps:

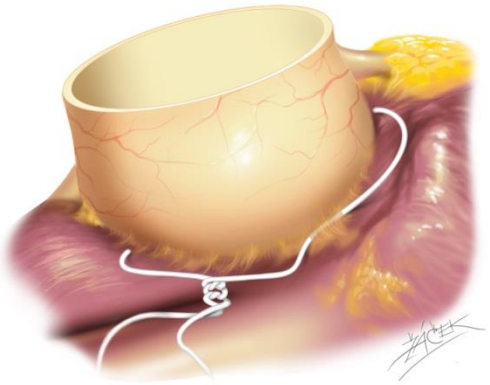

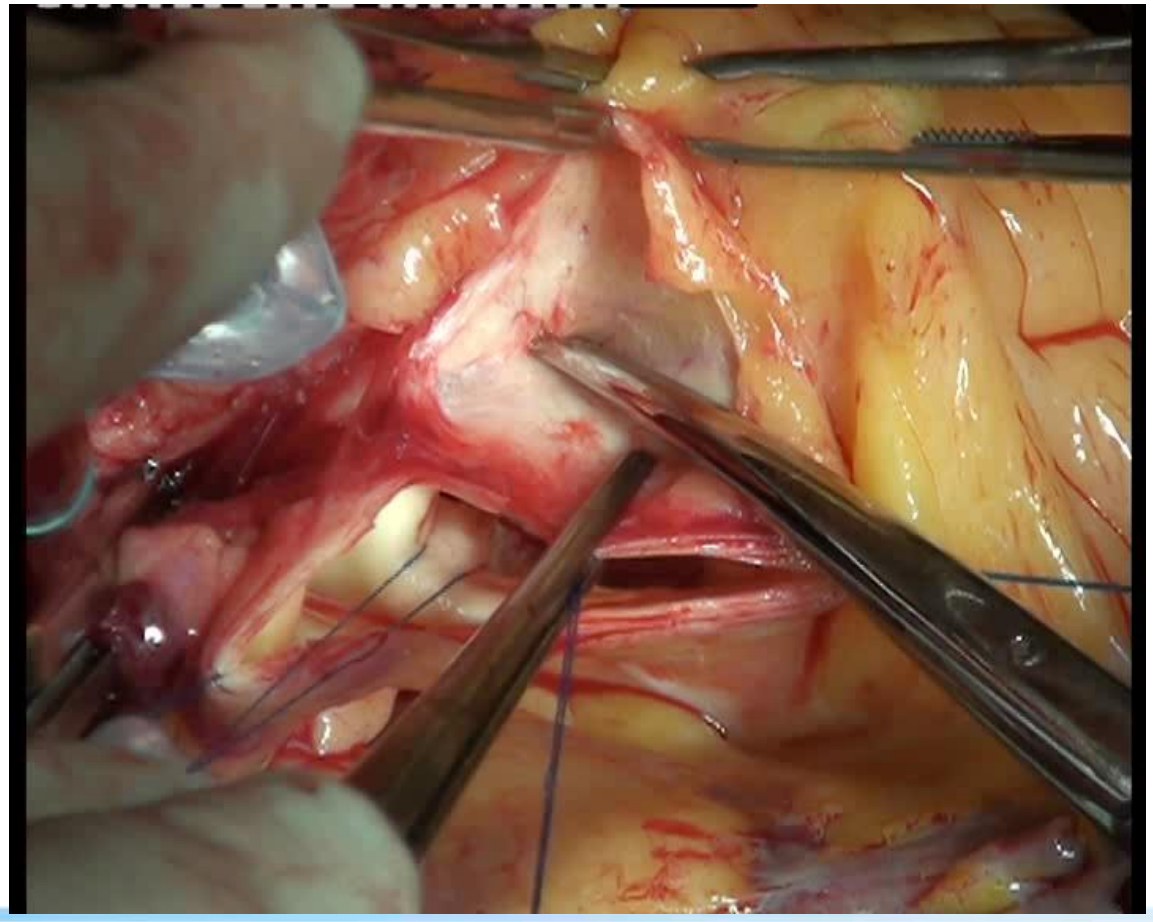

Operative Steps:

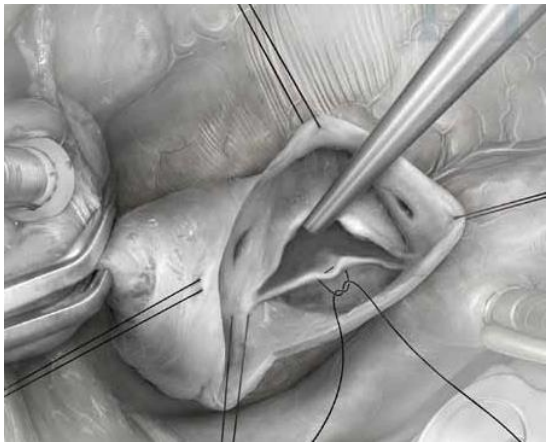

6. Correction of NC cusp prolapse:

- measure effective height
- plicate free margin
- ??

Operative Steps:

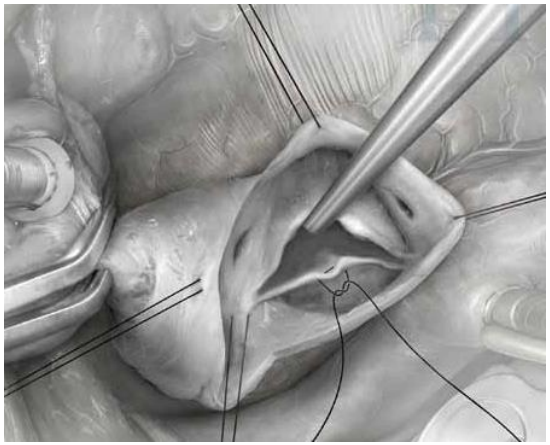

Correction of NC cusp prolapse:

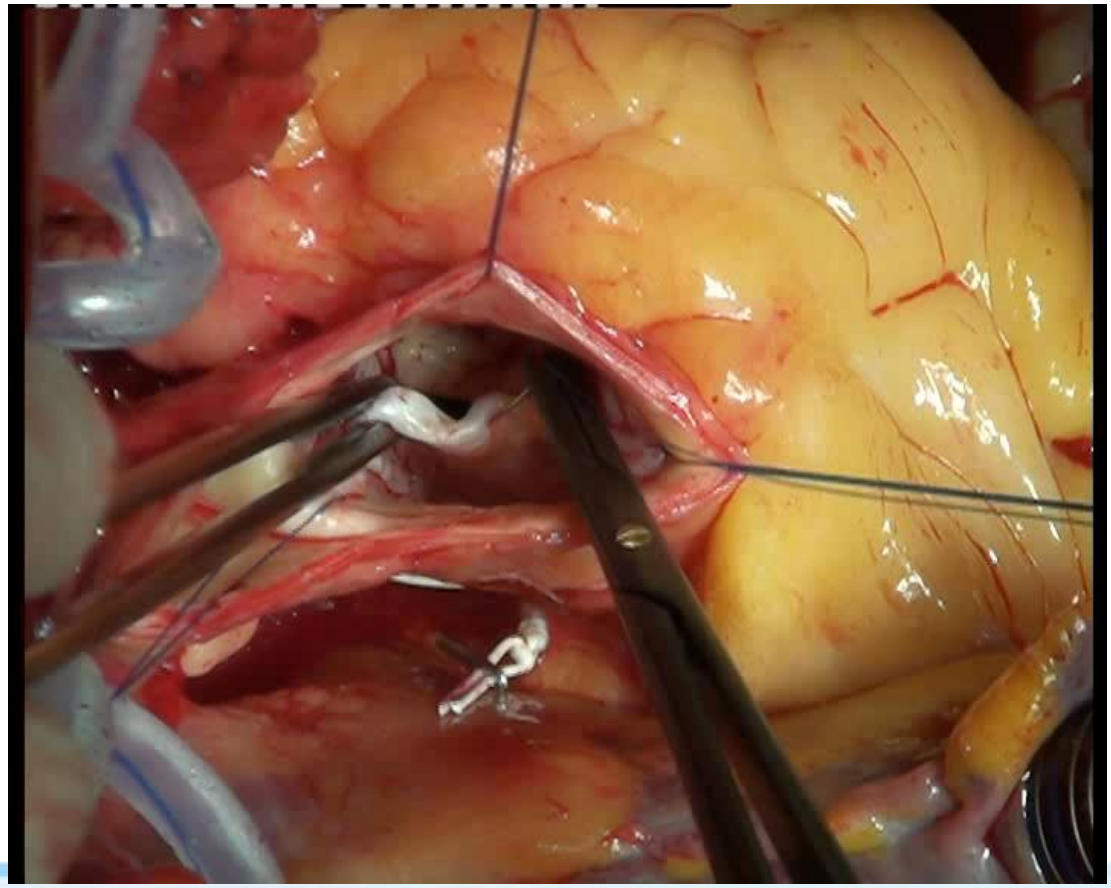

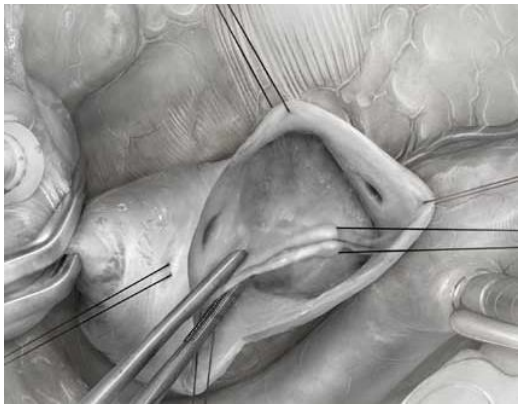

Operative Steps:

<u>Assessment of fused cusp geometry (prolapse):</u>

- stay sutures with equidistant lengths of NC/fused margins from each commissure

Operative Steps:

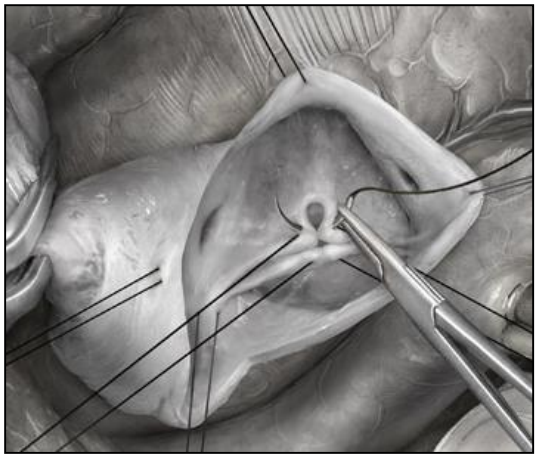

9. Correction of fused cusp geometry (prolapse):

- plication of free margin

- triangular resection

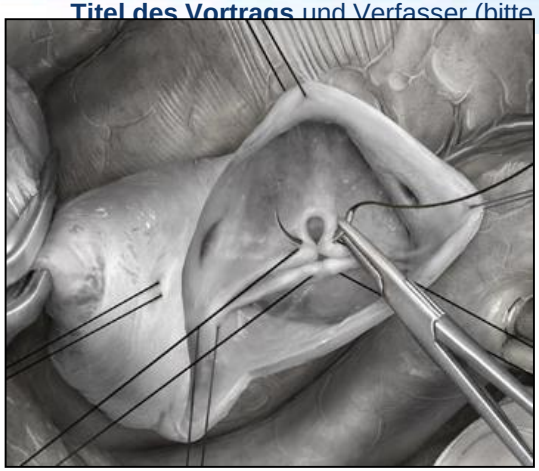

Operative Steps:

Correction of fused cusp geometry (prolapse):

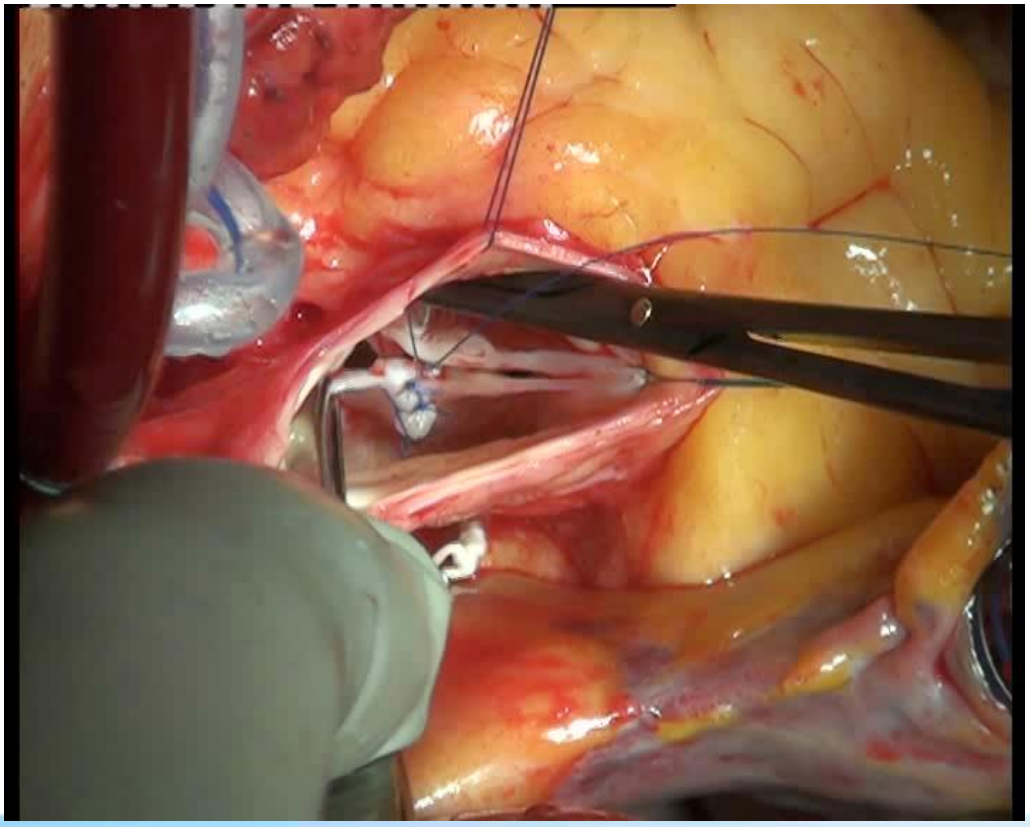

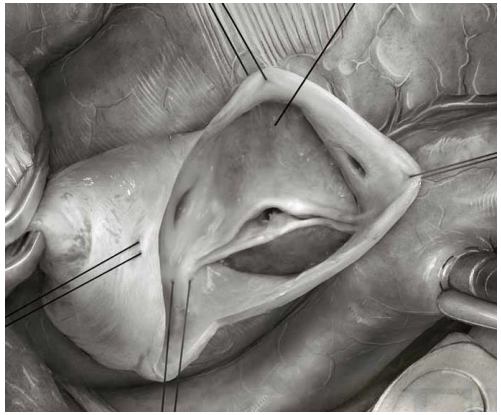

Final check

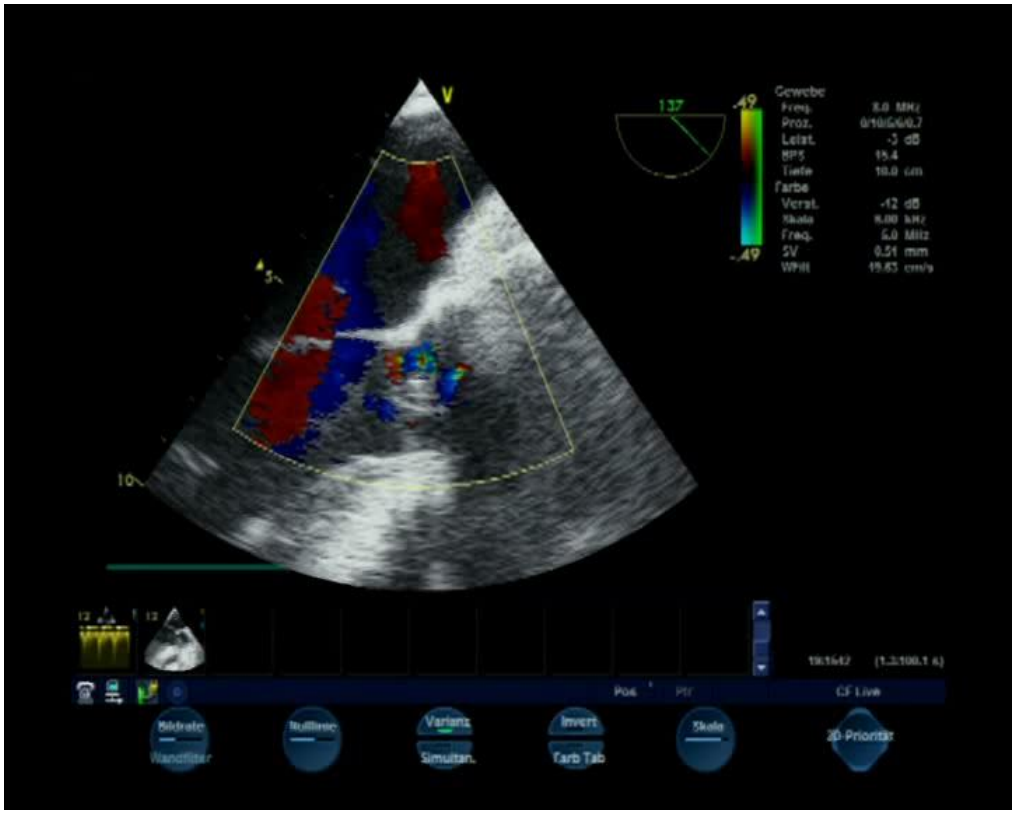
Gewebe
Farbe
Bildrate
Wandfilter
Nullinie
Varianz
Simultan.
Invert
Farb Tab
Skala
2D Prioritär
CF Live

Thank you for your attention



aortic-repair@uks.eu