UKS
Universitätsklinikum
des Saarlandes

12.09.2018

Root Remodeling is the Most Efficient Form of Valve-Preserving Surgery

H.-J. Schäfers
Dept. of Thoracic and Cardiovascular Surgery
Saarland University Medical Center

Disclaimer: I did not invent this operation!

Remodeling of the aortic valve anulus

Isolated aortic valve regurgitation that results from disease that primarily affects the aortic wall can be repaired by remodeling of the aortic anulus to restore its normal geometry. This involves excision of

coronary ostia,
f the coronary
re often present
erience with 10
National Heart
DIOVASC SURG

VALVE-PRESERVING REPLACEMENT OF THE ASCENDING AORTA: REMODELING VERSUS REIMPLANTATION

H.-J. Schäfers, MD, PhD[a]
R. Fries, MD[b]
F. Langer, MD[a]
N. Nikoloudakis, MD[a]
T. Graeter, MD[a]
U. Grundmann, MD[c]

Objective: Aortic valve regurgitation in combination with dilatation of the ascending aorta and root requires a combined procedure to restore valve function and eliminate pathologic dilatation of the proximal aorta. Two techniques have been proposed for this purpose; the aortic root may be either remodeled with an especially configured vascular graft or replaced with reimplantation of the aortic valve within the graft. We have used both techniques depending on the individual pathologic condition of the aortic root. *Methods:* Of 107 patients undergoing operation for proximal aortic disease between October 1995 and November 1997, 40 patients had morphologically intact aortic valve leaflets in conjunction with dilatation of the aortic root. Of these, 15 patients underwent an operation as a surgical emergency for acute aortic dissection type A.

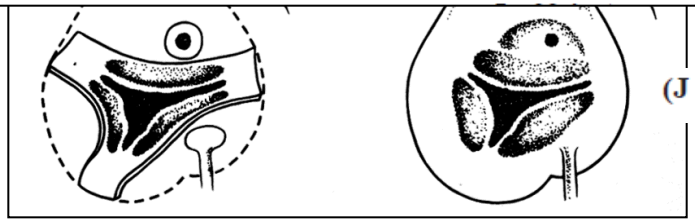

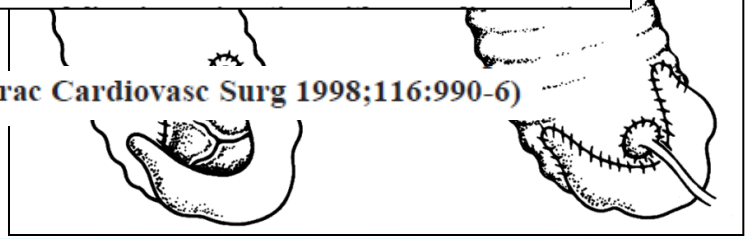

(J Thorac Cardiovasc Surg 1998;116:990-6)

Valve-sparing surgery: Long-term results

David JTCVS 2006

	Freedom from AR > II (10 years)	Freedom from reoperation (10 years)
Reimplantation (n=167)	94%	96%
Remodeling (n=53)	75%	93%

Yacoub JTCVS 1998

	Freedom from AR ≥ II (10 years)	Freedom from reoperation (10 years)
Remodeling (n=158)	64%	89%

Aortic Valve Reimplantation in Ascending Aortic Aneurysm: Risk Factors for Early Valve Failure

Klaus Pethig, MD, Andrea Milz, Christian Hagl, MD, Wolfgang Harringer, MD, and Axel Haverich, MD

Department of Thoracic and Cardiovascular Surgery, Division of Surgery, Hannover Medical School, Hannover, Germany

Background. Aortic root reconstruction by reimplantation of the native valve represents a new therapeutic option for ascending aortic aneurysms. Information about long-term follow-up is limited, and possible predictors for failure of reconstruction have not been evaluated so far.

Methods. After aortic valve reimplantation 101 patients were followed in a prospective observational study. From this cohort the first 75 consecutive patients with a complete 1-year follow-up were chosen for further analysis. Clinical and echocardiographic data were obtained preoperatively, intraoperatively, and early postoperatively, as well as after 1 year of follow-up.

Results. No mortality was observed within the first 30 days. There were 52 male patients, mean age was 49.1 ± 20.6 years, observation period was 35.6 ± 20.6 months, and Marfan's syndrome was present in 22 patients. Although in 67 patients a stable valve function could be demonstrated, 5 patients
sufficiency or had to be o
valve failure (n = 3). An
disease-related, and proc
multivariable approach, c
the graft (as assessed b
identified as being relate
ment of aortic insufficien
tube graft (type A) resulte
grade of 0.3 ± 0.5 as comp
0.6 for a coaptation type
0.001).

Conclusions. Aortic val
ing alternative to allopro
A level of coaptation within the tube graft is essential to achieve valve competence.

(Ann Thorac Surg 2002;73:29–33)

© 2002 by The Society of Thoracic Surgeons

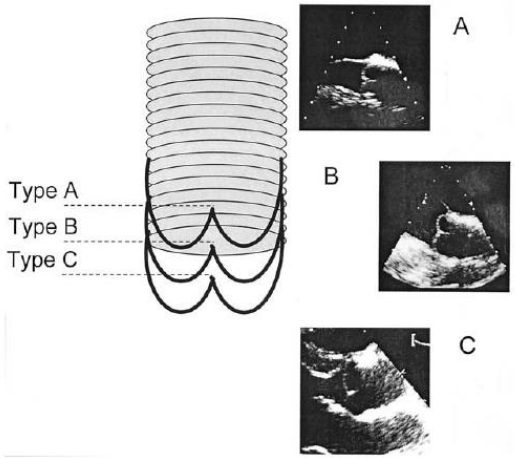

Fig 1. Type of coaptation of the aortic valve as assessed by echocardiography. Type A has the coaptation point ≥ 2 mm within the prosthesis. Type B has coaptation close to the lower border of the Dacron graft. Type C has coaptation ≥ 2 mm below the prosthesis.

Preserv

Hans-Joach
and Hennir

Department of T

Background.
common reasor
with aortic dil
have observed
used different
Methods. Bet
regurgitant bic
The aorta was
isolated repair.
sural level (n =
plus supracom
tients, aortic di
by root remode
Results. Hos
ity were low i
was significant

lom from aortic
d between 91%
years was 97%
pair plus aortic
se was the most

bicuspid aortic
f aortic pathol-
oot remodeling
n patients with
te valve repair
omplex alterna-
ided if the as-

2007;83:S740–5)
oracic Surgeons

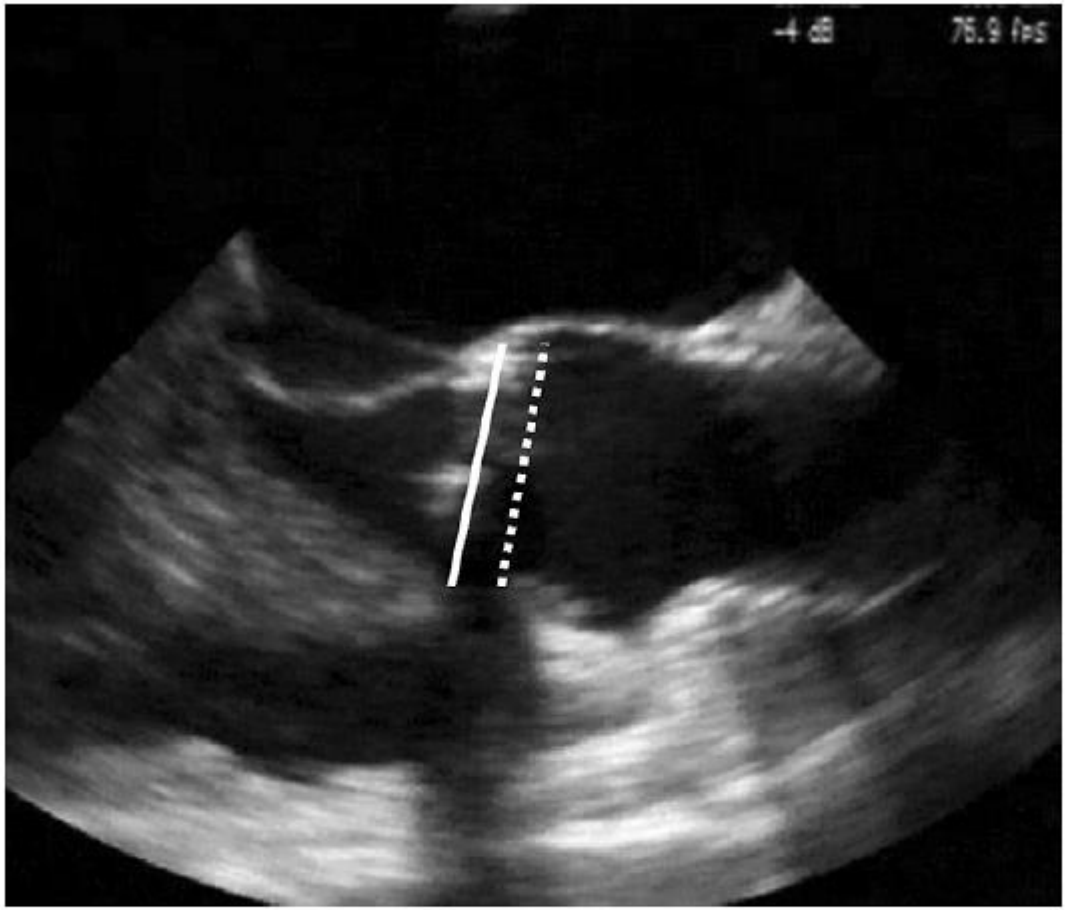

Fig 5. Typical echocardiogram of a patient with symmetric prolapse after separate valve repair and aortic replacement. The dotted line marks the coaptation level of the free margins, the solid line, the level of the aortic insertion. The most striking finding is an abnormally low height difference of 4 mm between central cusps and aortic insertion.

Reduction of STJ and Cusp Prolapse

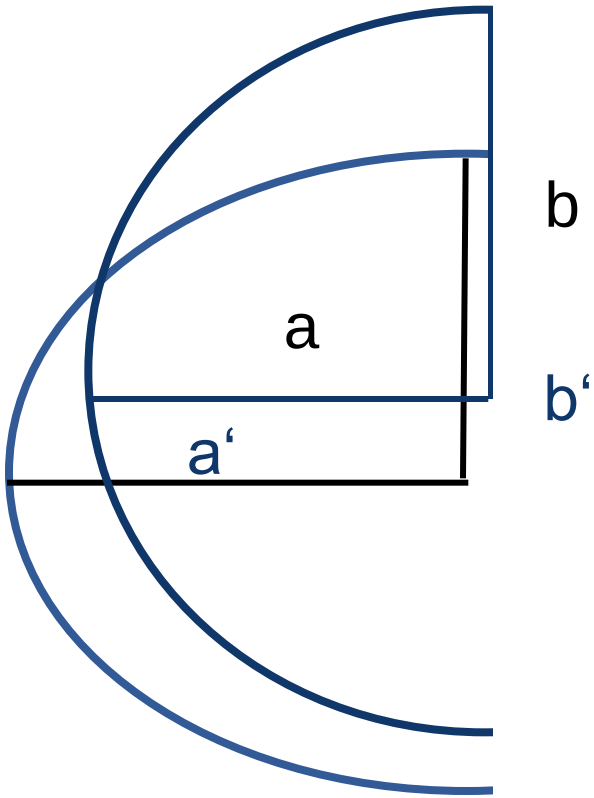

$$C_E = \pi \times [3/2\times(a+b) - \sqrt{a\times b}]$$

$b \approx r_{aorta}$

$a \approx r_{cusp}$ $\Longrightarrow$ $r_{cusp} \approx 1 / r_{aorta}$

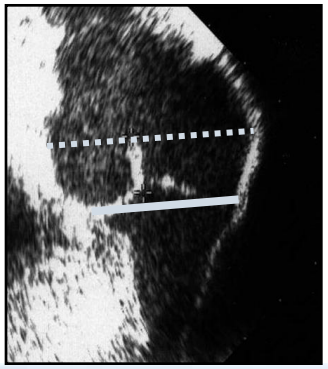

A new approach to metry

Hans-Joachim Schäfers, MD, Phl rg/Saar, Germany

Repair of the aortic valve i lardize intraoperatively, and these the treatment of aortic re iguration only in conjunction with the aortic valve can be ca dilatation, or a combinati a normal aortic valve is not only tional reconstruction, all pathologic c s but also the configuration of the addressed. Good results have been ac ght difference between the central aortic replacement,[1] but isolated aor tion lines (Figure 1, *A*).[3] We have cusp repair for prolapse) still rema sy and reproducible measurement judgment. ve call *effective height* as opposed

The main problem in repair of a his measurement allows for iden- pathology and the repair result. R ive cusps and assessment of pro- quantified preoperatively by means o ir. operative measurements. Cusp geom

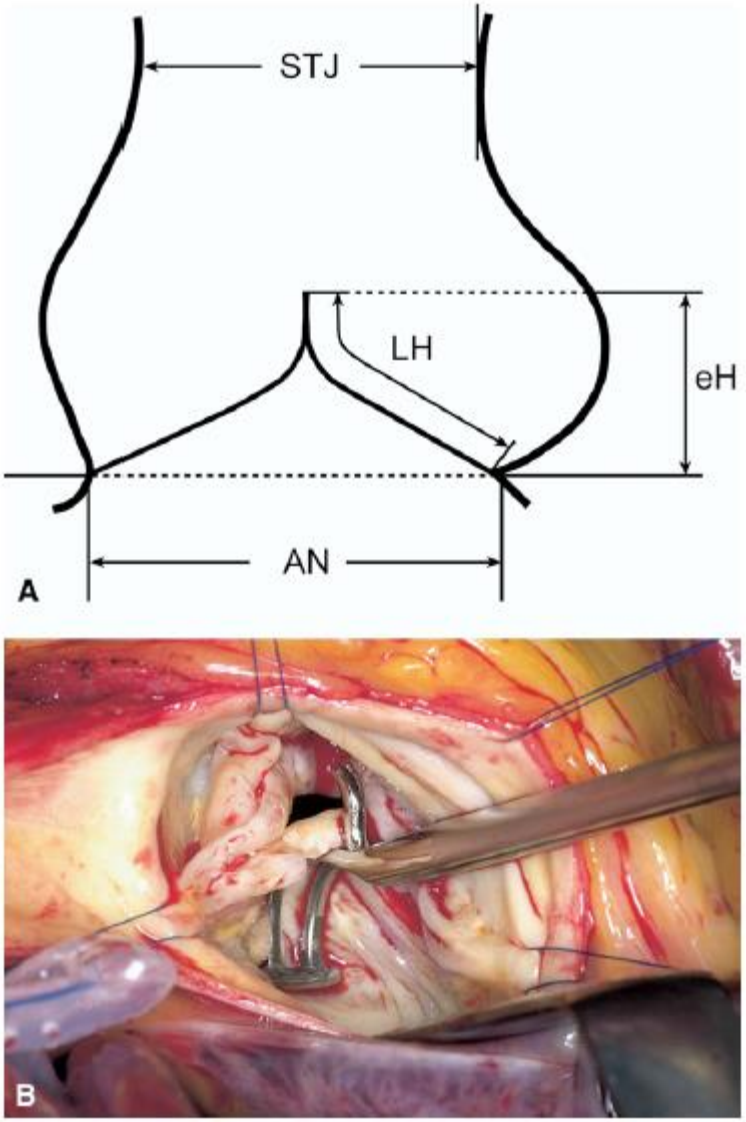

The Journal of
Thoracic and Cardiovascular Surgery

Valve-preserving aortic replacement: Does the additional repair of leaflet prolapse adversely affect the results?

Frank Langer, Thomas Graeter, Nikolaous Nikoloudakis, Diana Aicher, Olaf Wendler and Hans-Joachim Schäfers

J Thorac Cardiovasc Surg 2001;122:270-277

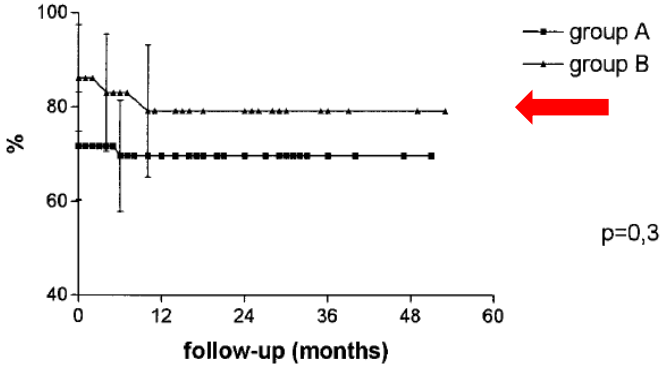

Individuals at risk

A:	60	30	18	8	2
B:	36	18	12	4	2

Figure 4. Freedom from aortic regurgitation of grade 1 or greater. *Error bars* represent 95% confidence intervals (*P* > .2).

Reimplantation

Remodeling

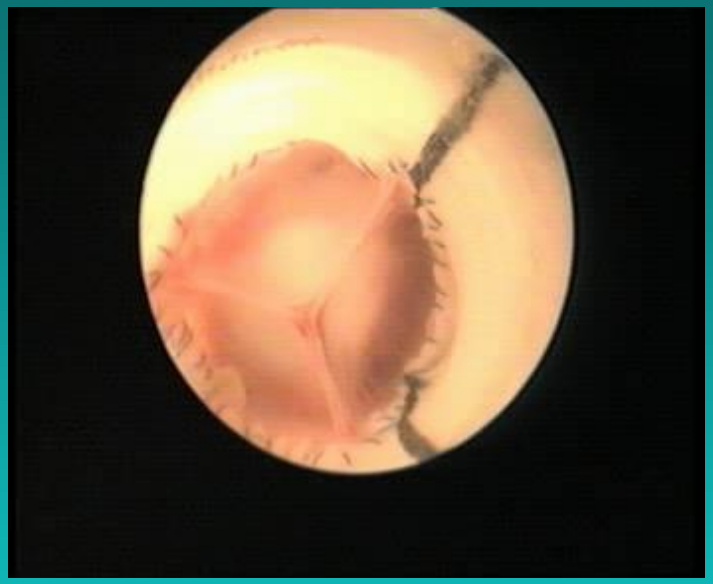

Systolic Energy Loss

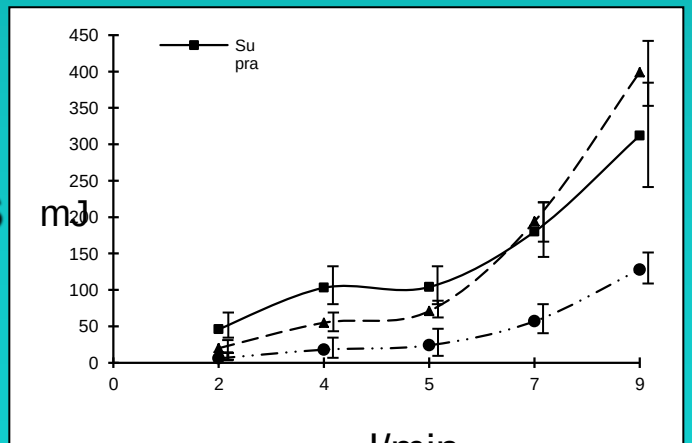

2 l/min

Valve-Sparing Surgery

Cusp Changes after Reimplantation

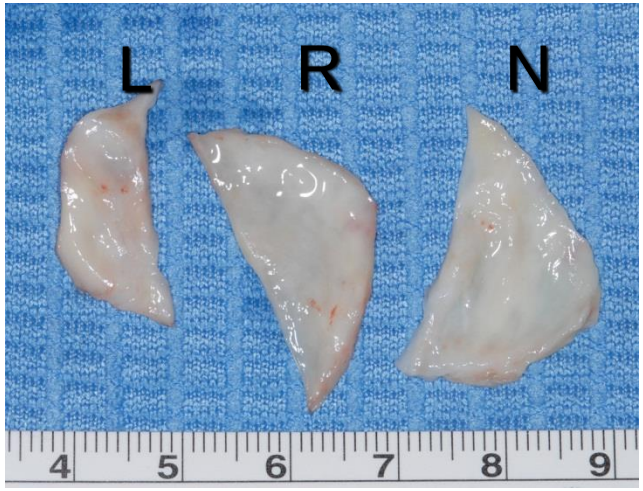

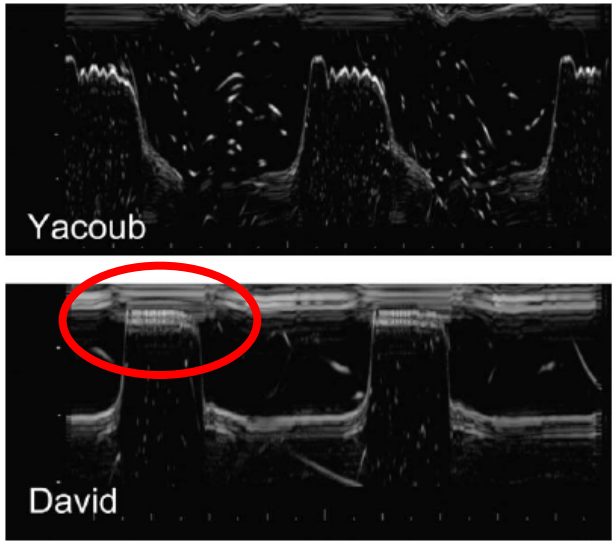

Figure 3. Typical M-mode recording of aortic valve motion after reimplantation *(David)* and remodeling *(Yacoub)*.

In vitro comparison of aortic valve movement after valve-preserving aortic replacement

Roland Fries, MD,[a] Thomas Graeter, MD,[b] Diana Aicher, MD,[b] Helmut Reul, MD,[c] Christoph Schmitz,[c] Michael Böhm, MD,[a] and Hans-Joachim Schäfers, MD[b]

Aortic Sinus Anatomy

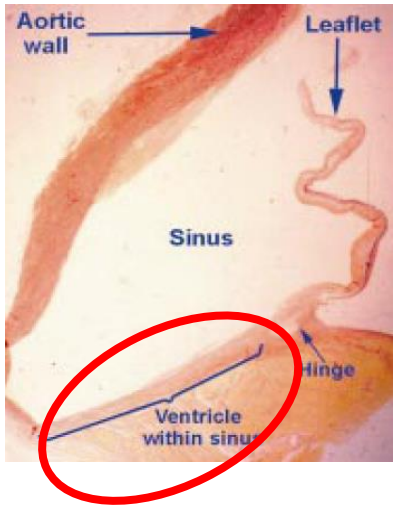

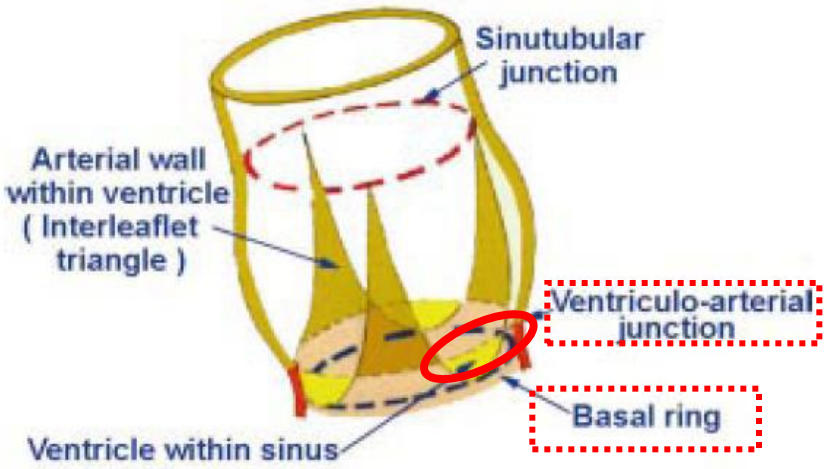

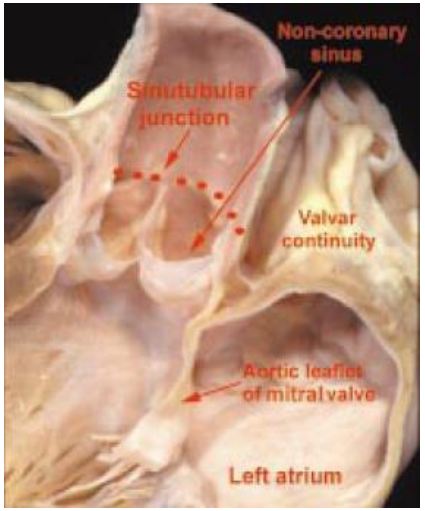

Crescents of LV muscle at base of (left and) right sinus (variable)

Anderson Heart 2000

	Remodeling (N=494)	Reimplantation (N=29)
Age (yrs)	58 ± 15	42 ± 16
Sex (m/f)	372 / 122	20 / 9
Tricuspid AV	333	27
BAV/UAV	154/7	2/-
Diagnosis: Aneurysm	428	23
AADA	59	6
CADA	7	-
Marfan	13	12

	Remodeling (N=494)	Reimplantation (N=29)
Concomitant procedures		
CABG	89*	1
MVR	16	1
part. arch	131*	8
tot. arch	26	2
Myoc. Ischemia (min)	82 ± 20*	112 ± 24

* $p<0.05$

Aortic root remodeling: Ten-year experience with 274 patients

Diana Aicher, MD, Frank Langer, MD, Henning Lausberg, MD, Benjamin Bierbach, MD, and Hans-Joachim Schäfers, MD

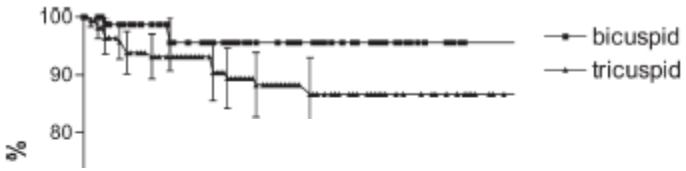

TABLE 3. Reasons for reoperation after root remodeling, stratified for aortic valve anatomy

Reasons for reoperation	BAV	TAV
Symmetric cusp prolapse	2	4
Dilatation at the aortoventricular level	0	1
Endocarditis	0	1
Secondary cusp retraction	0	1

BAV, Bicuspid aortic valve; *TAV*, Tricuspid aortic valve.

The Journal of Thoracic and Cardiovascular Surgery • October 2007

Preoperative aortic root geometry and postoperative cusp

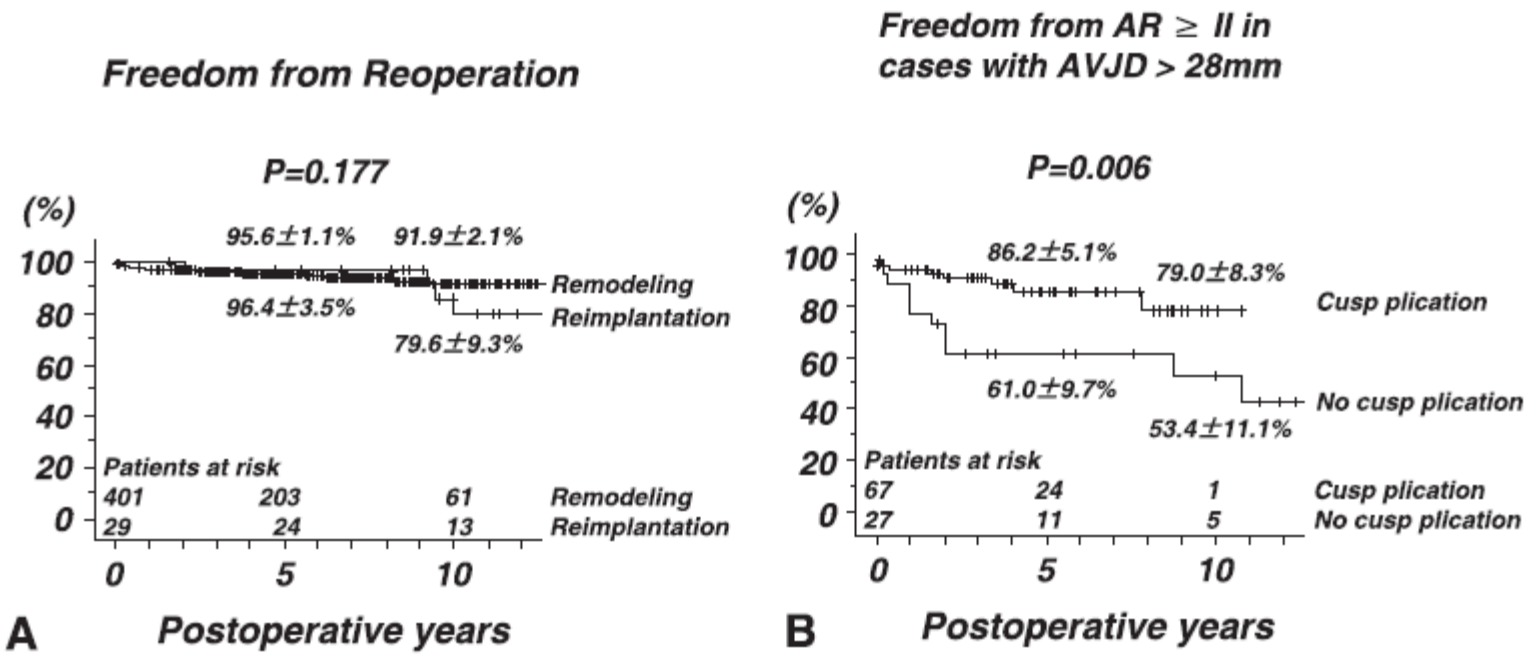

FIGURE 3. A and B, Freedom from reoperation of patients who underwent remodeling (*thin line*) or reimplantation (*bold line*).

Root Repair – Technical Options

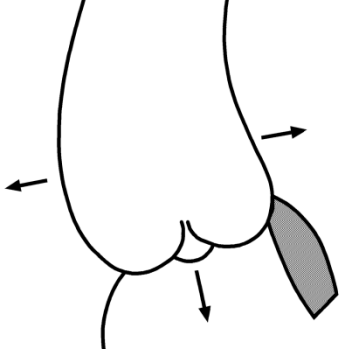

Subcommissural Plication

(Cabrol 1966)

Suture Annulopasty
(AVJ > 27mm)

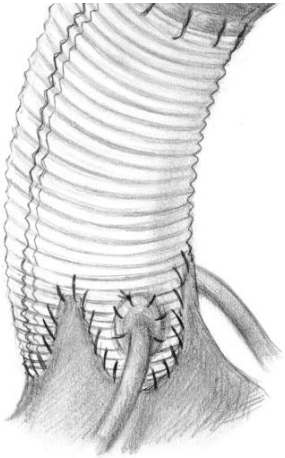

+

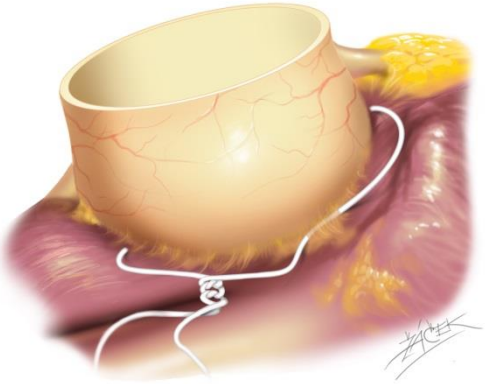

Aortic annulus does not dilate over time after aortic root remodeling with or without annuloplasty

Takashi Kunihara, MD, PhD,[a] Satoshi Arimura, MD,[a] Fumihiro Sata, MD, PhD,[b] Christian Giebels, MD,[c] Ulrich Schneider, MD,[c] and Hans-Joachim Schäfers, MD, PhD[c]

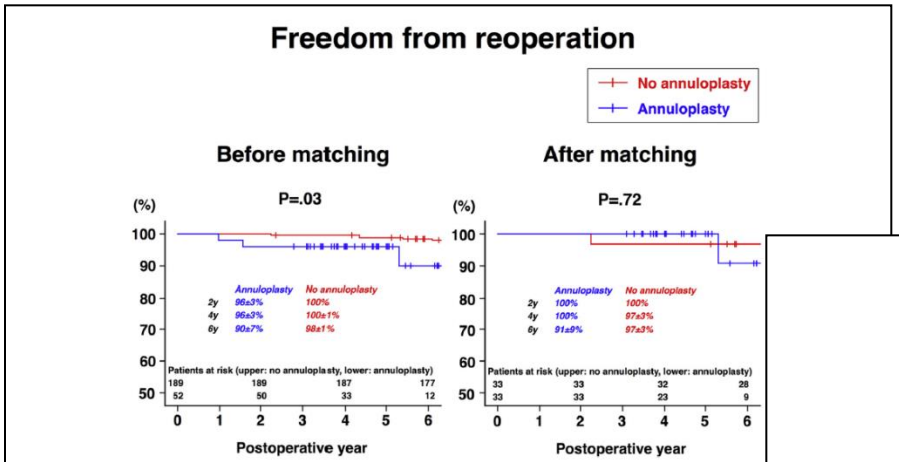

FIGURE 2. Freedom from reoperation on the aortic valve or root in patients with (*blue line*) or without (*red line*) annuloplasty before (
propensity score matching.

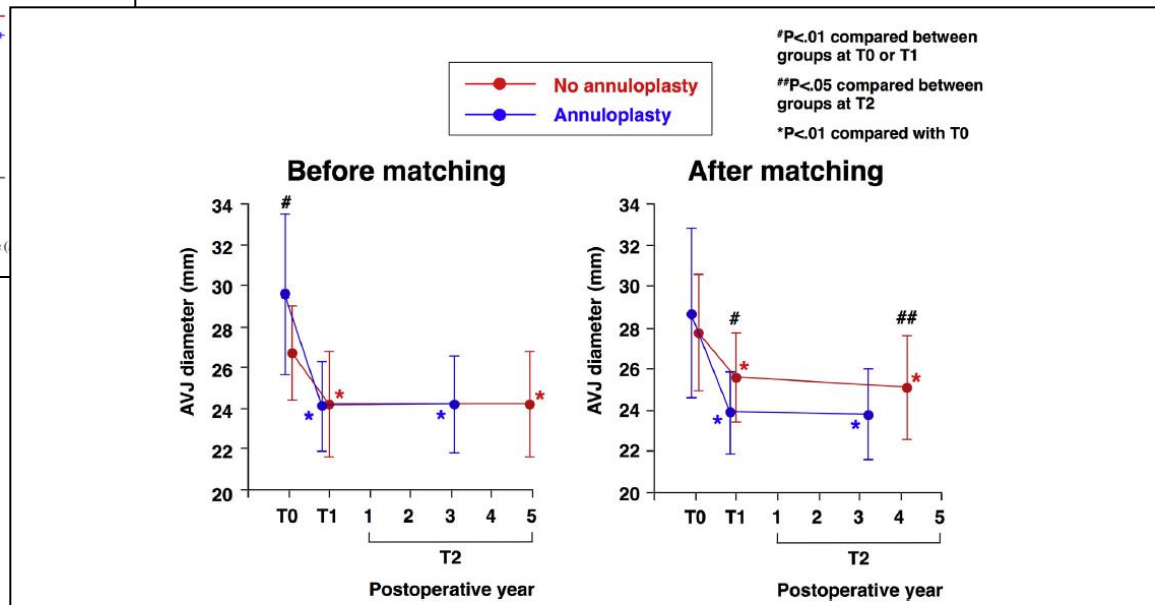

FIGURE 3. Time course of AVJ diameter in patients with (*blue line*) or without (*red line*) annuloplasty before (*left*) and after (*right*) propensity score matching. See text for each time point. *AVJ*, Aortoventricular junction.

Current Readings: Aortic Valve–Sparing Operations

Tirone E. David, MD[*,†]

Semin Thoracic Surg 26:231–238 © 2014

aortic aneurysms and normal aortic annulus. Thus, both techniques are useful in preserving the aortic valve. With either technique, restoration of normal aortic annulus and cusp geometry is the single most important technical aspect of these operations. In addition to having a competent valve with no

this maneuver can correct the problem. Thus, selection of the size of the graft is a complex problem in aortic valve reimplantation. We have stated

in aortic valve reimplantation. We have stated numerous times that reimplantation of the aortic valve is a far more complex operation than remodeling of the aortic root because it alters the geometry of

root aneurysm associated with ascending aor
aneurysm and normal aortic ann
very well after the remodeling pr
technically less demanding than
the aortic valve. Younger patient

postoperatively.[13] Finally, aortic valve–sparing operations are an alternative to composite replacement of the aortic valve and ascending aorta, and as there is no evidence of their superiority, the surgeon "has to have an open and receptive mind but a balanced view" of these operations and give the patient what is best in his or her hands.

step of

The fully protected aortic valve?



Conclusions

Root remodel chemia than valve reimplantation

RR can be ap of sinus anatomy)

RR leads to n

RR may lead maller graft), but this can be detect p configuration determines du

Addition of an f competent valves (durability?)

RR is my preferred form or valve-preserving root replacement, (at least for all patients without connective tissue disease).