MAYO CLINIC

Comprehensive Intra-operative Echocardiography in the Adult:

Anatomy Mechanisms Communication

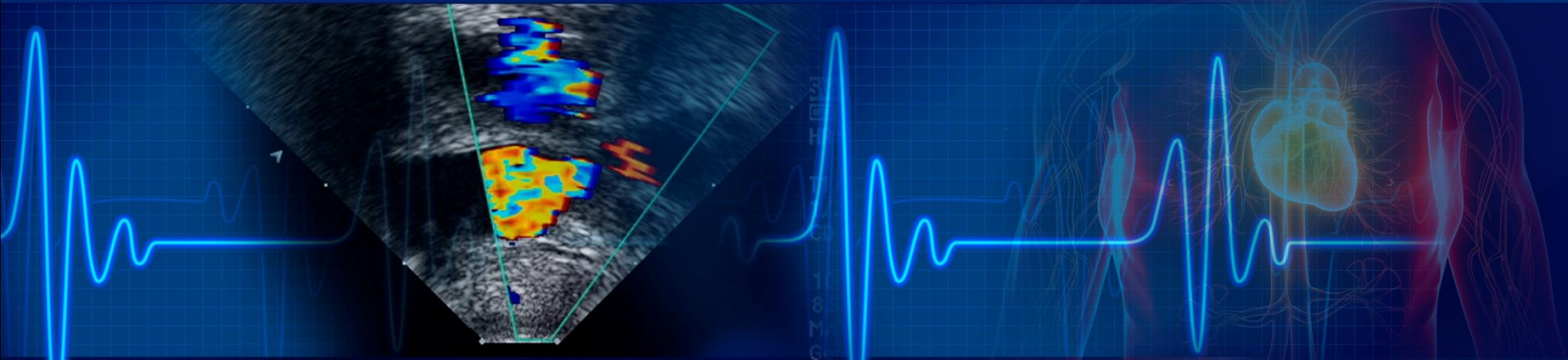

Hector I. Michelena, MD, FACC, FASE
Professor of Medicine
Director, Intra-operative Echocardiography
Michelena.hector@mayo.edu

©2017 MFMER | 3645766-1

Disclosures

None $$

Search for the truth

MAYO CLINIC

©2017 MFMER | 3645766-2

“Everything should be made as simple as possible, but not simpler.”

Albert Einstein



MAYO CLINIC

©2017 MFMER | 3645766-3

PROGRESS IN CARDIOVASCULAR DISEASES 57 (2014) 74–90

Available online at www.sciencedirect.com

ScienceDirect

www.onlinepcd.com

Adult Perioperative Echocardiography: Anatomy, Mechanisms and Effective Communication

Hector I. Michelena[a,], Rakesh M. Suri[b], Joseph Malouf[a], Maurice Enriquez-Sarano[a], Sunil V. Mankad[a]*

[a]Division of Cardiovascular Diseases, Mayo Clinic, Rochester, MN, USA
[b]Division of Cardiovascular Surgery, Mayo Clinic, Rochester, MN, USA



REVIEW

Mayo Clin Proc. 2010;85(7):646-655

Intraoperative Echocardiography in Valvular Heart Disease: An Evidence-Based Appraisal

HECTOR I. MICHELENA, MD; MARTIN D. ABEL, MD; RAKESH M. SURI, MD, PHD; WILLIAM K. FREEMAN, MD; ROGER L. CLICK, MD, PHD; THORALF M. SUNDT, MD; HARTZELL V. SCHAFF, MD; AND MAURICE ENRIQUEZ-SARANO, MD

MAYO CLINIC

©2017 MFMER | 3645766-4

What is Peri-op echo?

1. Pre-operative imaging – TTE // TEE
   Defines problem and operability, i.e. MR, AR
2. Intra-operative Imaging – IOTEE
   a. Pre-bypass – Confirm, refine, search
   b. Post-bypass – Most important, real-time clinical decision-making
3. Pre-discharge TTE
   "fingerprint" new baseline

MAYO CLINIC

©2017 MFMER | 3645766-5

Intra-operative Imaging – IOTEE

a. Pre-bypass – Confirm, refine, search

b. Post-bypass – Most important, real-time clinical decision-making

Intra-operative TEE is a mature imaging technique that represents the primary surgical-quality control method for cardiac surgery worldwide

MAYO CLINIC

©2017 MFMER | 3645766-6

What is the quality of evidence supporting it?

Is it comfort-testing?

MAYO CLINIC

©2017 MFMER | 3645766-7

REVIEW

Mayo Clin Proc. 2010;85(7):646-655

Intraoperative Echocardiography in Valvular Heart Disease: An Evidence-Based Appraisal

Hector I. Michelena, MD; Martin D. Abel, MD; Rakesh M. Suri, MD, PhD; William K. Freeman, MD; Roger L. Click, MD, PhD; Thoralf M. Sundt, MD; Hartzell V. Schaff, MD; and Maurice Enriquez-Sarano, MD

- No randomized outcomes data support its use
- Excellent safety record (<0.1 % mortality, ≤0.2% morbidity)
- Prospect of effectively treating post-CPB residual abnormalities before patient leaves OR
- Permit inference of improved patient outcomes from non-randomized test-accuracy studies
- **The impact of IOTEE is measured by the amount of non-planned surgical modifications elicited**

MAYO CLINIC

©2017 MFMER | 3645766-8

Studies Addressing the Specific Impact of IOTEE in VHD Surgery

Reference	Design	Year	No. pt	Valve surgery (%)	Pre-CPB impact (%)	Post-CPB findings	Second pump run (%)
Sheikh et al	Prospective Nonconsecutive	1895-1988	154	Mitral surgery (60) (repair [26]) Aortic surgery (40) (repair [11])	9	Residual regurgitation	6.0 All mitral surgery
Grimm & Stewart	Retrospective Nonconsecutive	1984-1996	4066	Mitral repair (75) Aortic repair (12) Tricuspid repair (13)	NS	Inadequate repair Residual regurgitation	7.0 Total 5.0 Mitral 1.8 Aortic 0.2 Tricuspid
Mishra et al	Prospective Nonconsecutive	1993-1997	1356	Mitral (62) (repair or MVR) AVR (38)	13	Inadequate repair	2.0 All mitral repair
Click et al	Prospective Nonconsecutive	1993-1997	2369	Mitral repair (36) MVR (18) AVR (30) Aortic repair (5) Other (11)	14	Inadequate repair Perivalvular leak LVOT obstruction	2.0 All mitral repair
Nowrangi et al	Retrospective Nonconsecutive	1993-1996	383	AVR for aortic stenosis (100)	7	New RWMA	0.0
Shapira et al	Retrospective Nonconsecutive	1999-2003	352	MVR (47) AVR (43) TVR (10)	29	Perivalvular leak Immobilized leaflet Coronary obstruction	4.0 Total 2.0 MVR 1.7 AVR 0.3 TVR
Bajzer et al	Prospective Nonconsecutive	1990s	335	Tricuspid surgery (100) (repair or replacement)	6	Failed repair	4.0
Eltzschig et al	Retrospective	1990-2005	6525	MVR or repair (28)	9	Inadequate mitral or	3.0 Total
Summery		1984-2005	15,540	Mitral surgery (56) Aortic surgery (36) Tricuspid (8)	11 (n=11,474)	Abnormal valve result most common	4.0

4% VHD vs 2% general vs 0.8% CABG

MAYO CLINIC

©2017 MFMER | 3645766-9

Intra-operative Imaging – IOTEE

a. Pre-bypass – Confirm, refine, search

b. Post-bypass – Most important, real-time clinical decision-making

Prebypass general/AR

MAYO CLINIC

©2017 MFMER | 3645766-10

The aorta!!!

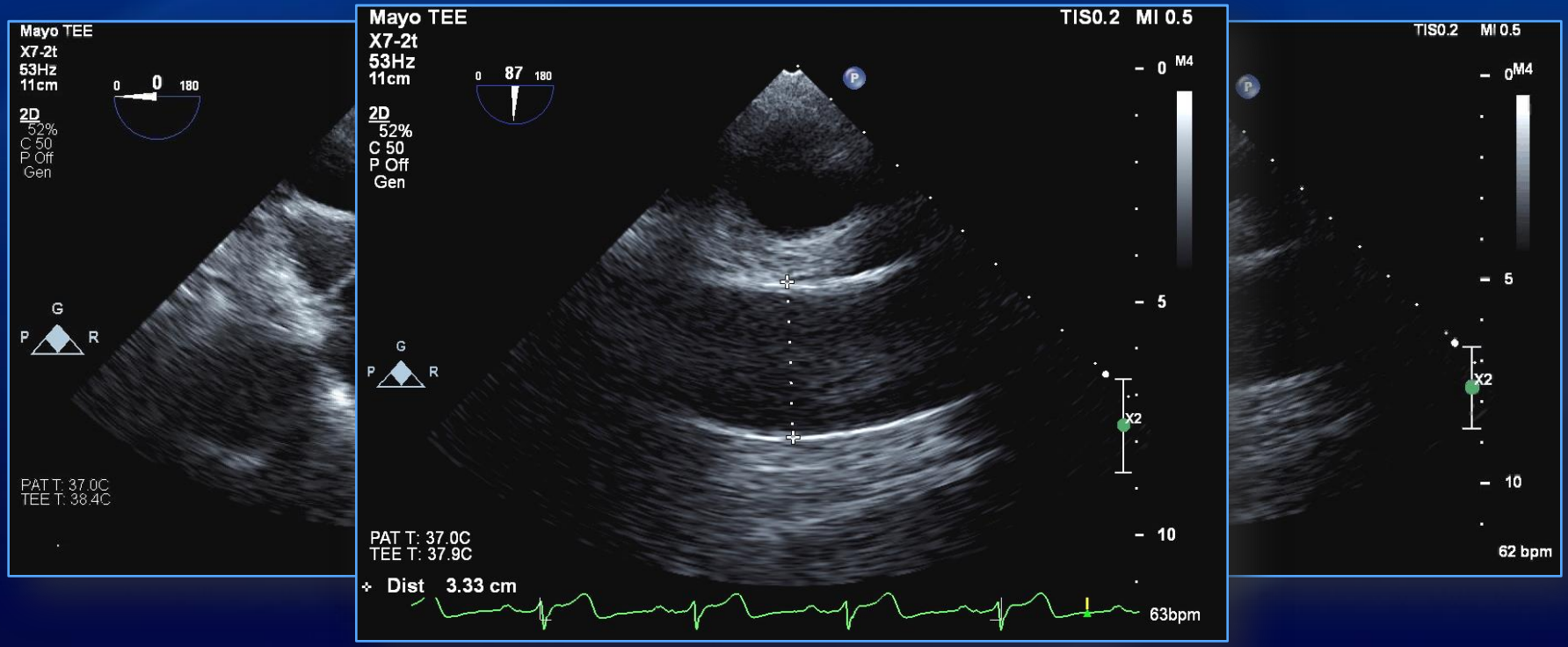

©2017 MFMER | 3645766-11

The aorta!!!

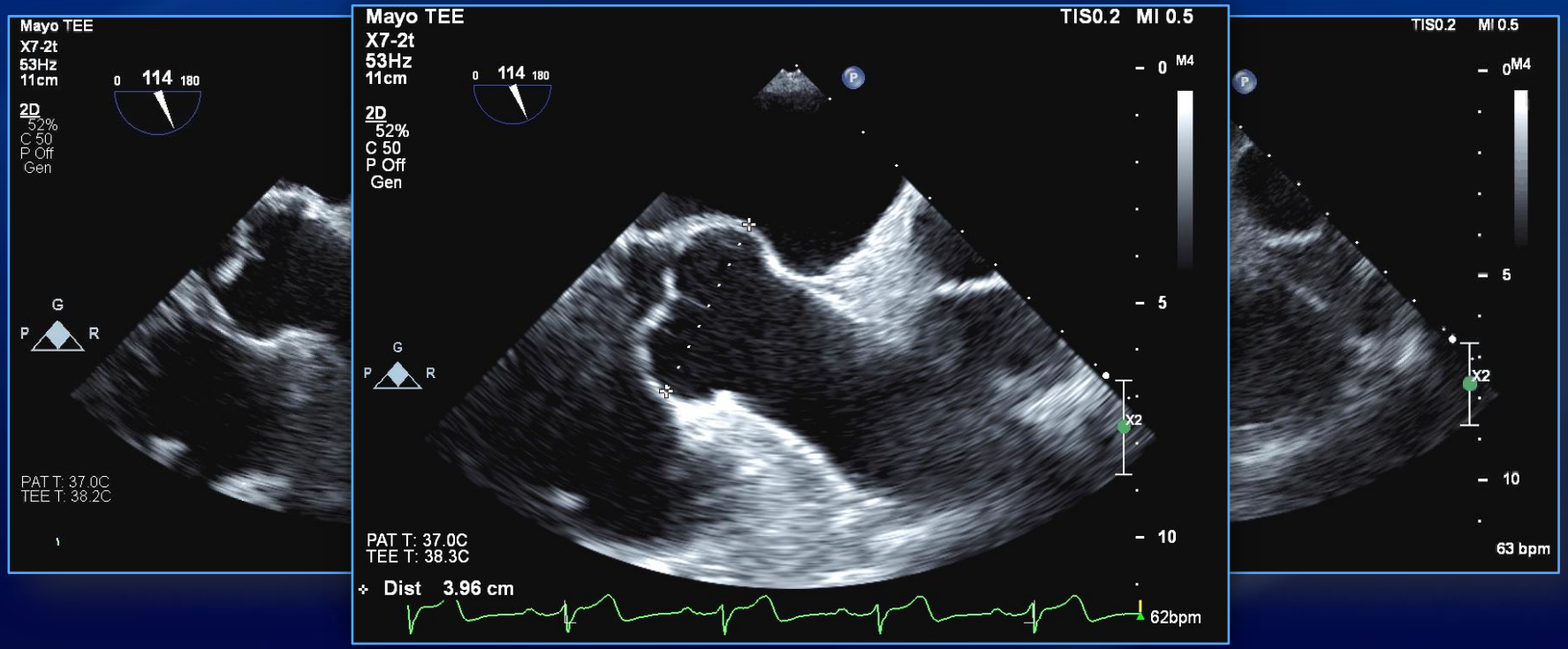

©2017 MFMER | 3645766-12

Ascending aorta (pre-cannulation)

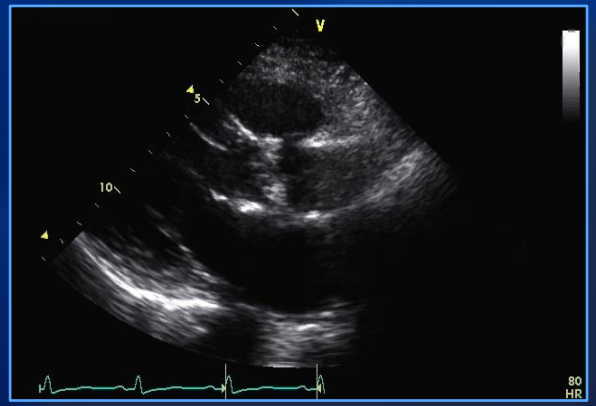

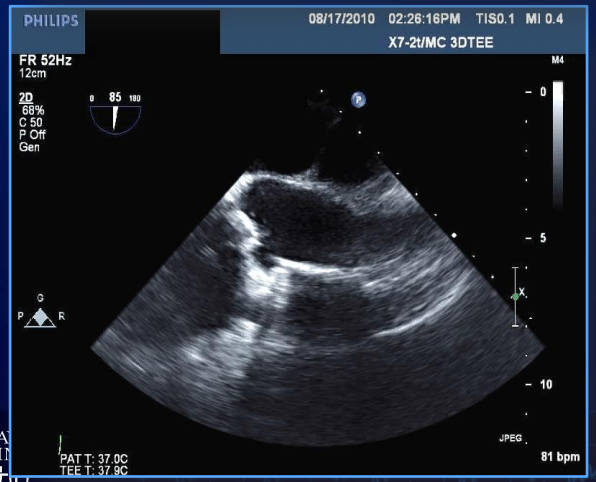

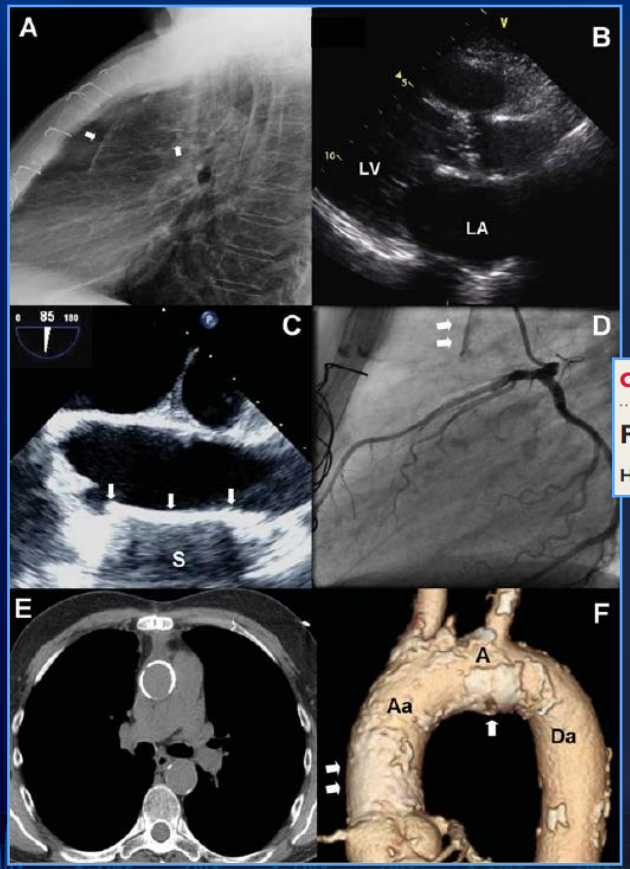

CARDIOVASCULAR FLASHLIGHT

Porcelain aorta

Hector I. Michelena*, Charanjit S. Rihal, and Maurice Enriquez-Sarano

©2017 MFMER | 3645766-13

Ascending aorta (pre-cannulation)

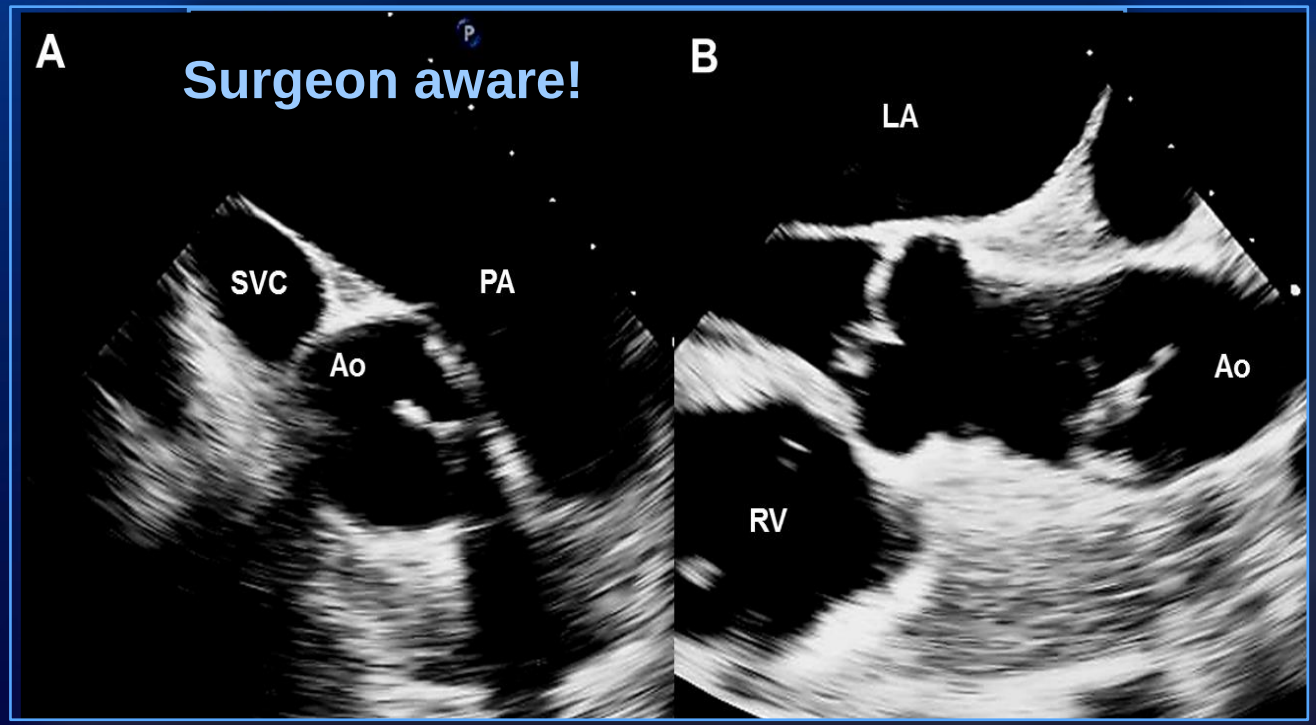

MAYO CLINIC
©2017 MFMER | 3645766-14

Pre-bypass incidentals…

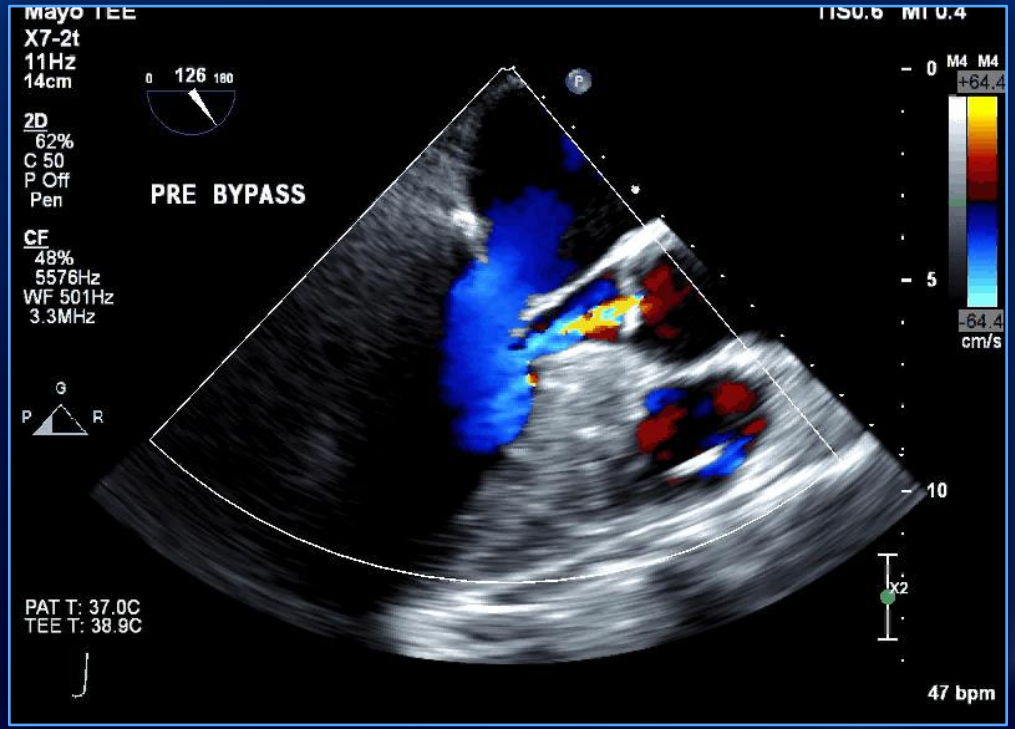

MAYO CLINIC
©2017 MFMER | 3645766-15

Pre-bypass incidentals…

MAYO CLINIC
©2017 MFMER | 3645766-16

Pre-bypass incidentals…
AR – cardioplegia (Vena contracta)

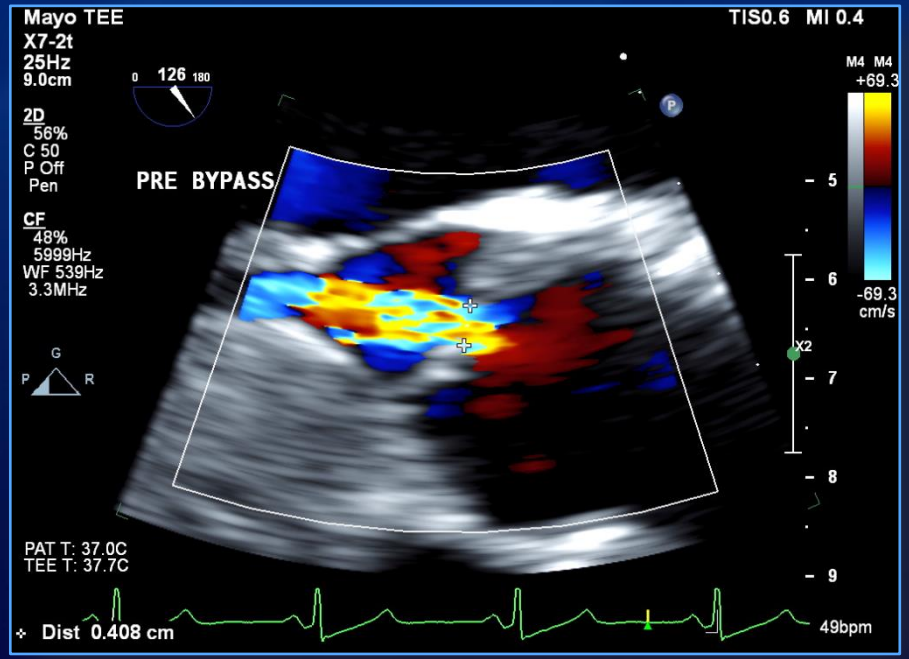

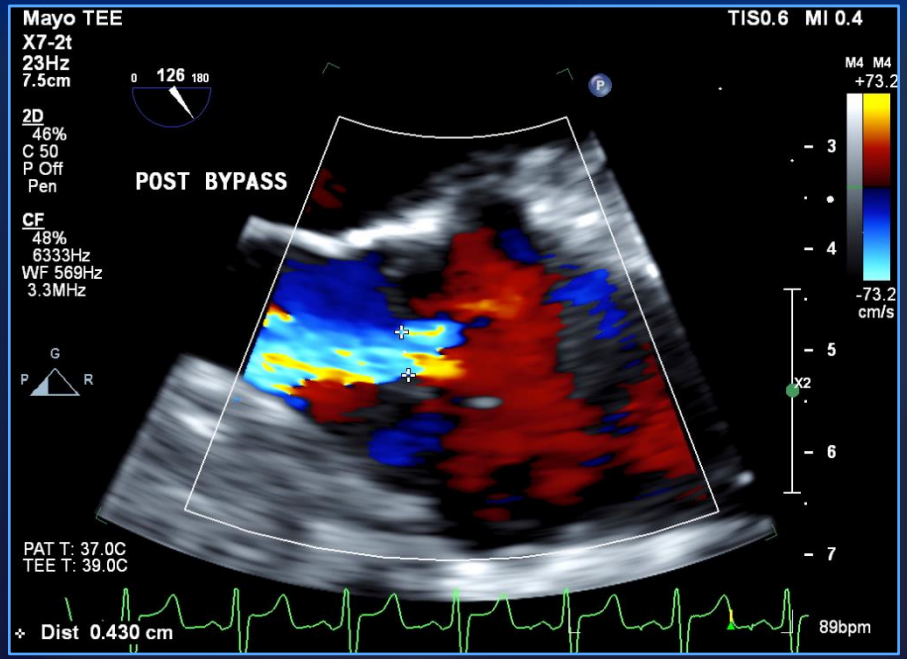

MAYO CLINIC
©2017 MFMER | 3645766-17

Intra-operative Imaging – IOTEE

a. Pre-bypass – Confirm, refine, search

b. Post-bypass – Most important, real-time clinical decision-making

Postbypass/ general-AR

MAYO CLINIC

©2017 MFMER | 3645766-18

Post-bypass goals

IOTEE Post-CPB Goals

- Timely presence of echocardiographer in operating room
- Assist surgeon in de-airing procedures
- Reassess left and right ventricular systolic function
- **Anatomic and hemodynamic evaluation of valvular procedure result under appropriate hemodynamic conditions of heart rate, blood pressure and intra-cardiac volume**
- Effective communication of residual severity of valvular dysfunction, anatomy and mechanism of dysfunction
- Rule out ascending aorta hematoma or dissection

Michelena et al. Prog Cardiovasc Dis 2014;57:74-90

MAYO CLINIC

©2017 MFMER | 3645766-19

AIR…

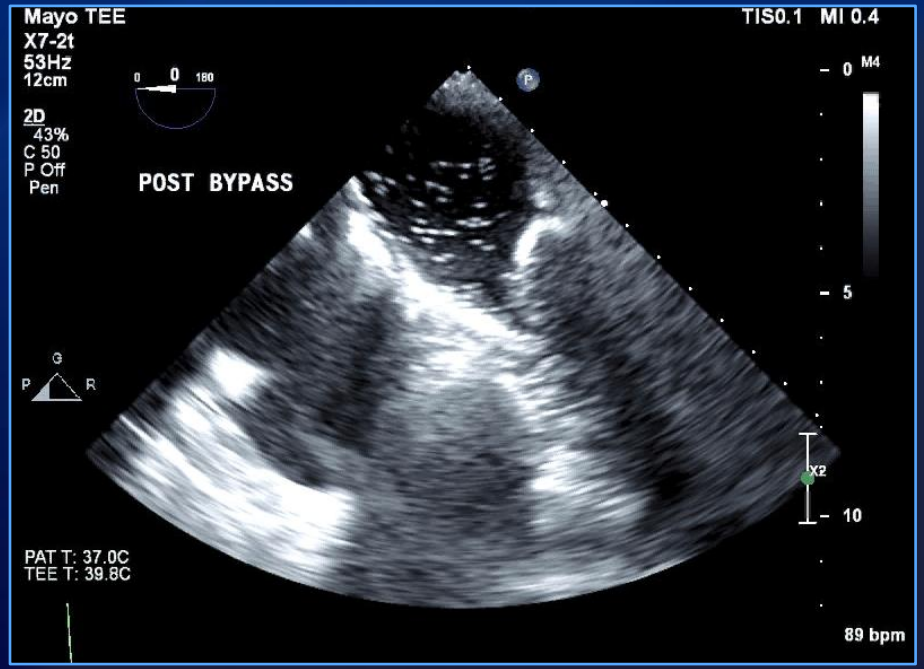

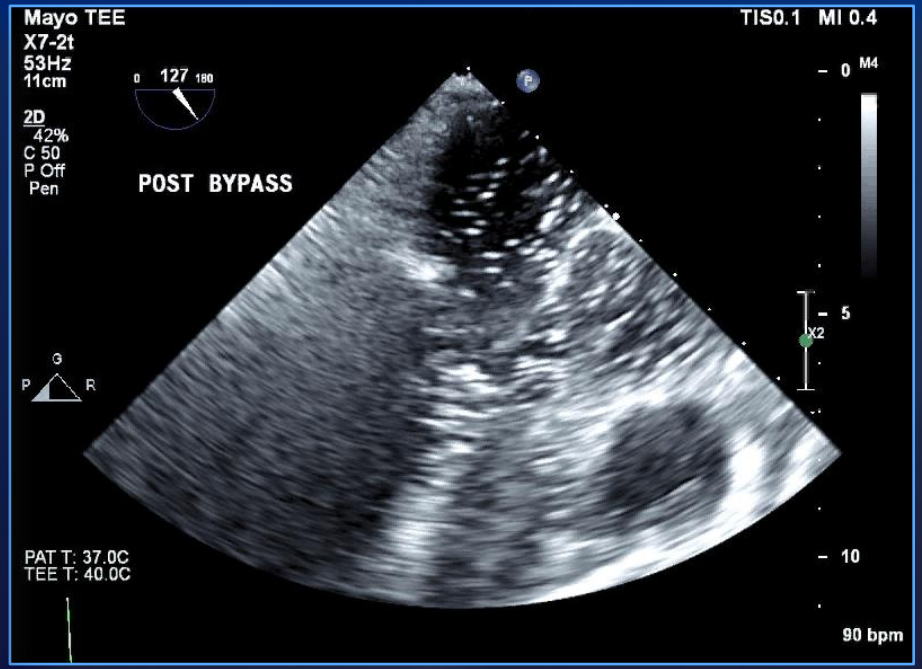

MAYO CLINIC
©2017 MFMER | 3645766-20

De-airing…

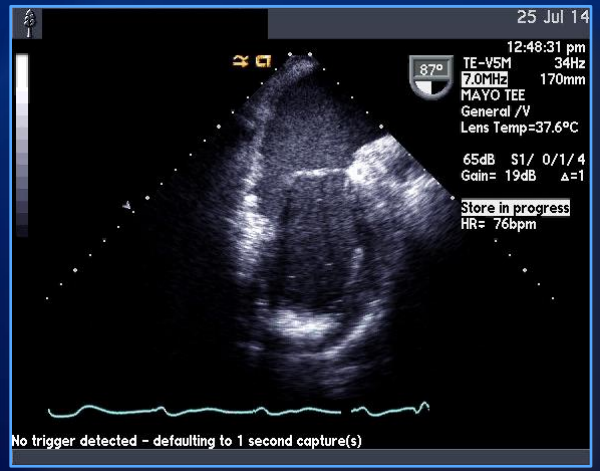

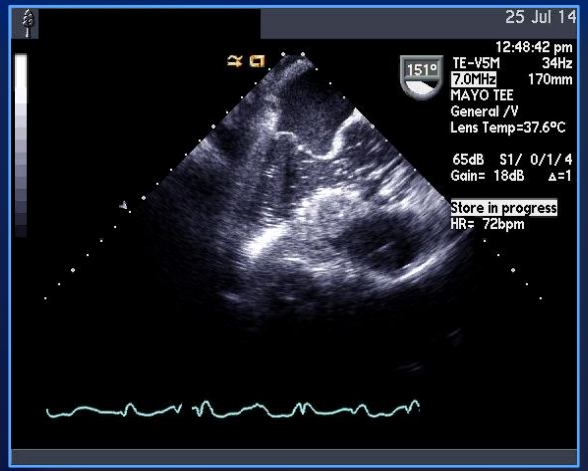

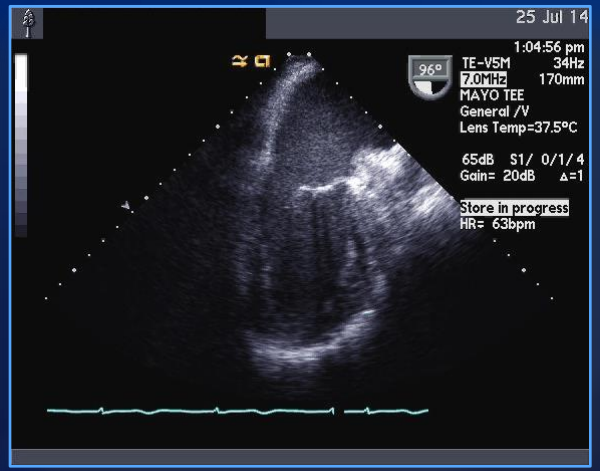

MAYO CLINIC

©2017 MFMER | 3645766-21

De-airing…

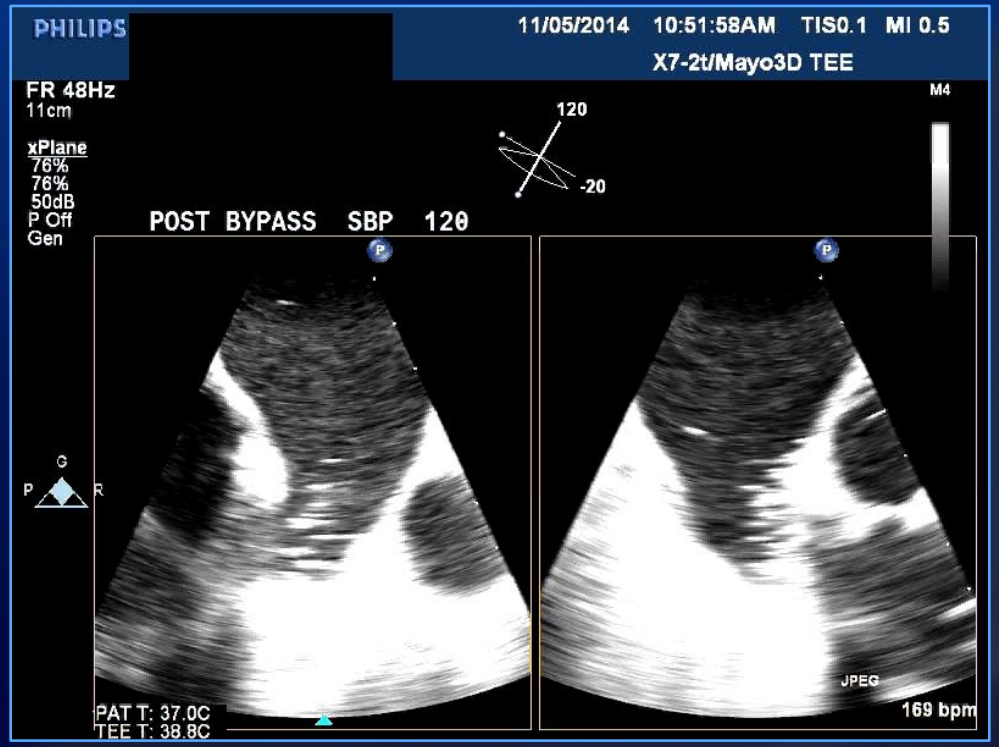

MAYO CLINIC
©2017 MFMER | 3645766-22

De-airing…

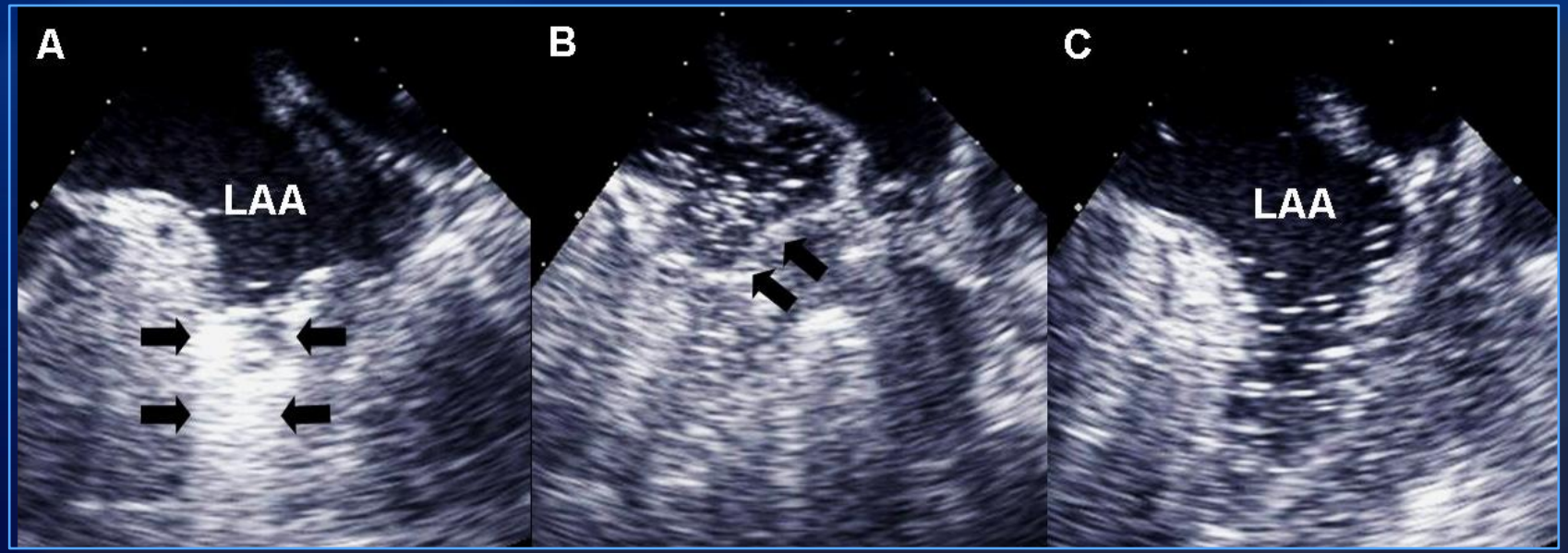

MAYO CLINIC
©2017 MFMER | 3645766-23

Myocardial air…

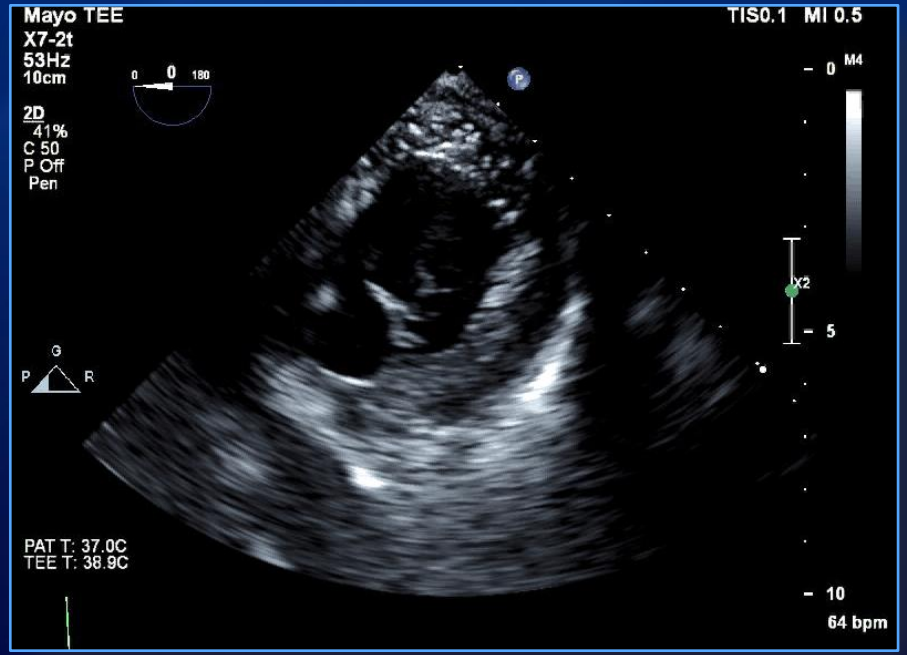

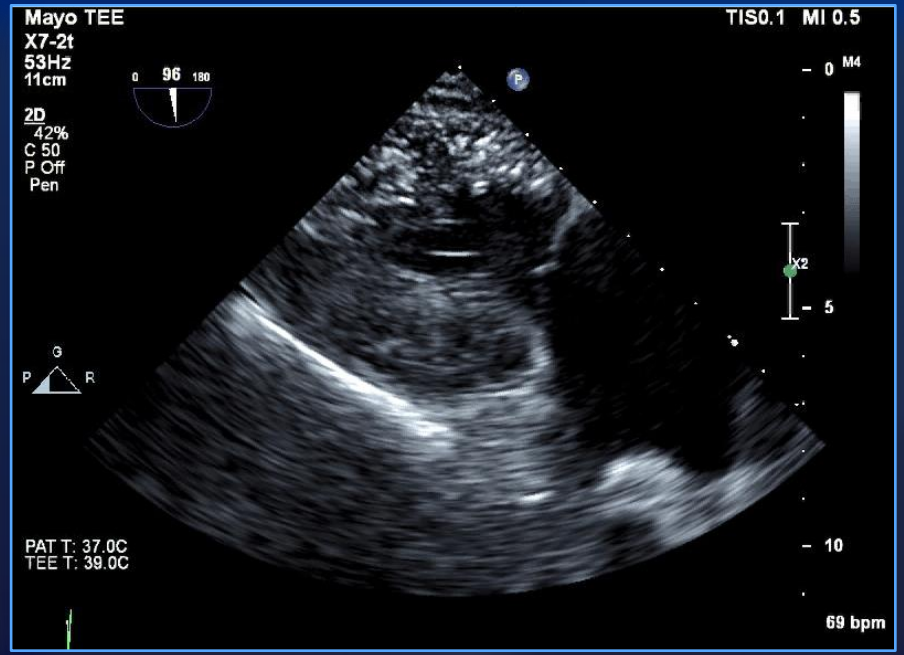

MAYO CLINIC
©2017 MFMER | 3645766-24

Post-bypass Ao dissection…<1%
(100% for this patient)

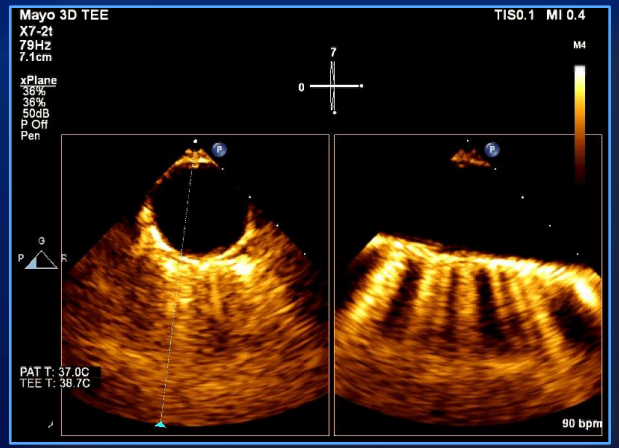

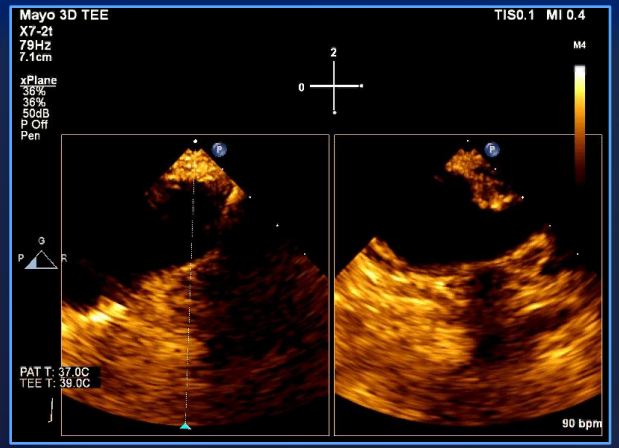

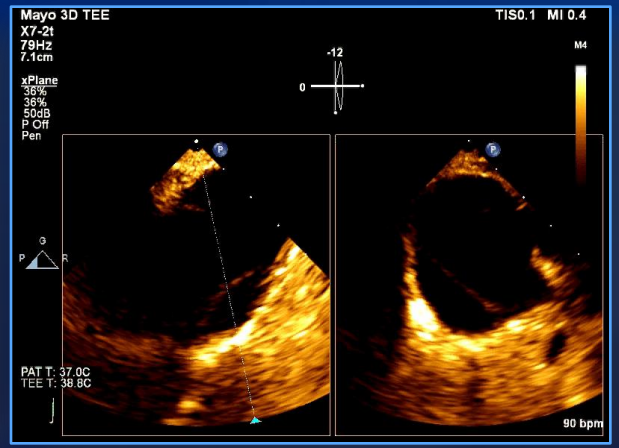

MAYO CLINIC
©2017 MFMER | 3645766-25

Post-bypass Ao dissection…

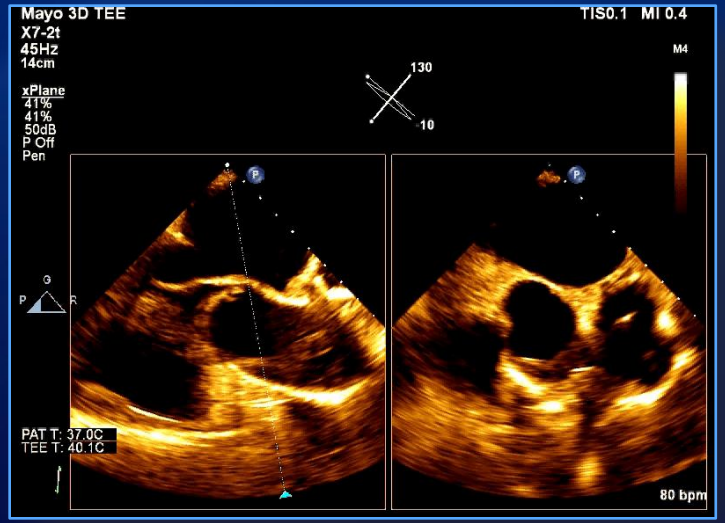

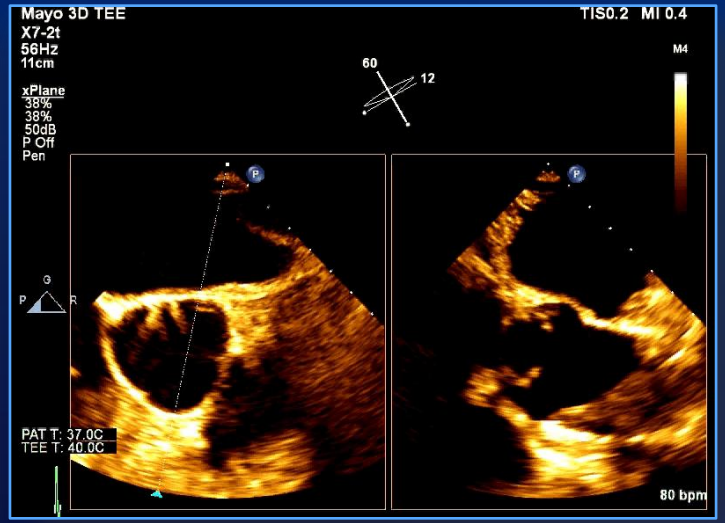

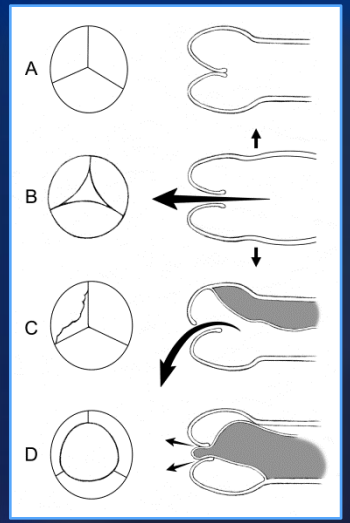

MAYO CLINIC
©2017 MFMER | 3645766-26

Post-bypass Ao dissection…

Color scale!!

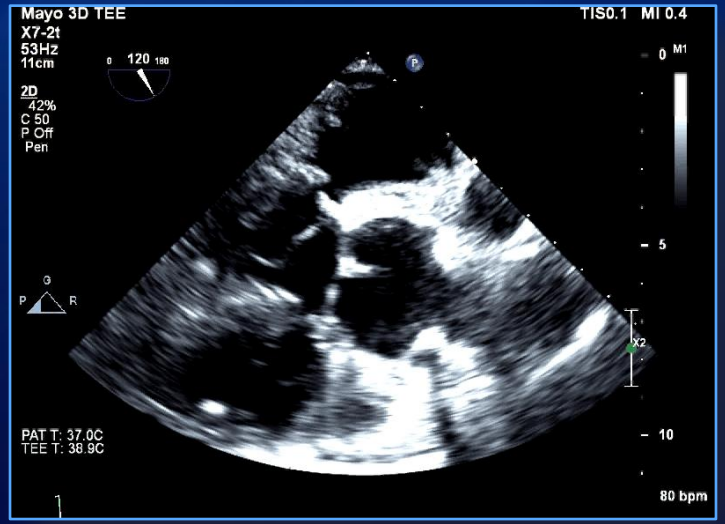

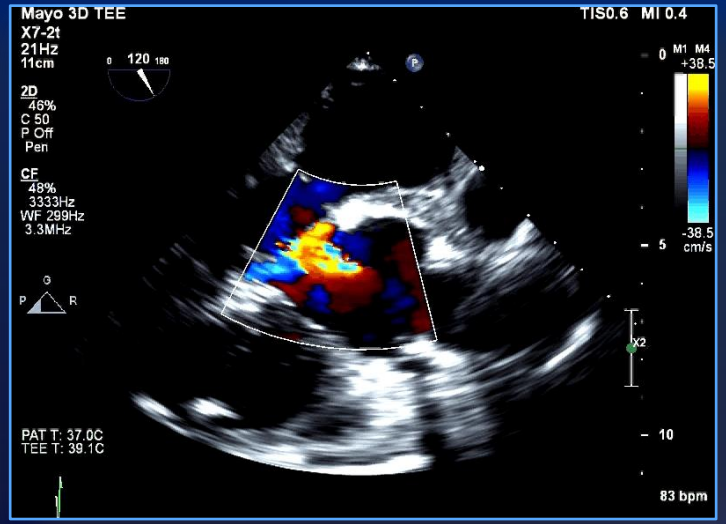

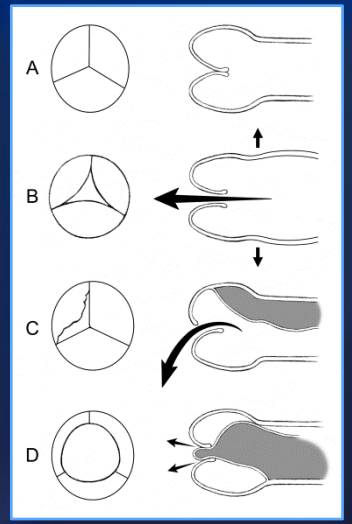

MAYO CLINIC
©2017 MFMER | 3645766-27

Another Dissection AR mechanism…

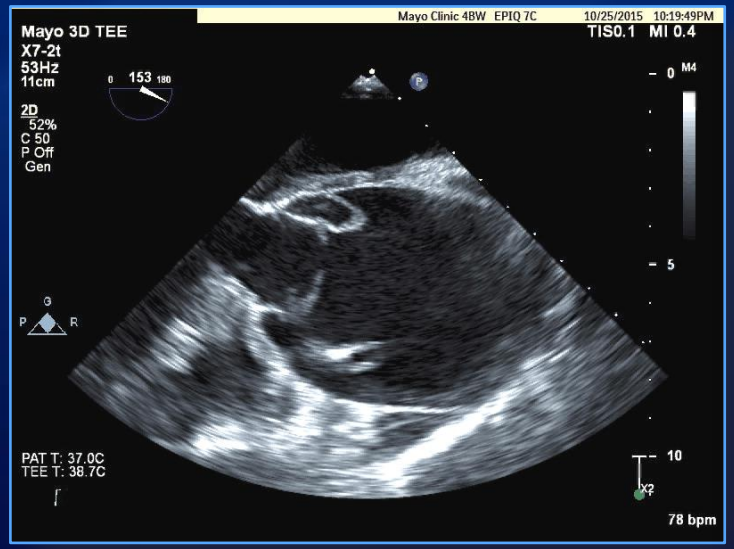

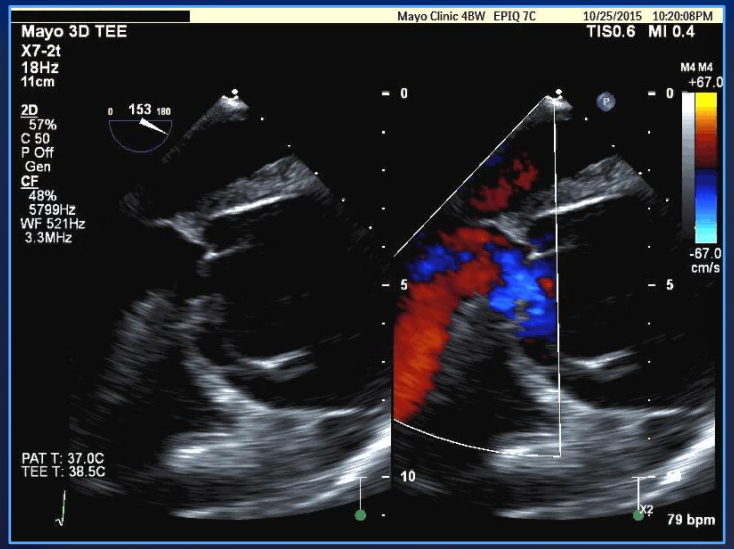

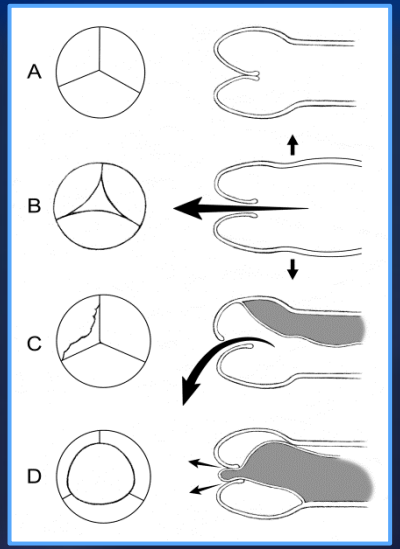

MAYO CLINIC
©2017 MFMER | 3645766-28

Intra-operative Imaging – IOTEE

a. Pre-bypass – Confirm, refine, search

b. Post-bypass – Most important, real-time clinical decision-making

Valvular principles// AR

MAYO CLINIC

©2017 MFMER | 3645766-29

IOTEE Valvular Principles

- IOTEE is not designed to determine the surgical indication, only to confirm it
- Severity of lesions should be determined preop
- Pre-bypass IOTEE refines mechanisms in aortic and mitral regurgitation, especially for repair purposes
- Pre-bypass IOTEE refines anatomy of damage caused by endocarditis
- Post-bypass IOTEE provides anatomic and hemodynamic evaluation of valvular repair or replacement results, under appropriate conditions of heart rate, blood pressure and intra-cardiac volume
- Echocardiologist must develop communication skills

Michelena et al. Prog Cardiovasc Dis 2014;57:74-90

MAYO CLINIC

©2017 MFMER | 3645766-30

High quality echo

- Surgeon perfect understanding of mechanism of dysfunction
- Prevent a second operation down the line…POSTBYPASS

MAYO CLINIC

©2017 MFMER | 3645766-31

Complex case…AS vs HCM vs subAo m

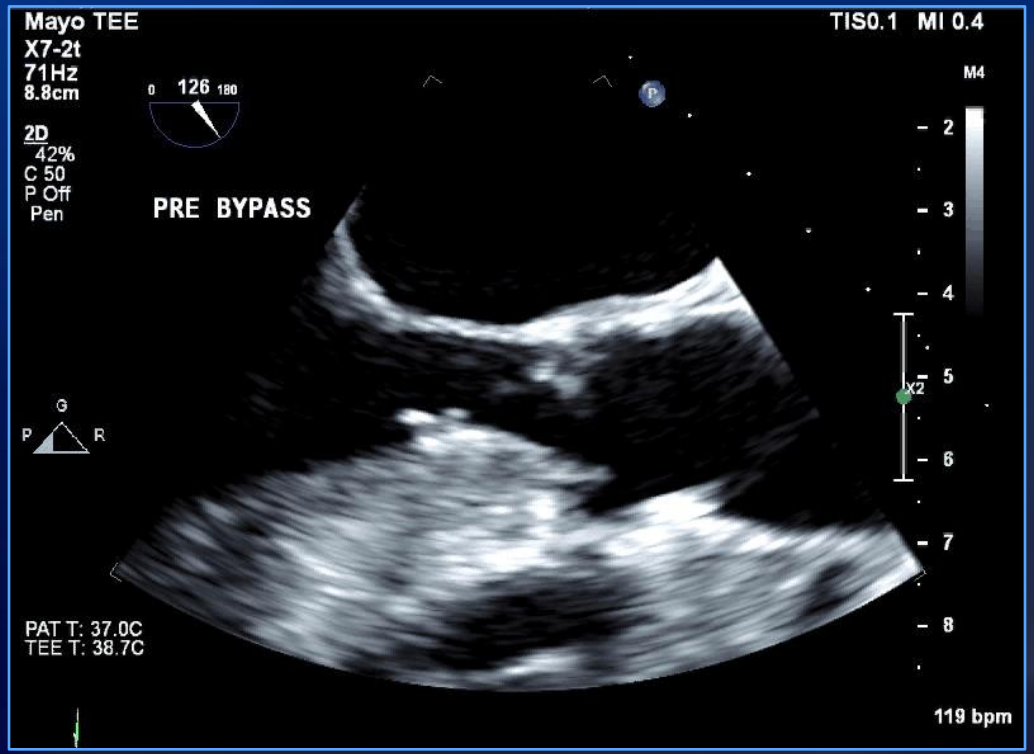

MAYO CLINIC
©2017 MFMER | 3645766-32

Complex case…AS vs HCM vs subAo m

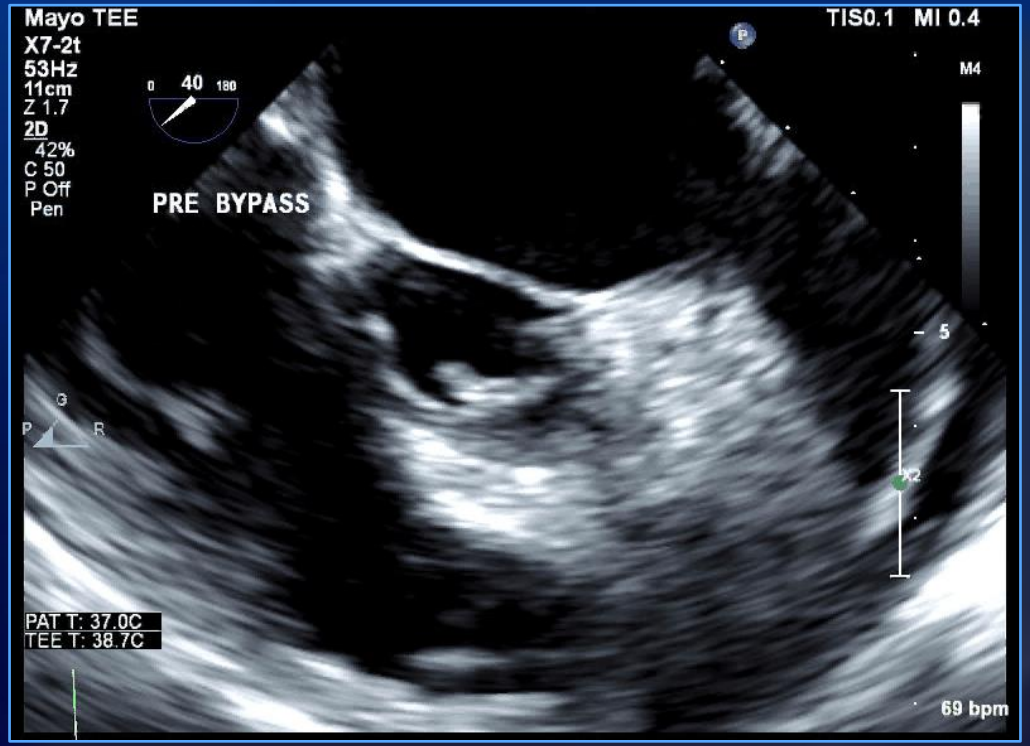

MAYO CLINIC
©2017 MFMER | 3645766-33

Complex case…AS vs HCM vs subAo m

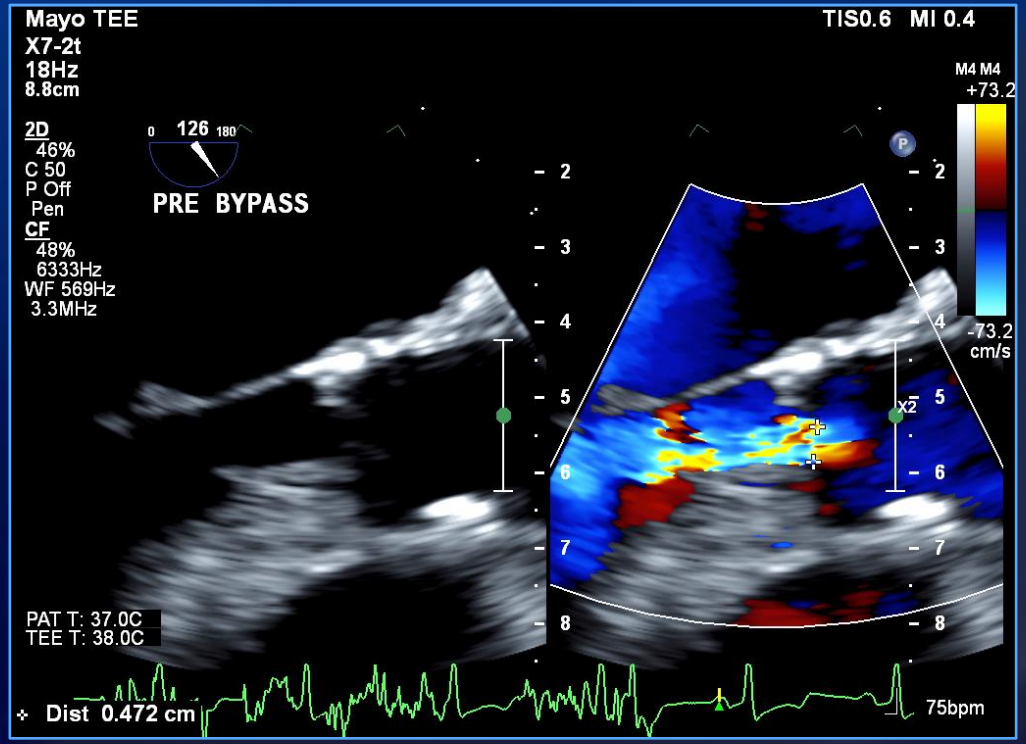

©2017 MFMER | 3645766-34

Complex case…AS vs HCM vs subAo m
LVOT= 1.8 cm…very small

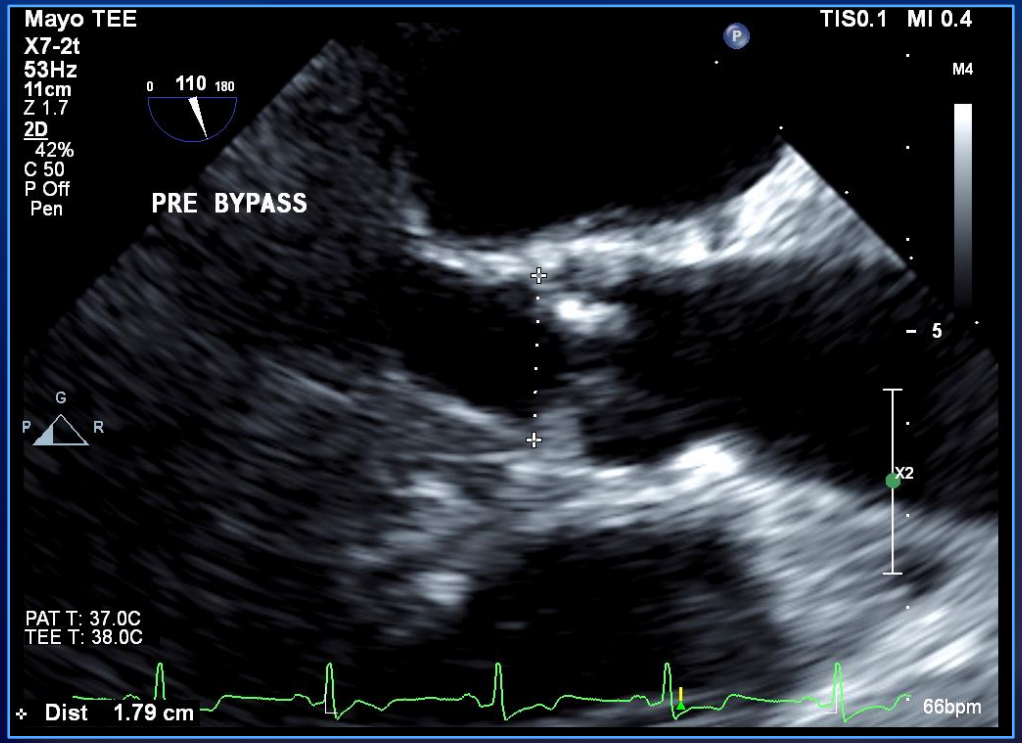

MAYO CLINIC
©2017 MFMER | 3645766-35

Complex case…AS vs HCM vs subAo m
S/P septal myectomy, membrane resection

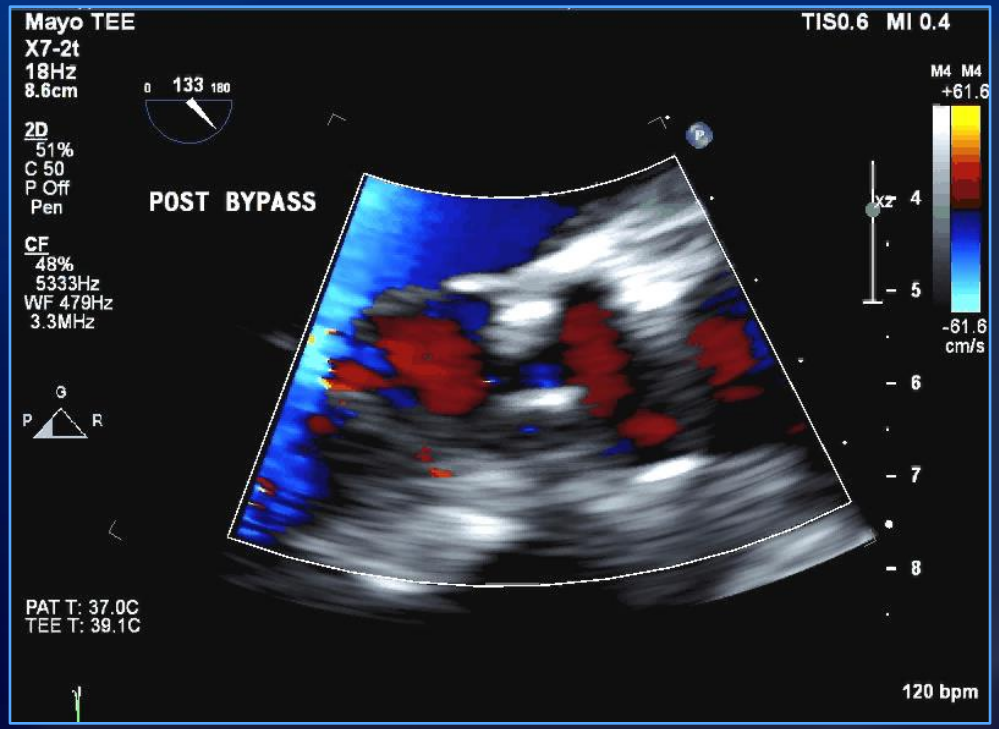

MAYO CLINIC
©2017 MFMER | 3645766-36

Intra-operative Imaging – IOTEE

a. Pre-bypass – Confirm, refine, search

b. Post-bypass – Most important, real-time clinical decision-making

Native Aortic Valve / AR mechanisms

MAYO CLINIC

©2017 MFMER | 3645766-37

Repair-oriented classification of aortic insufficiency: Impact on surgical techniques and clinical outcomes

Munir Boodhwani, MD, MMSc, Laurent de Kerchove, MD, David Glineur, MD, Alain Poncelet, MD, Jean Rubay, MD, Parla Astarci, MD, Robert Verhelst, MD, Philippe Noirhomme, MD, and Gébrine El Khoury, MD

The Journal of Thoracic and Cardiovascular Surgery • Volume 137, Number 2

AI Class	Type I Normal cusp motion with FAA dilatation or cusp perforation				Type II Cusp Prolapse	Type III Cusp Restriction
	Ia	Ib	Ic	Id		
Mechanism		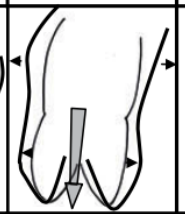	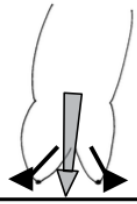			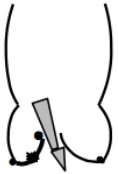
Repair Techniques (Primary)	STJ remodeling *Ascending aortic graft*	Aortic Valve sparing: *Reimplantation or Remodeling with SCA*	SCA	Patch Repair *Autologous or bovine pericardium*	Prolapse Repair *Plication* *Triangular resection* *Free margin* *Resuspension* *Patch*	Leaflet Repair *Shaving* *Decalcificatio* *Patch*

MAYO CLINIC

©2017 MFMER | 3645766-38

Type 1

AI Class	Type I Normal cusp motion with FAA dilatation or cusp perforation				Type II Cusp Prolapse	Type III Cusp Restriction
	Ia	Ib	Ic	Id		
Mechanism		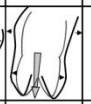				
Repair Techniques (Primary)	STJ remodeling *Ascending aortic graft*	Aortic Valve sparing: *Reimplantation or Remodeling with SCA*	SCA	Patch Repair *Autologous or bovine pericardium*	Prolapse Repair *Plication* *Triangular resection* *Free margin* *Resuspension* *Patch*	Leaflet Repair *Shaving* *Decalcificatio* *Patch*

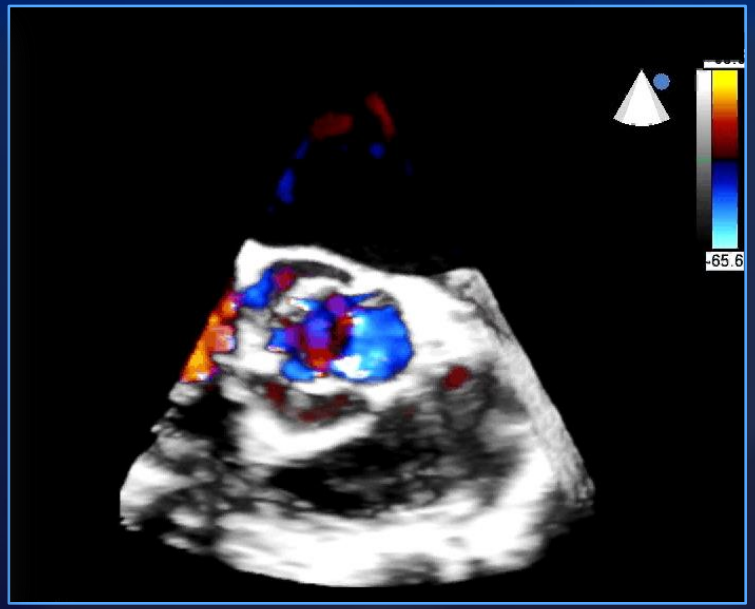

MAYO CLINIC
©2017 MFMER | 3645766-39

Type 1

AI Class	Type I Normal cusp motion with FAA dilatation or cusp perforation				Type II Cusp Prolapse	Type III Cusp Restriction
	Ia	Ib	Ic	Id		
Mechanism						
Repair Techniques (Primary)	STJ remodeling *Ascending aortic graft*	Aortic Valve sparing: *Reimplantation or Remodeling with SCA*	SCA	Patch Repair *Autologous or bovine pericardium*	Prolapse Repair *Plication* *Triangular resection* *Free margin Resuspension* *Patch*	Leaflet Repair *Shaving* *Decalcificatio* *Patch*

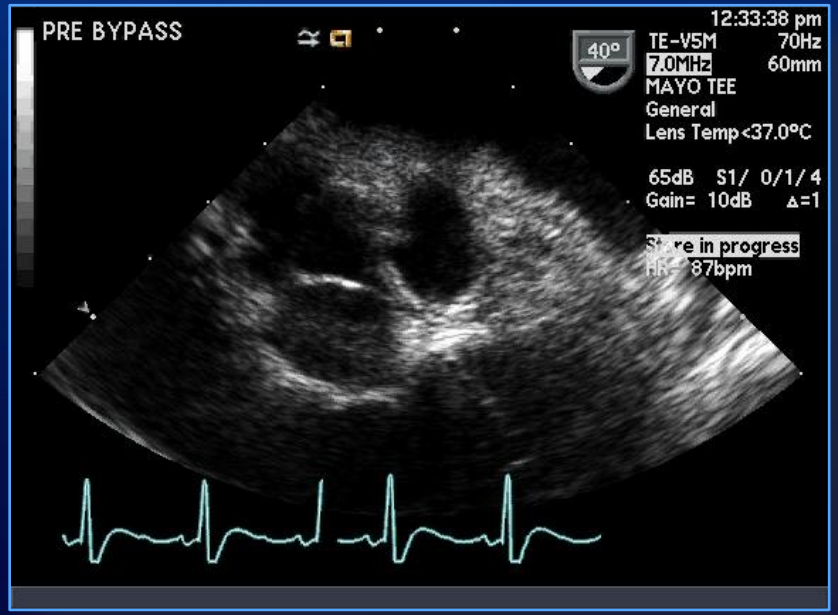

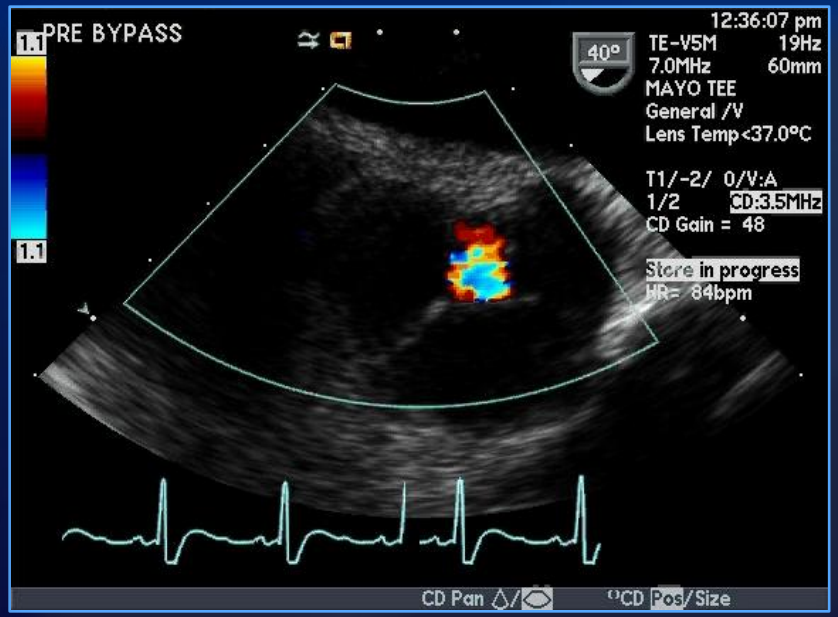

MAYO CLINIC
©2017 MFMER | 3645766-40

Type 2

AI Class	Type I Normal cusp motion with FAA dilatation or cusp perforation				Type II Cusp Prolapse	Type III Cusp Restriction
	Ia	Ib	Ic	Id		
Mechanism						
Repair Techniques (Primary)	STJ remodeling *Ascending aortic graft*	Aortic Valve sparing: *Reimplantation or Remodeling with SCA*	SCA	Patch Repair *Autologous or bovine pericardium*	Prolapse Repair *Plication* *Triangular resection* *Free margin Resuspension* *Patch*	Leaflet Repair *Shaving* *Decalcificatio* *Patch*

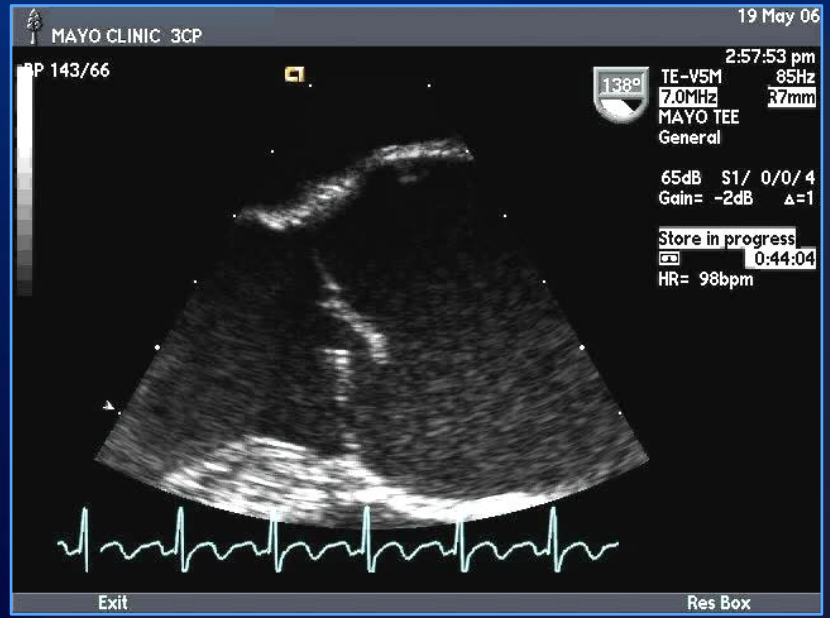

©2017 MFMER | 3645766-41

Type 3

AI Class	Type I Normal cusp motion with FAA dilatation or cusp perforation				Type II Cusp Prolapse	Type III Cusp Restriction
	Ia	Ib	Ic	Id		
Mechanism		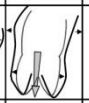				
Repair Techniques (Primary)	STJ remodeling *Ascending aortic graft*	Aortic Valve sparing: *Reimplantation or Remodeling with SCA*	SCA	Patch Repair *Autologous or bovine pericardium*	Prolapse Repair *Plication* *Triangular resection* *Free margin* *Resuspension* *Patch*	Leaflet Repair *Shaving* *Decalcificatio* *Patch*

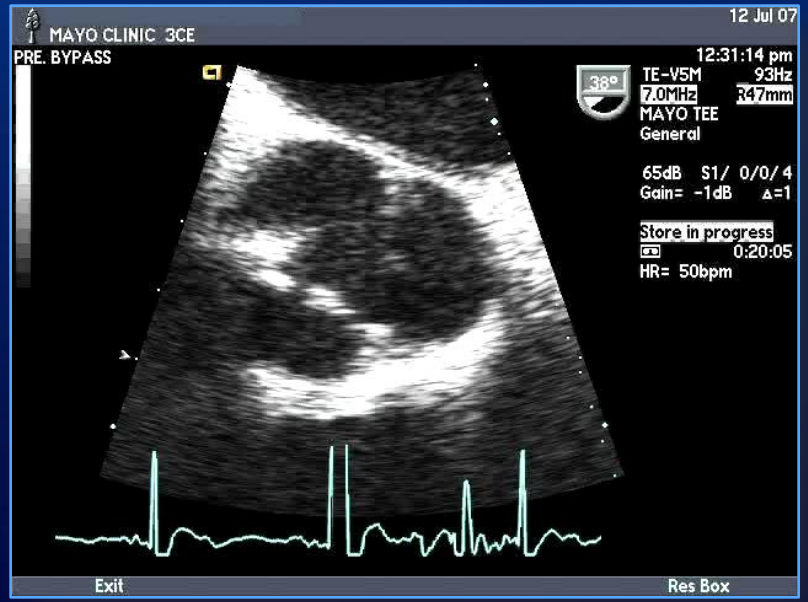

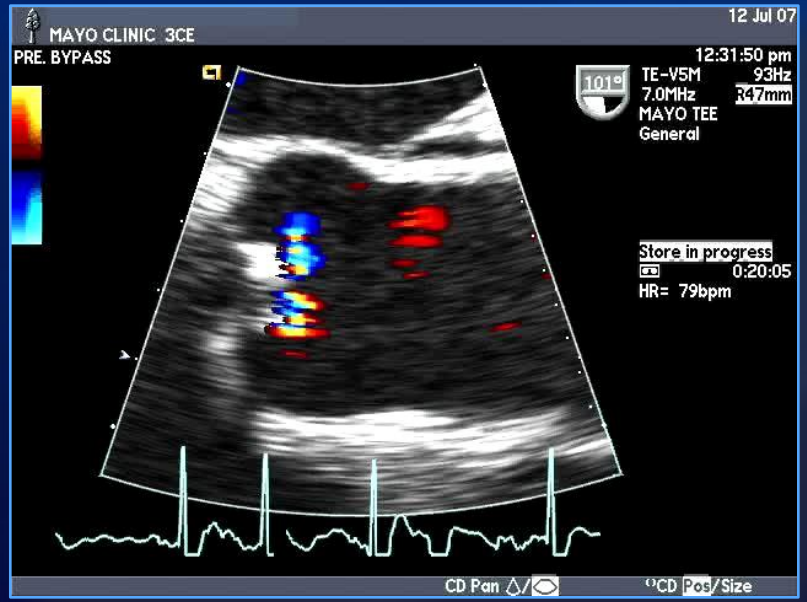

©2017 MFMER | 3645766-42

Post-inflammatory aortic stenosis

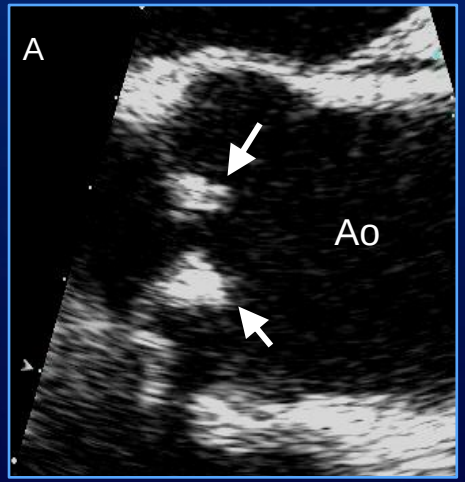

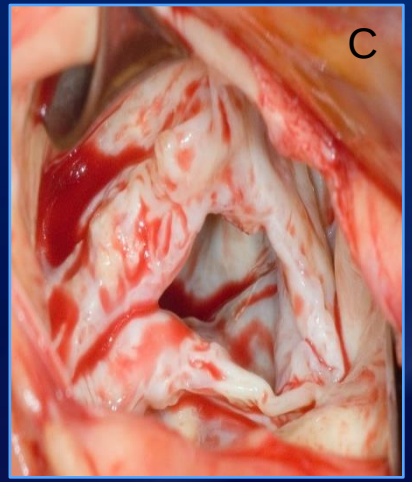

MAYO CLINIC
©2017 MFMER | 3645766-43

Intra-operative Imaging – IOTEE

a. Pre-bypass – Confirm, refine, search

b. Post-bypass – Most important, real-time clinical decision-making

Native Aortic Valve / BAV-AR

MAYO CLINIC

©2017 MFMER | 3645766-44

Young man // preop TTE

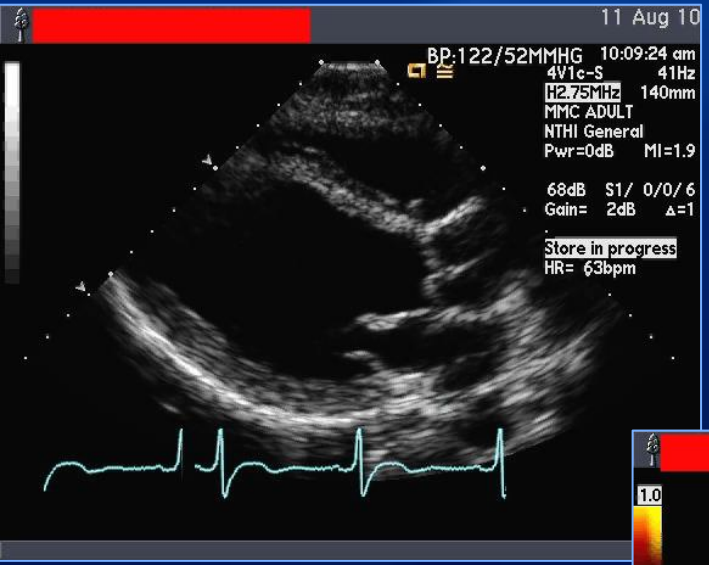

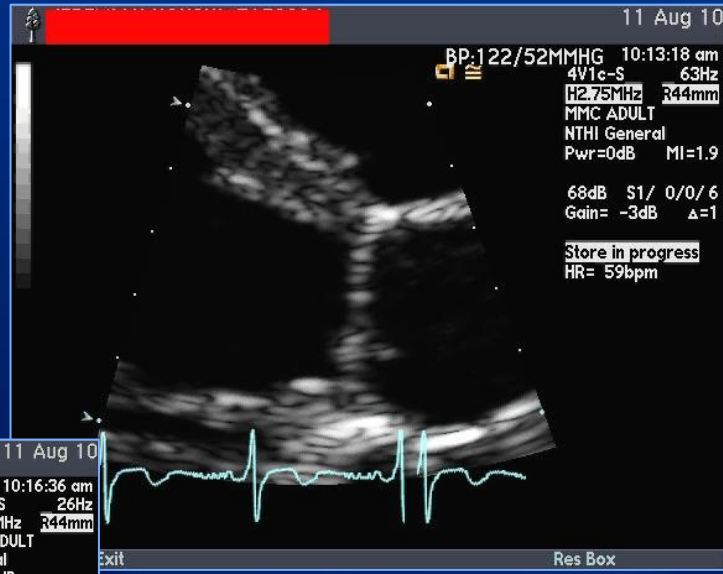

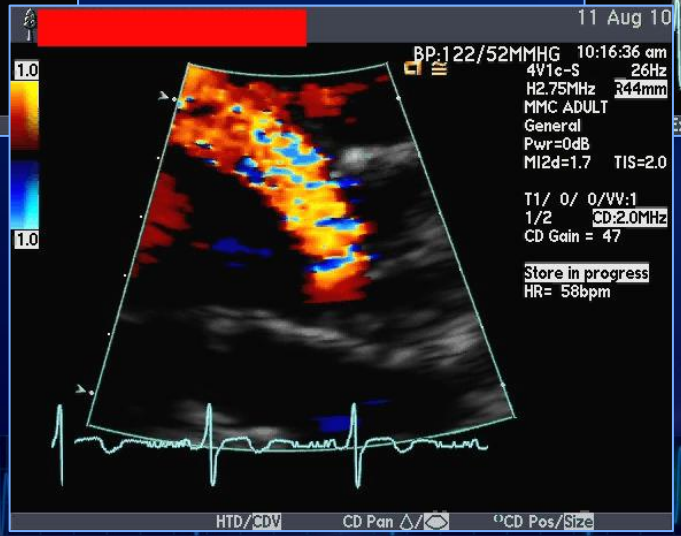

MAYO CLINIC
©2017 MFMER | 3645766-45

Prebypass IOTEE

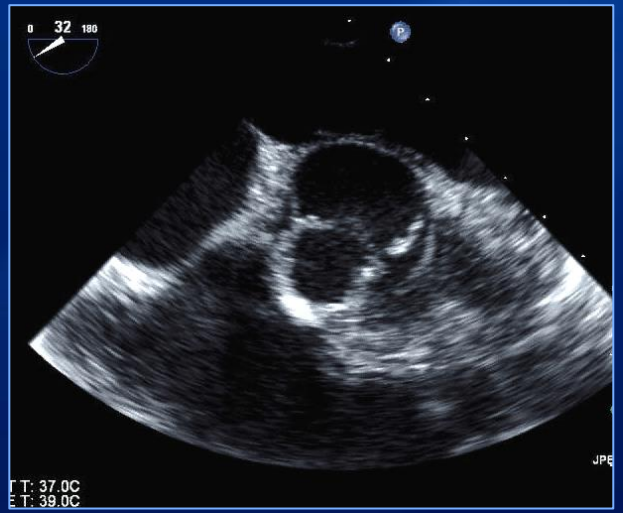

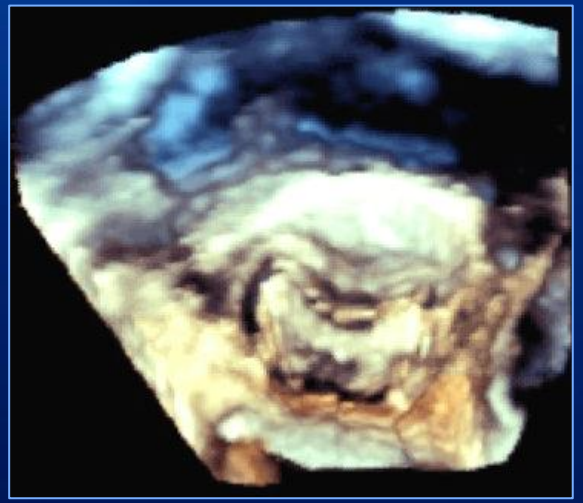

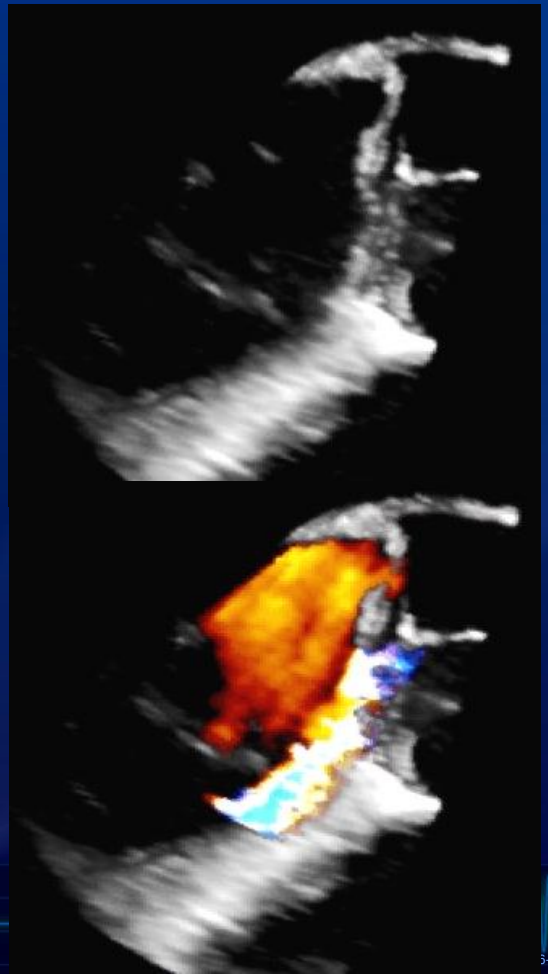

Post-bypass

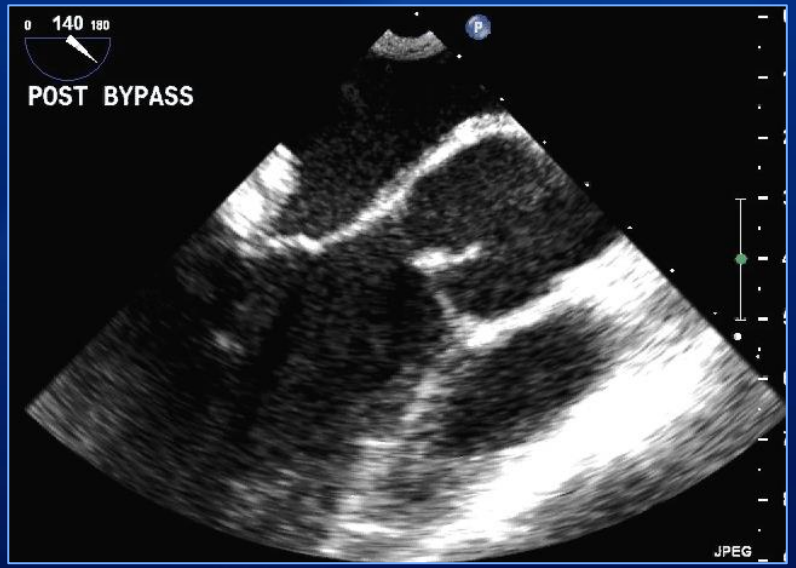

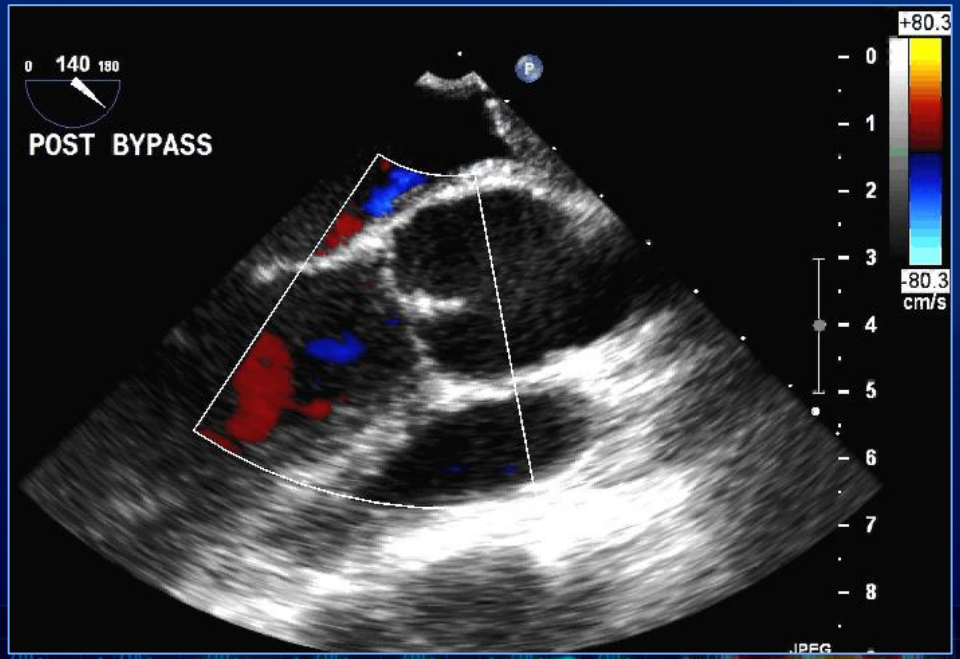

MAYO CLINIC
©2017 MFMER | 3645766-47

A few months later…

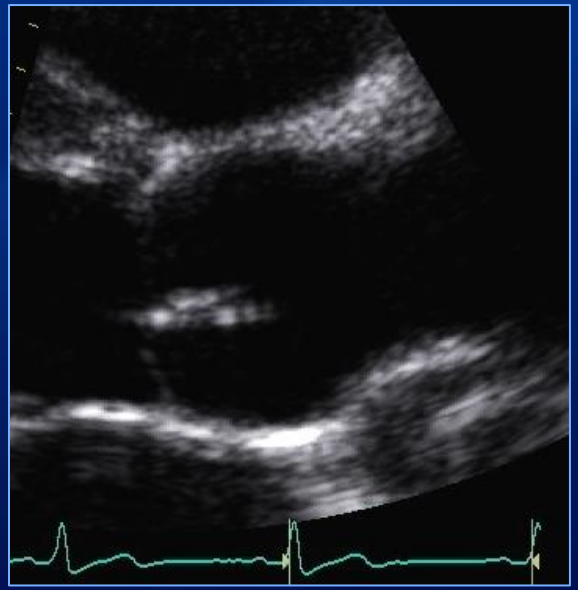

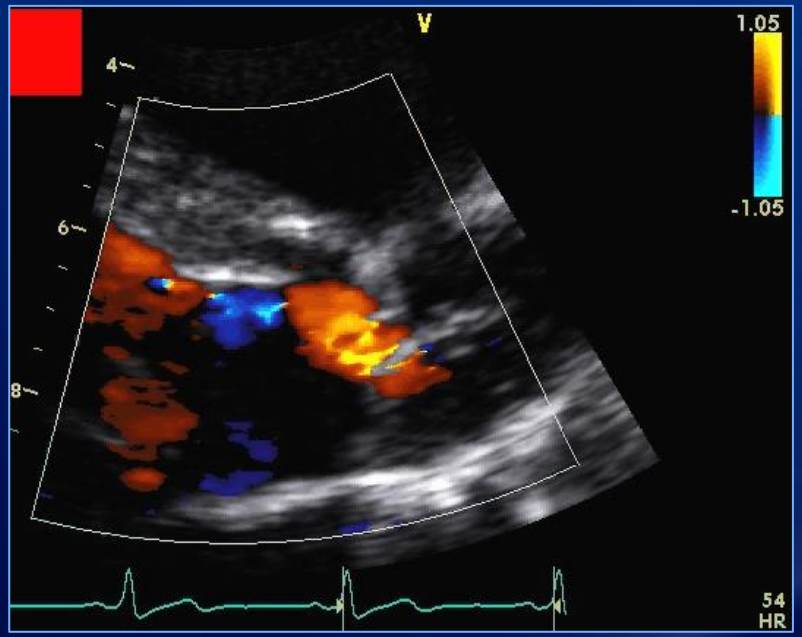

MAYO CLINIC
©2017 MFMER | 3645766-48

BAV repair

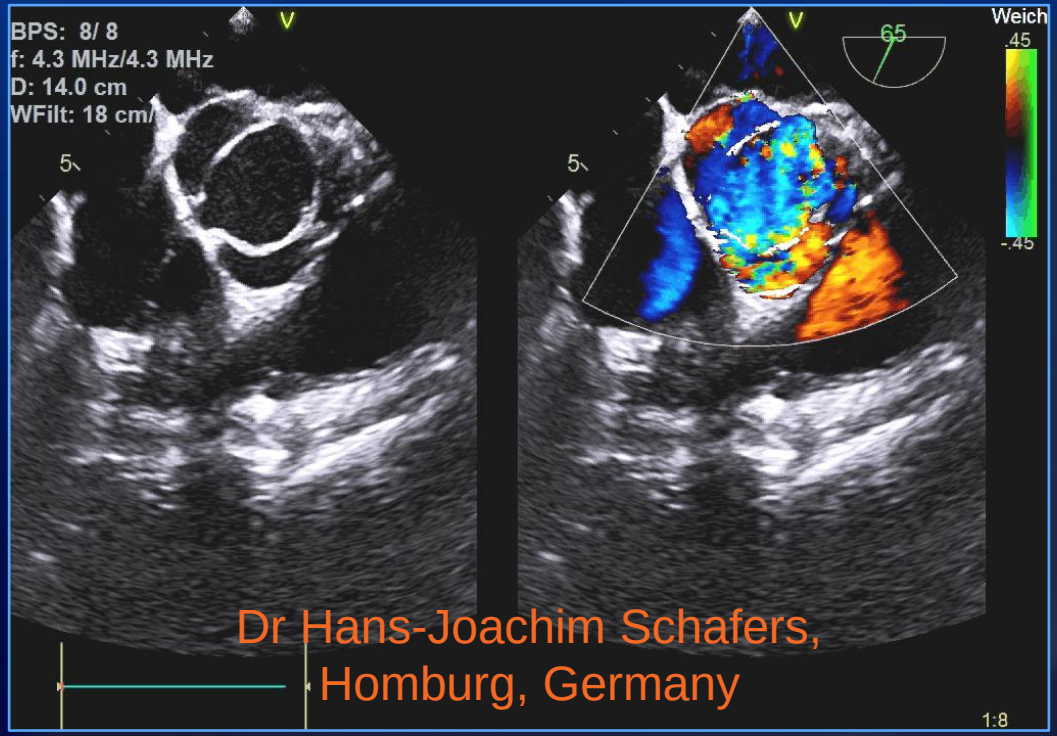

Dr Hans-Joachim Schafers,
Homburg, Germany

MAYO CLINIC
©2017 MFMER | 3645766-49

BAV repair

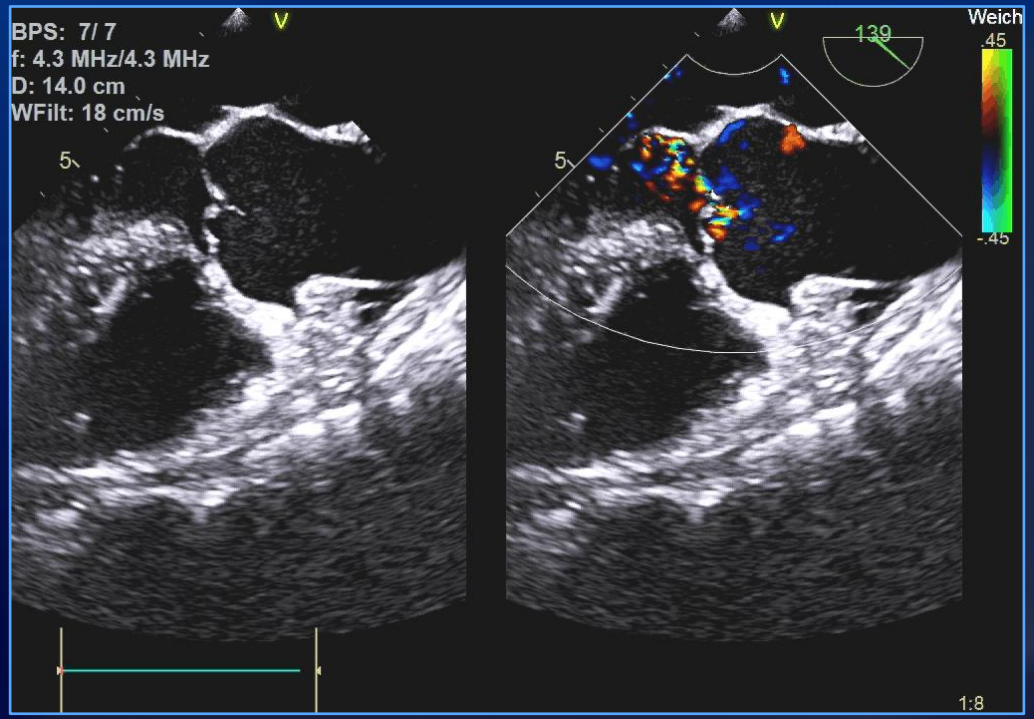

MAYO CLINIC
©2017 MFMER | 3645766-50

BAV repair

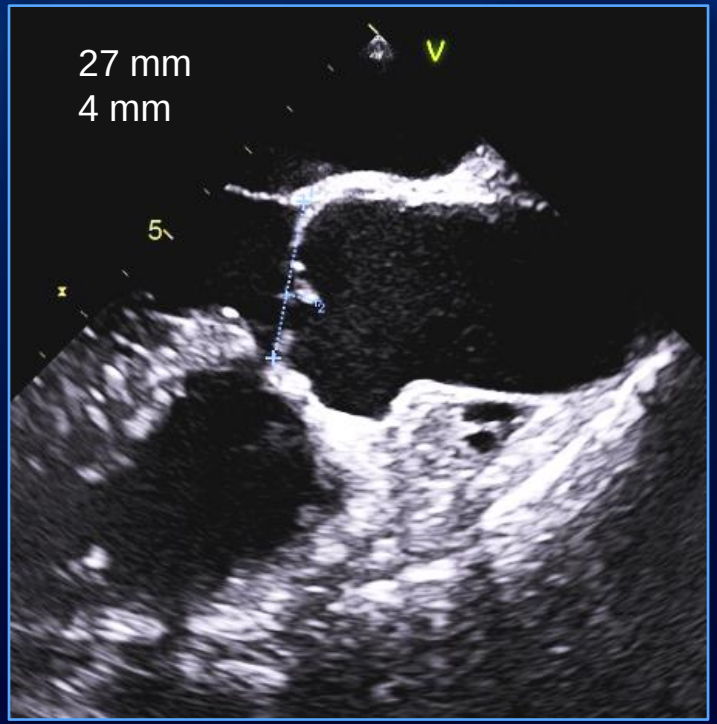

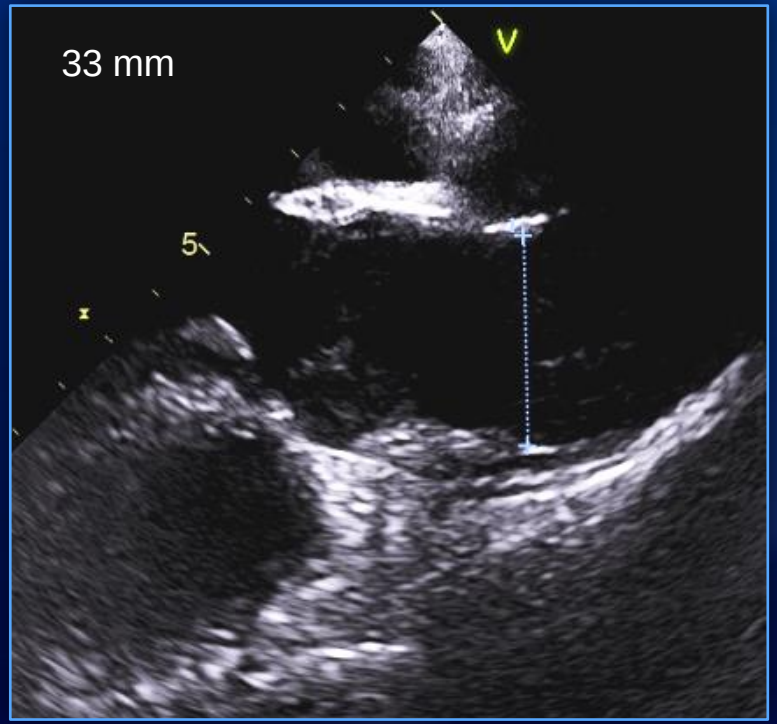

MAYO CLINIC
©2017 MFMER | 3645766-51

Valve Configuration Determines Long-Term Results After Repair of the Bicuspid Aortic Valve

Diana Aicher, MD; Takashi Kunihara, MD; Omar Abou Issa, MD; Brigitte Brittner, MD; Stefan Gräber, MD; Hans-Joachim Schäfers, MD

Circulation. 2011;123:178-185

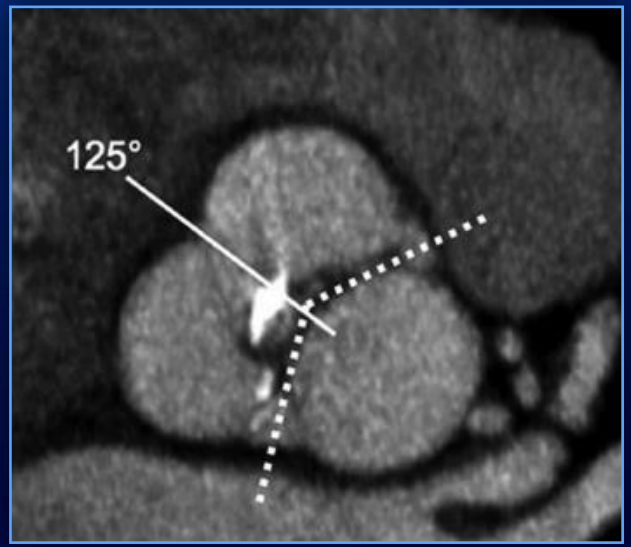

	HR	95% CI	P
Age	0.955	0.928-0.982	0.001
eH	0.740	0.612-0.894	0.002
AVD/	1.302	1.076-1.575	0.007
Commissural orientation	0.961	0.938-0.985	0.002
Peridacarial patch	5.175	2.100-12.753	0.000

MAYO CLINIC

©2017 MFMER | 3645766-52

Suture Annuloplasty Significantly Improves the Durability of Bicuspid Aortic Valve Repair

Ulrich Schneider, MD, Christopher Hofmann, Diana Aicher, MD,
Hiroaki Takahashi, MD, Yujiro Miura, MD, and Hans-Joachim Schäfers, MD

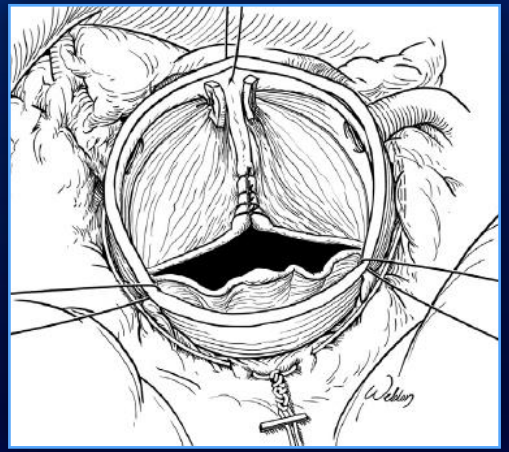

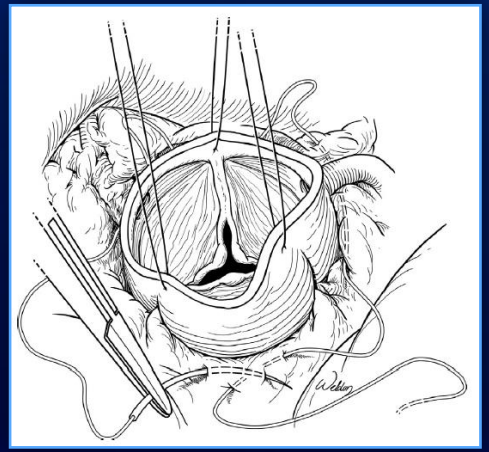

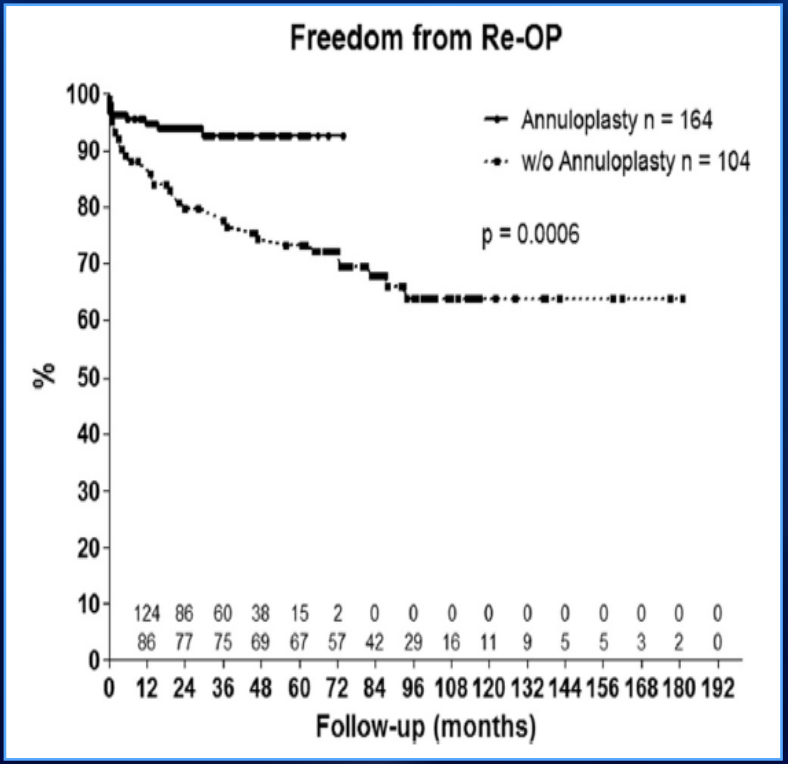

MAYO CLINIC
©2017 MFMER | 3645766-53

Natural History of Asymptomatic Patients With Normally Functioning or Minimally Dysfunctional Bicuspid Aortic Valve in the Community

Hector I. Michelena, MD; Valerie A. Desjardins, MD; Jean-François Avierinos, MD; Antonio Russo, MD; Vuyisile T. Nkomo, MD; Thoralf M. Sundt, MD; Patricia A. Pellikka, MD; A. Jamil Tajik, MD; Maurice Enriquez-Sarano, MD

Circulation. 2008;117:2776-2784

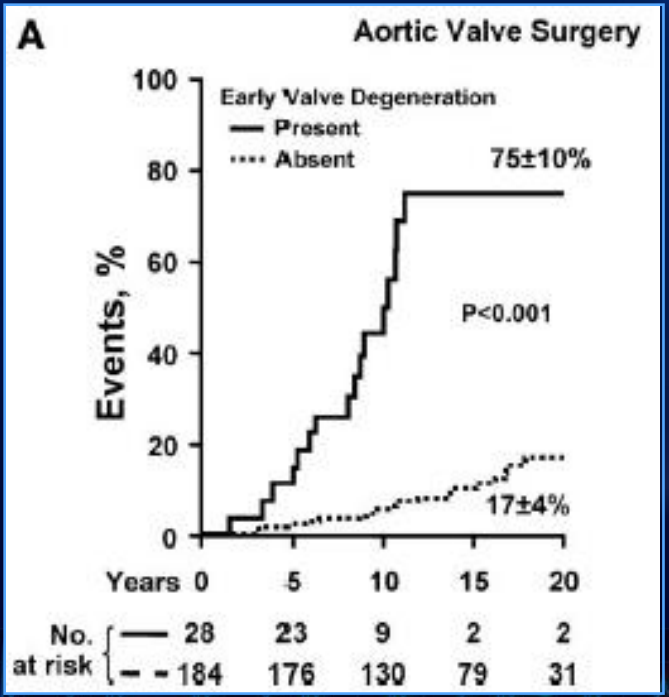

MAYO CLINIC

©2017 MFMER | 3645766-54

Our patient…valve not calcified Good mobility Prolapse mechanism Non-dilated root

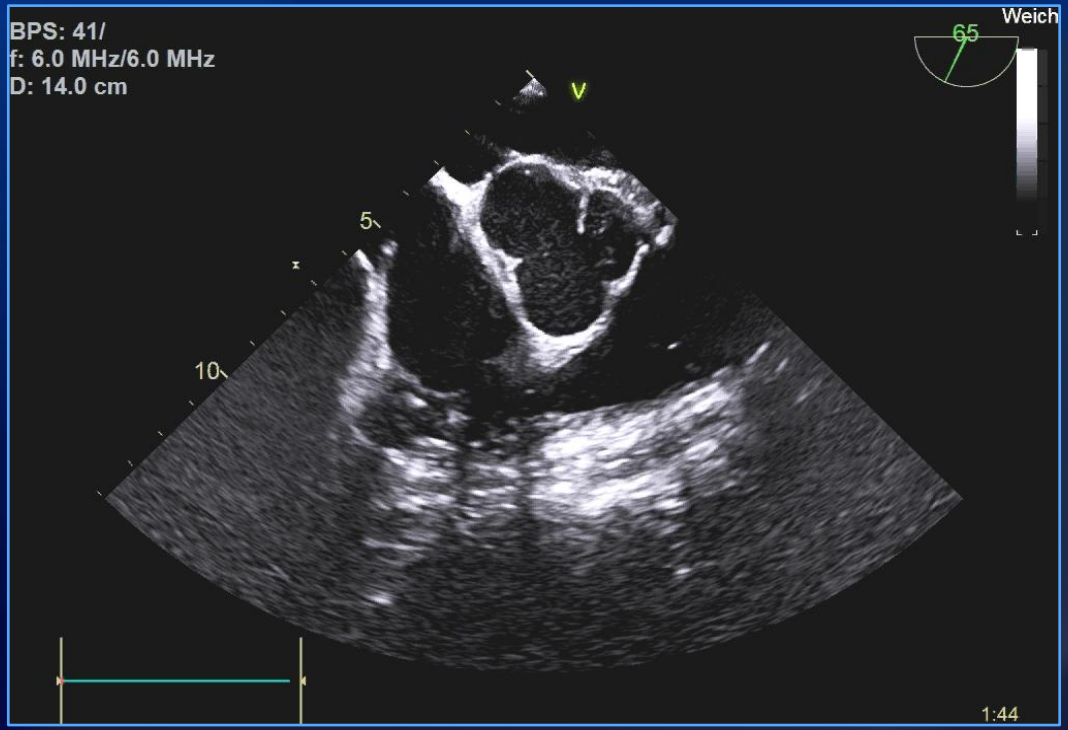

MAYO CLINIC
©2017 MFMER | 3645766-55

Our patient…

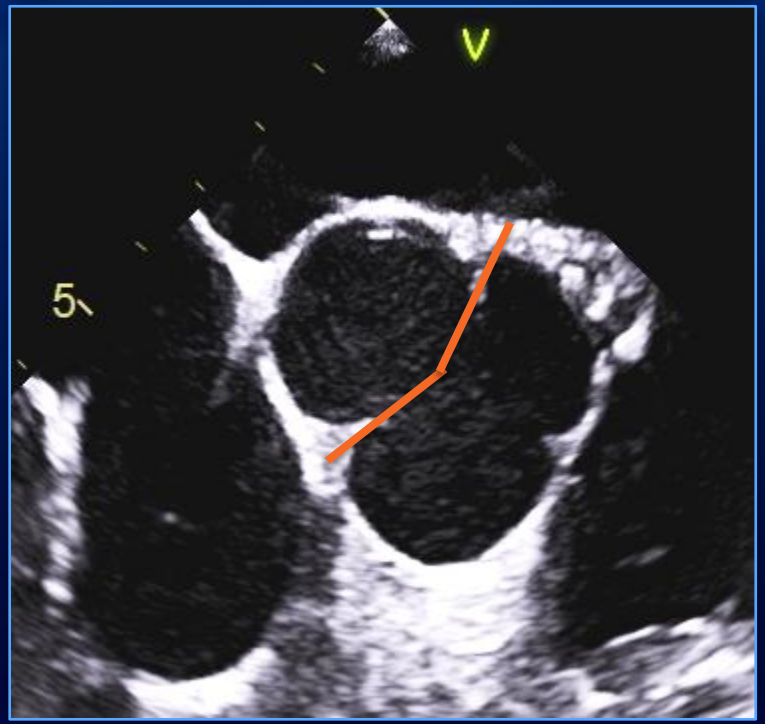

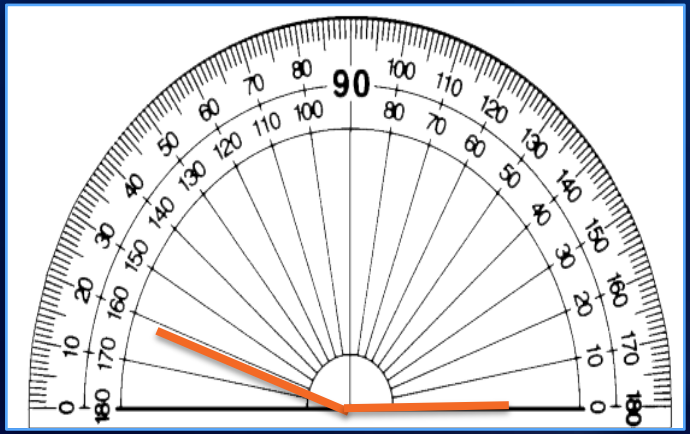

MAYO CLINIC
©2017 MFMER | 3645766-56

BAV repair// postbypass

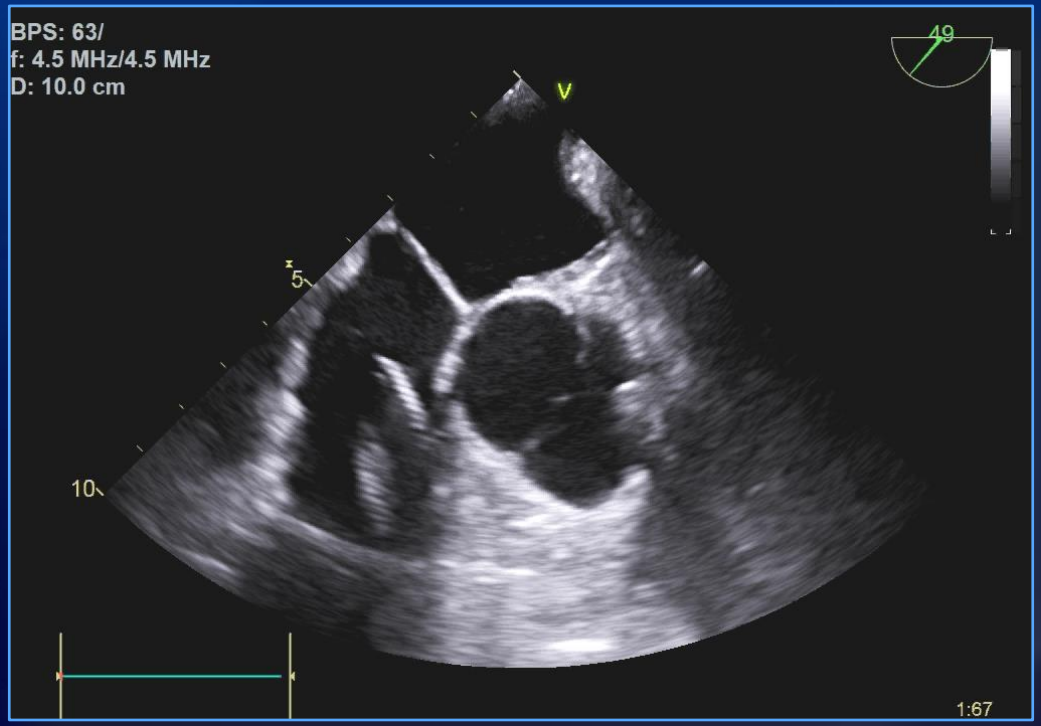

MAYO CLINIC
©2017 MFMER | 3645766-57

BAV repair// Postbypass

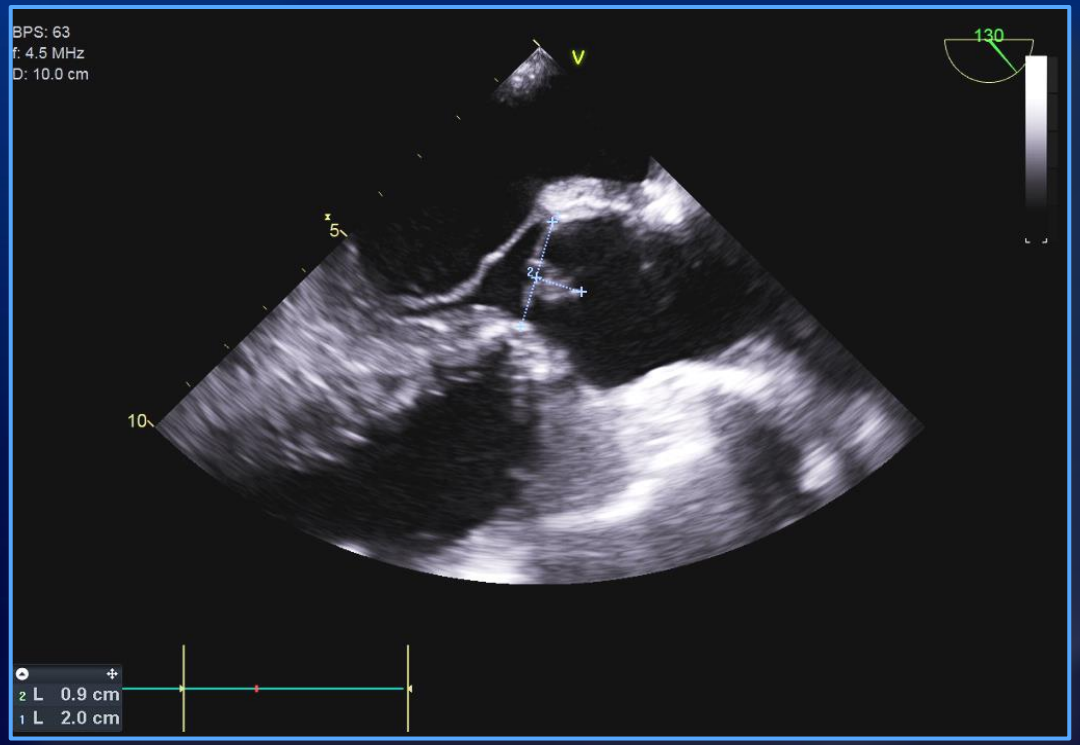

MAYO CLINIC
©2017 MFMER | 3645766-58

BAV repair // Physiologic DBP!!

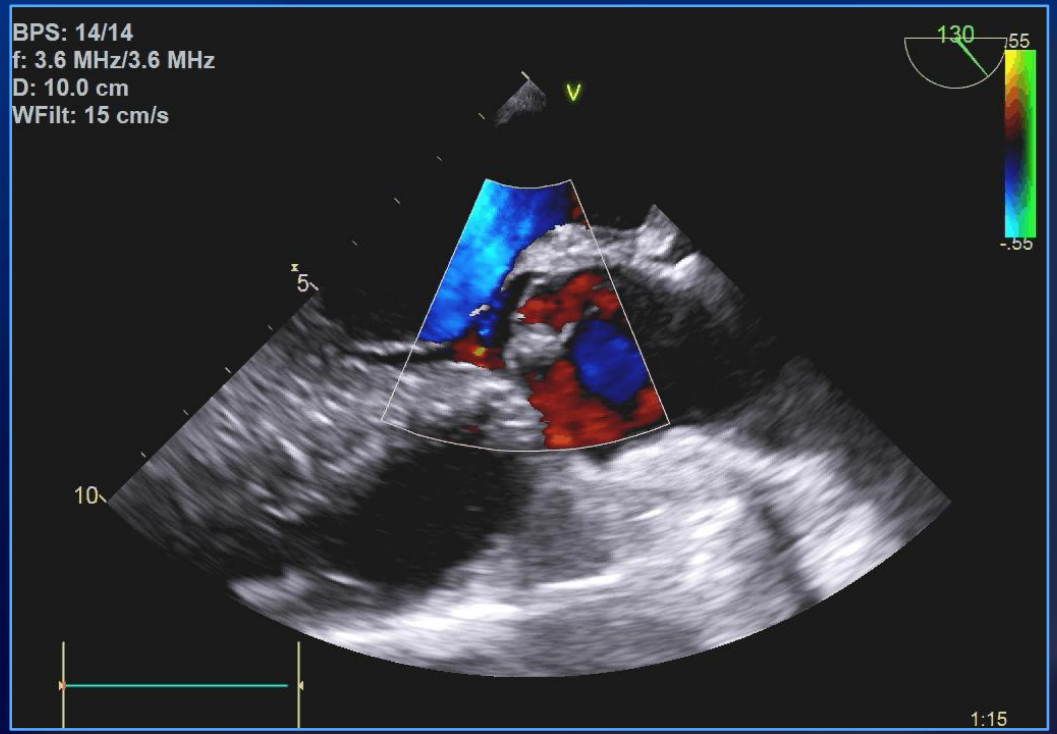

MAYO CLINIC
©2017 MFMER | 3645766-59

Intra-operative Imaging – IOTEE

a. Pre-bypass – Confirm, refine, search

b. Post-bypass – Most important, real-time clinical decision-making

Native Aortic Valve / AR unpredictable

MAYO CLINIC

©2017 MFMER | 3645766-60

More common than not…”poor” tissue / fenestrations

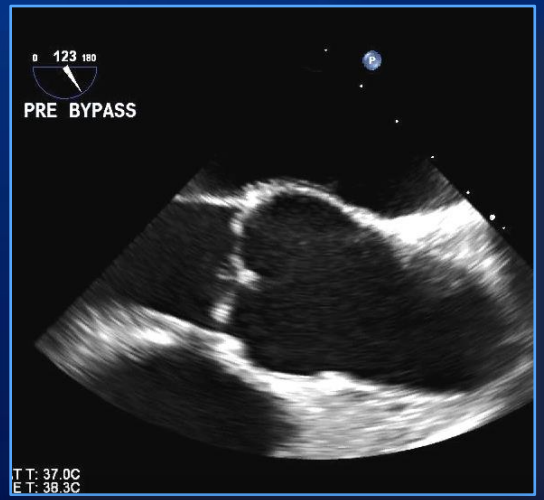

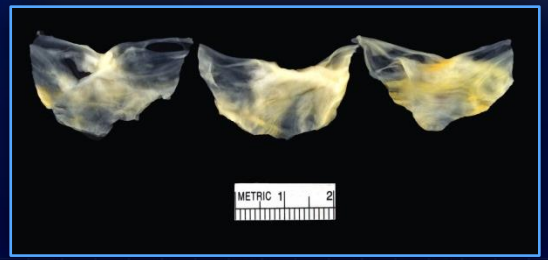

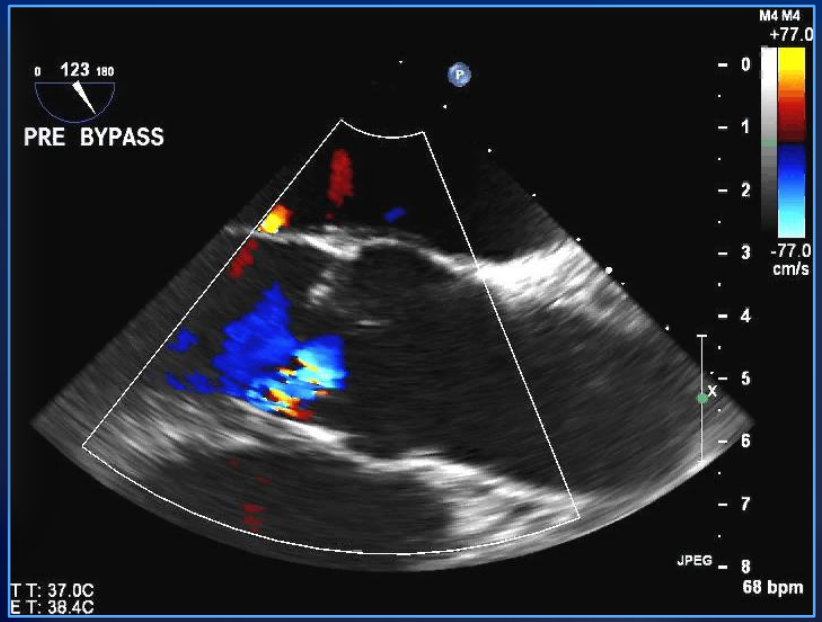

MAYO CLINIC
©2017 MFMER | 3645766-61

Repairable TAV?

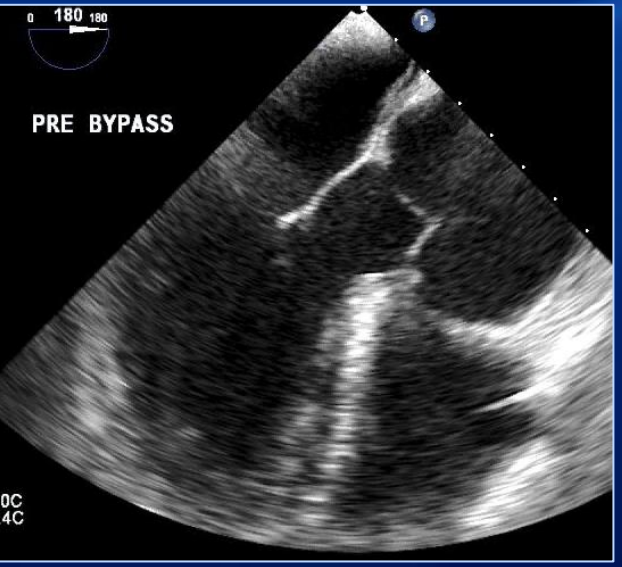

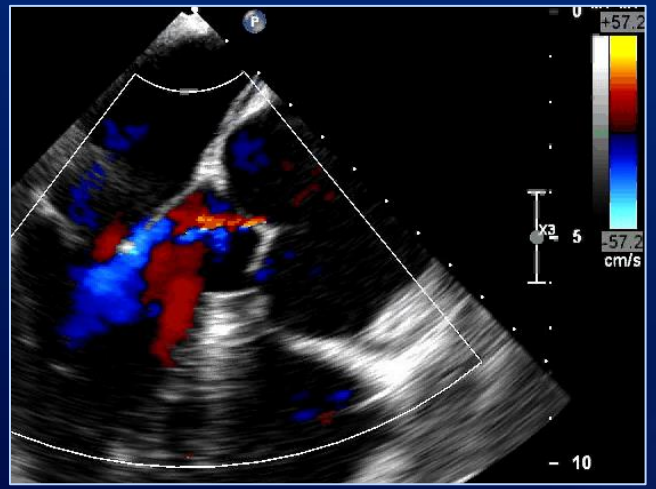

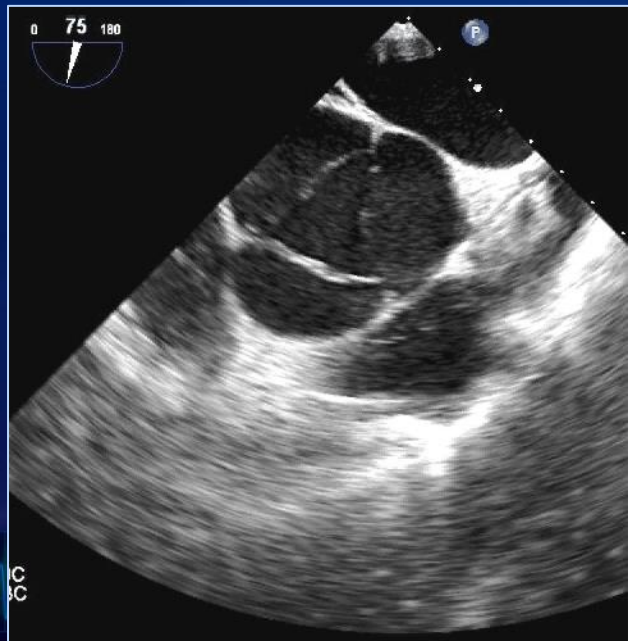

Yes repairable…

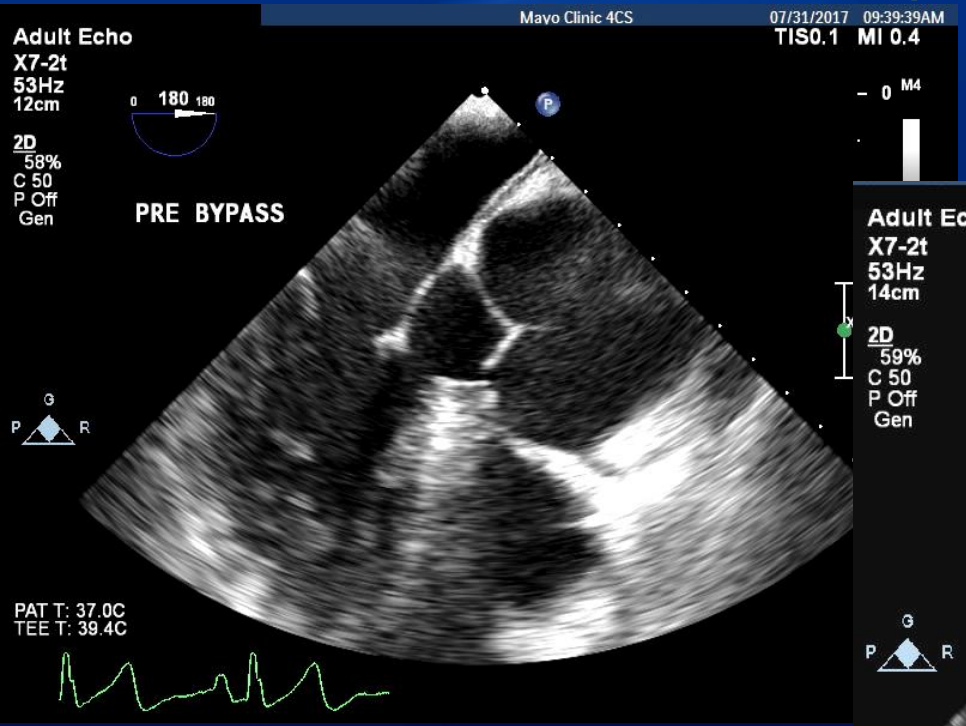

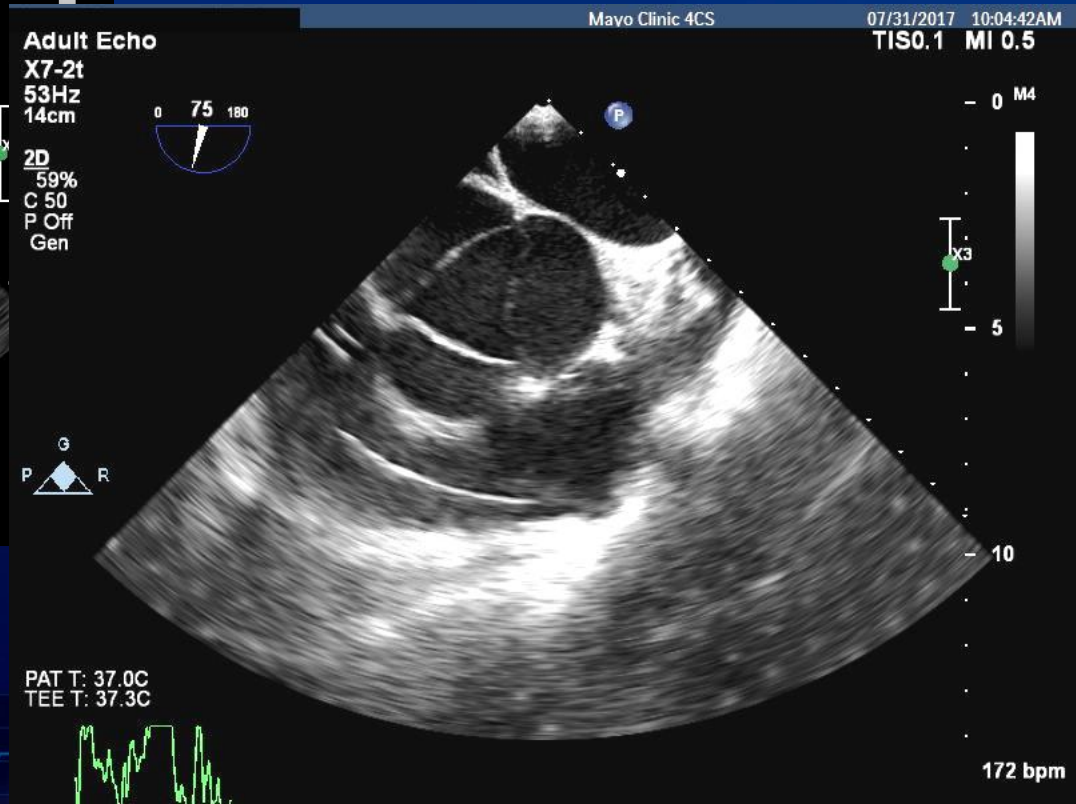

MAYO CLINIC

Repairable TAV?= No

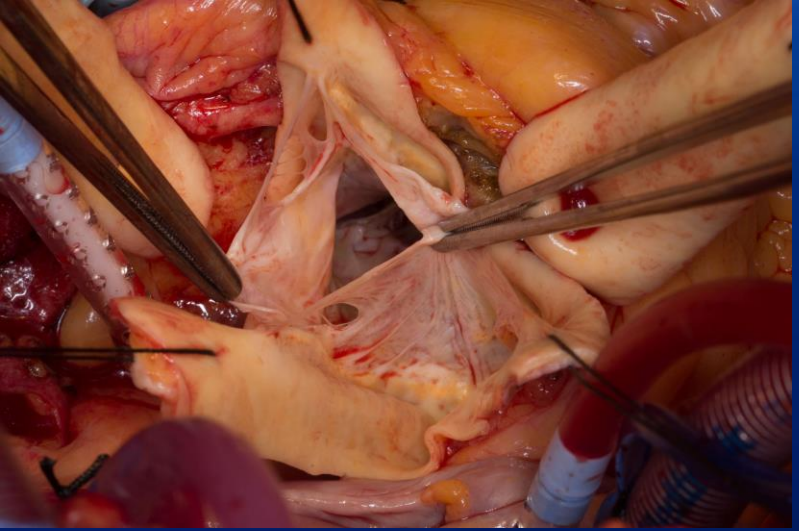

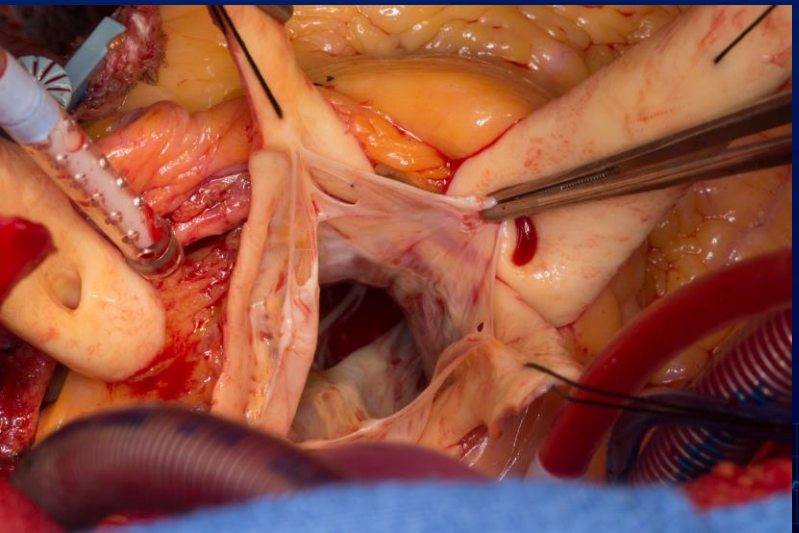

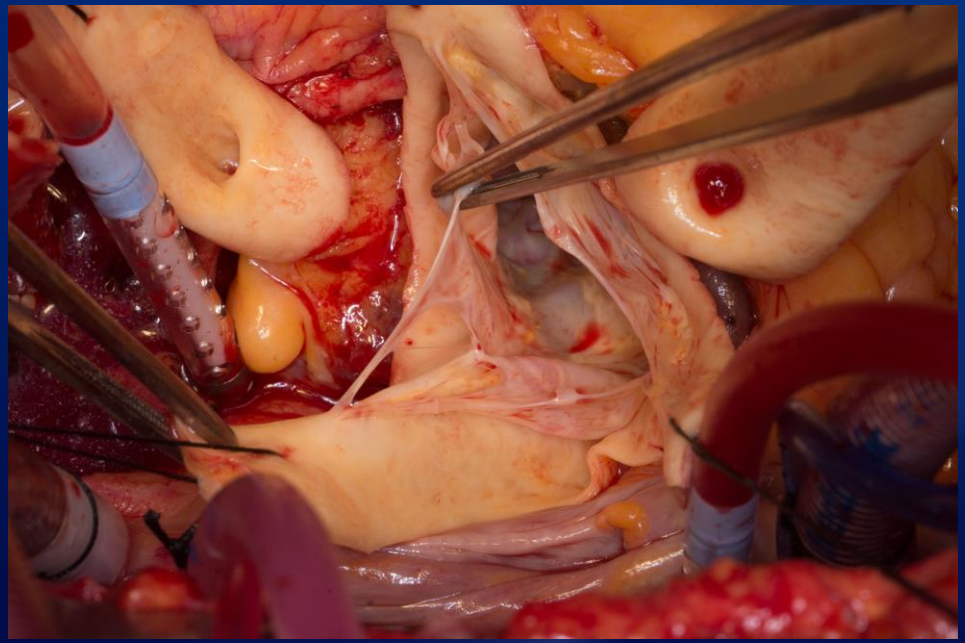

©2017 MFMER | 3645766-64

Intra-operative Imaging – IOTEE

a. Pre-bypass – Confirm, refine, search

b. Post-bypass – Most important, real-time clinical decision-making

Native Aorta

MAYO CLINIC

©2017 MFMER | 3645766-65

Ascending + hemiarch / total arch

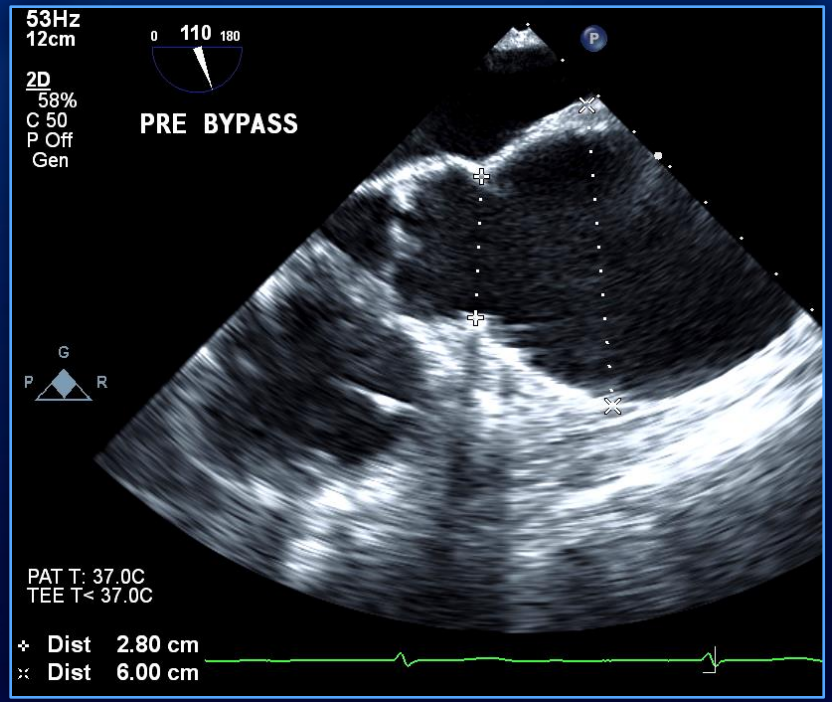

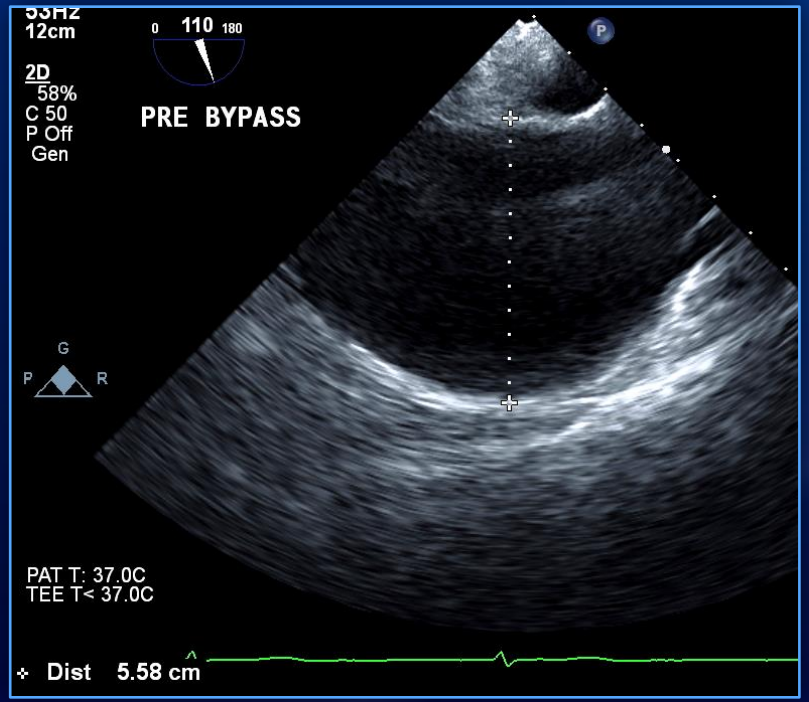

MAYO CLINIC
©2017 MFMER | 3645766-66

Ascending + hemiarch / total arch

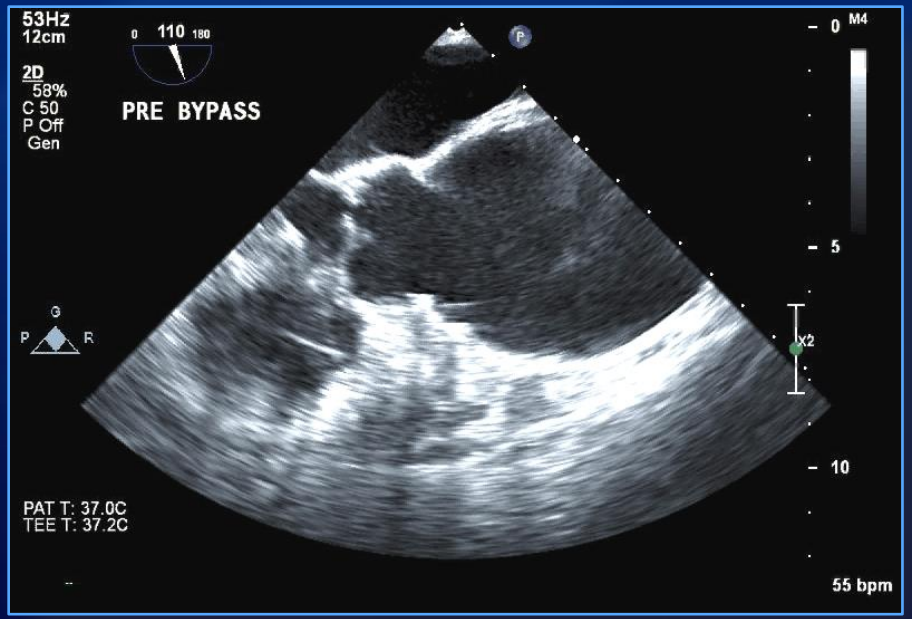

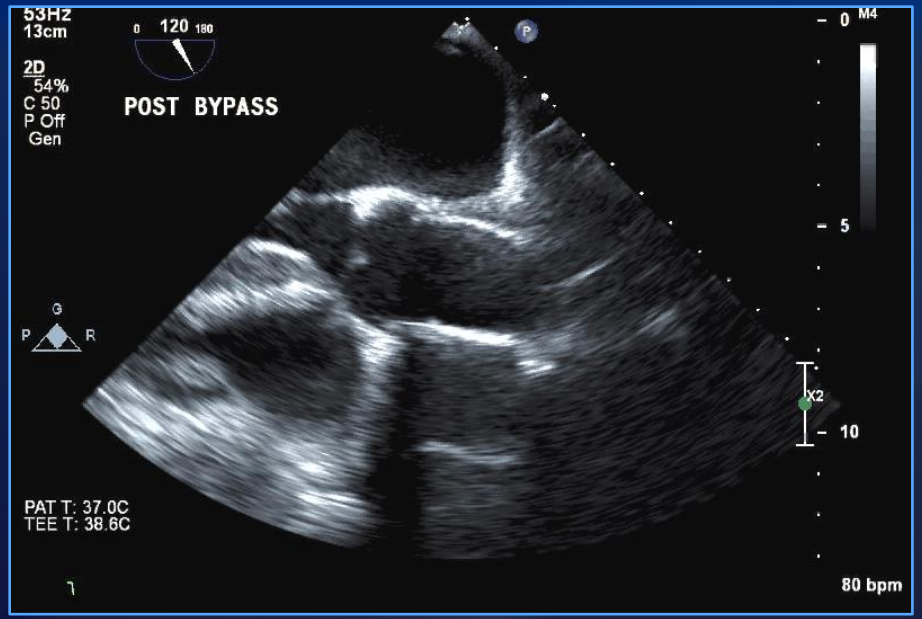

MAYO CLINIC
©2017 MFMER | 3645766-67

Ascending + hemiarch / total arch

Elephant Trunk

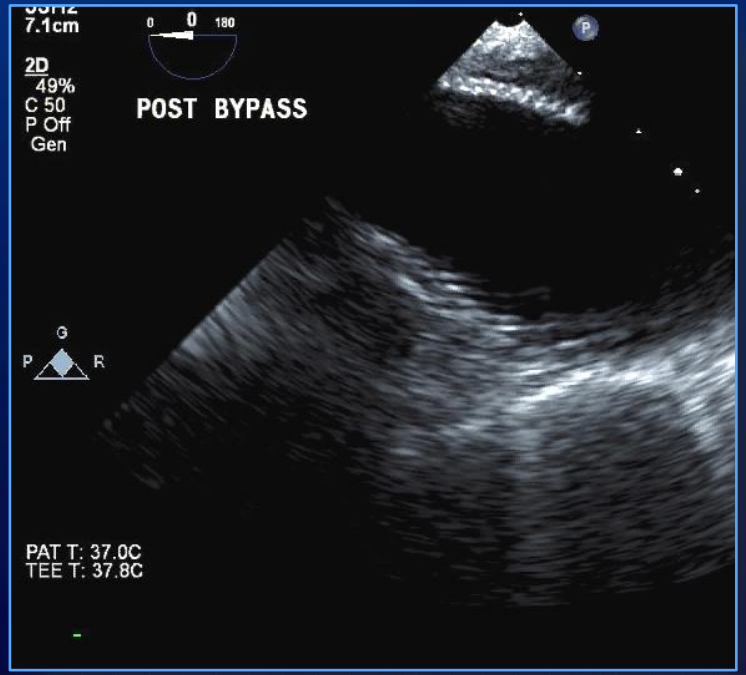

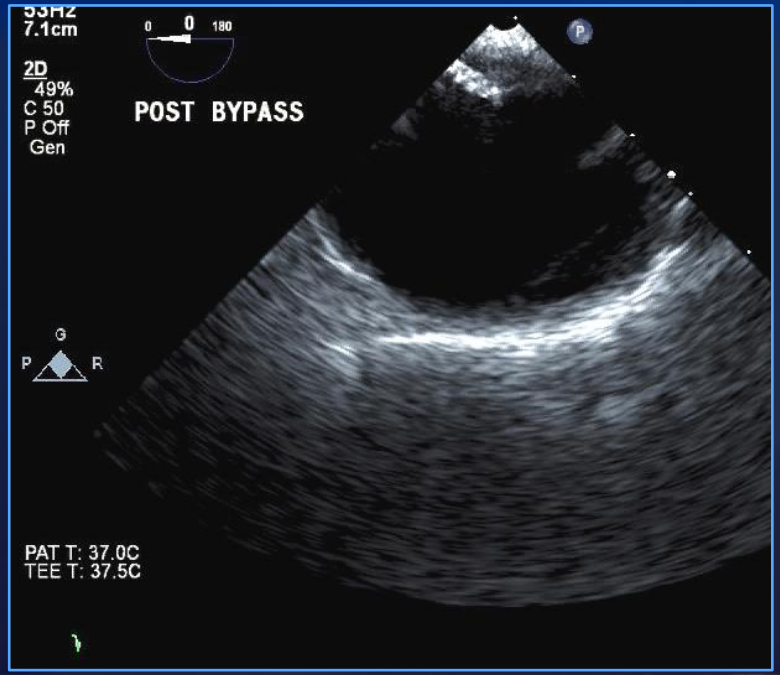

MAYO CLINIC
©2017 MFMER | 3645766-68

Ascending + hemiarch / total arch

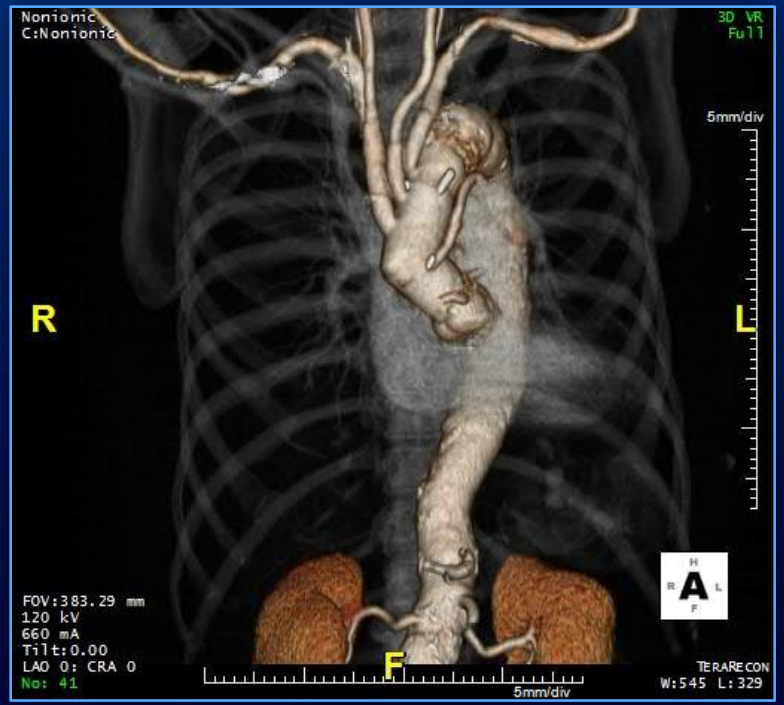

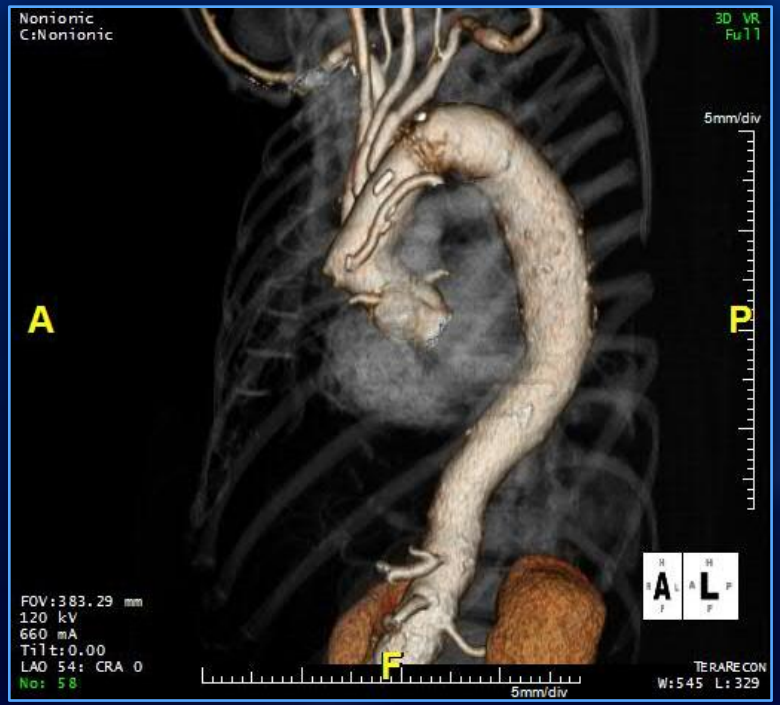

MAYO CLINIC
©2017 MFMER | 3645766-69

Intra-operative Imaging – IOTEE

a. Pre-bypass – Confirm, refine, search

b. Post-bypass – Most important, real-time clinical decision-making

Native Aorta

MAYO CLINIC

©2017 MFMER | 3645766-70

Bentall Operation

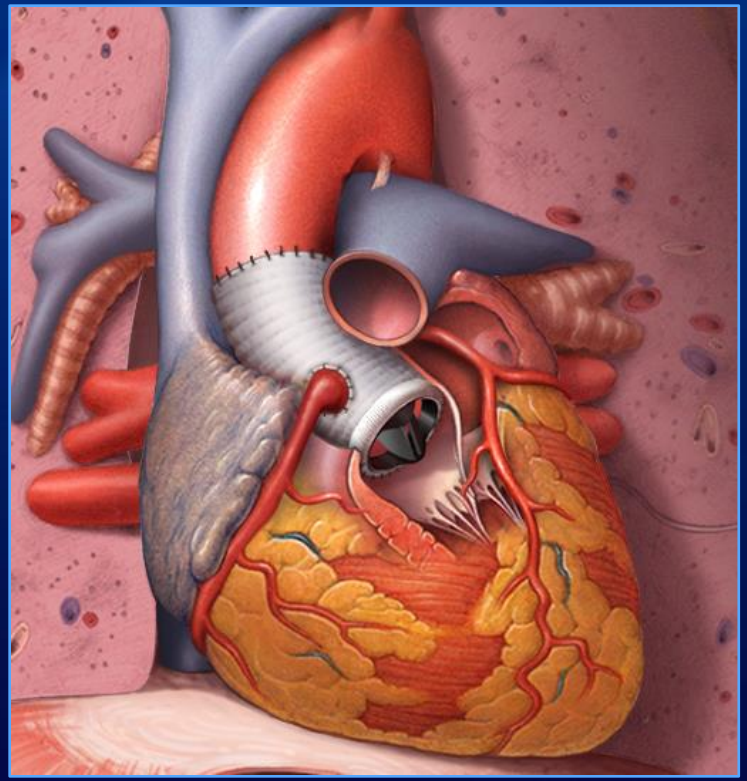

Valve Sparing Operation

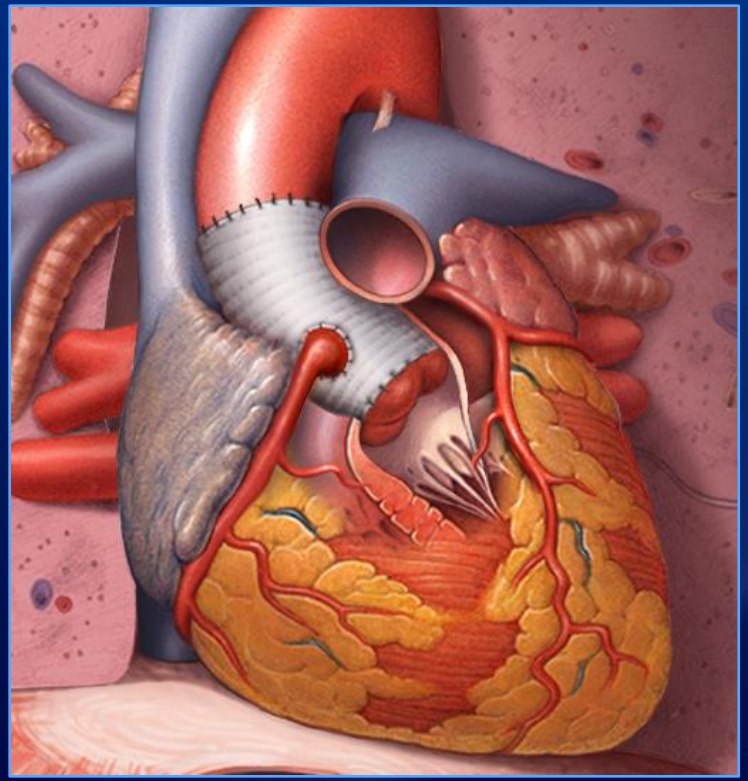

MAYO CLINIC

©2017 MFMER | 3645766-71

David Procedure

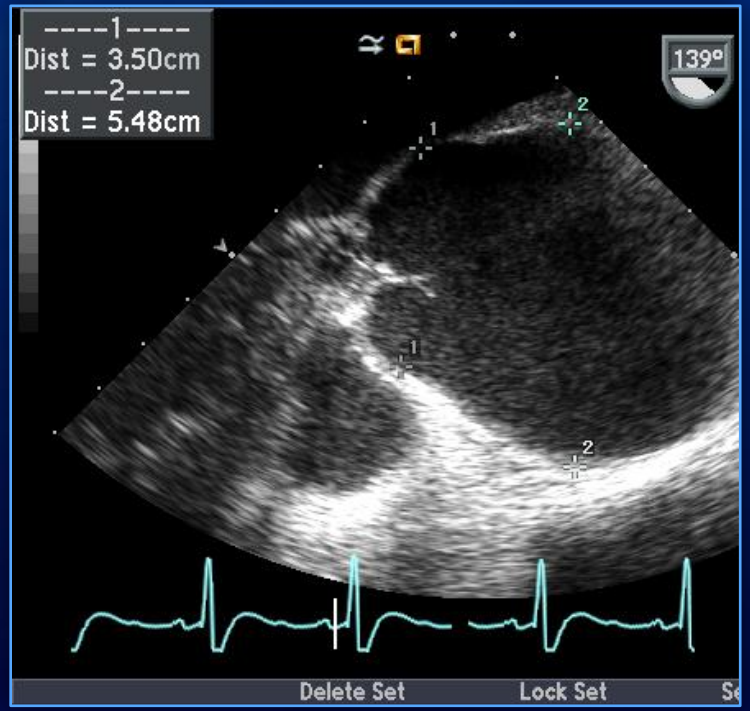

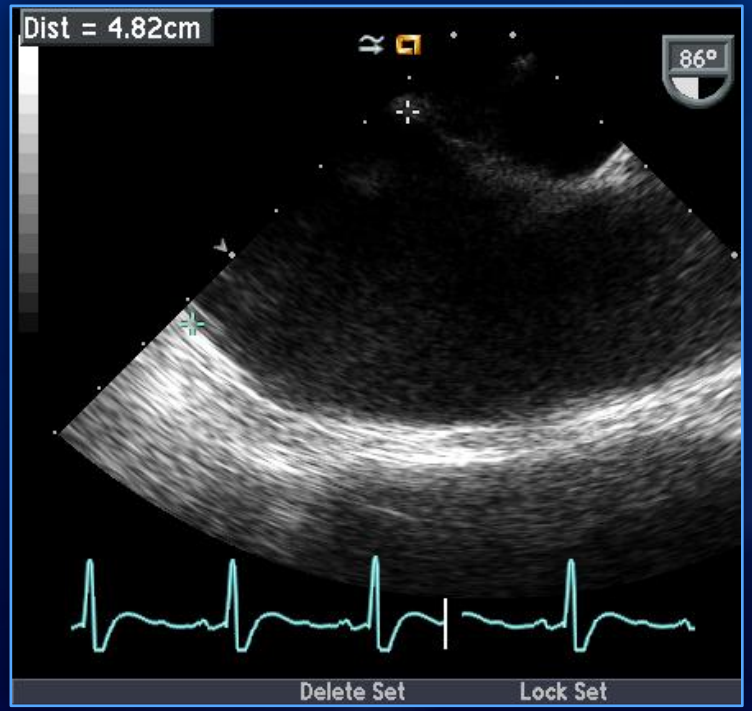

MAYO CLINIC
©2017 MFMER | 3645766-72

David Procedure

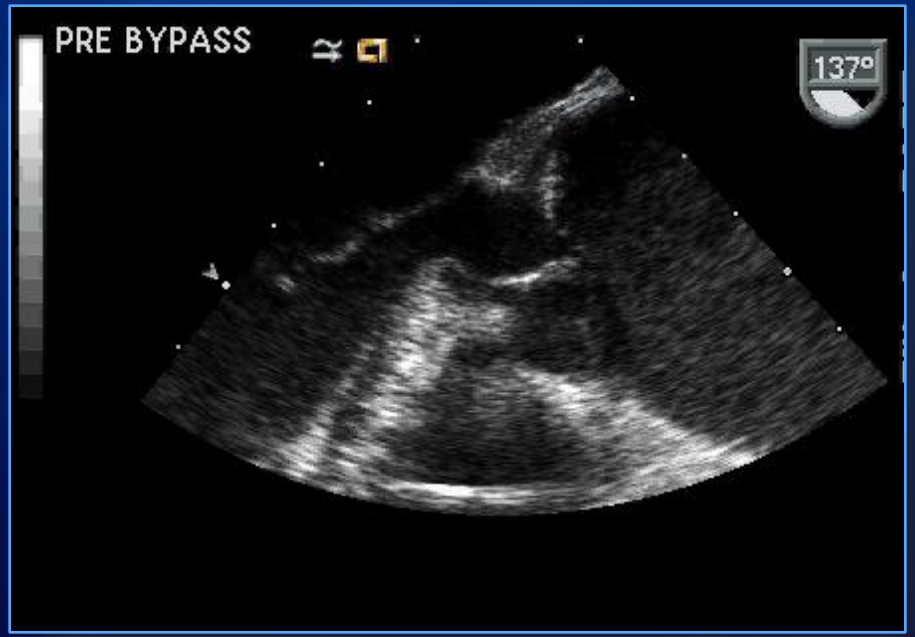

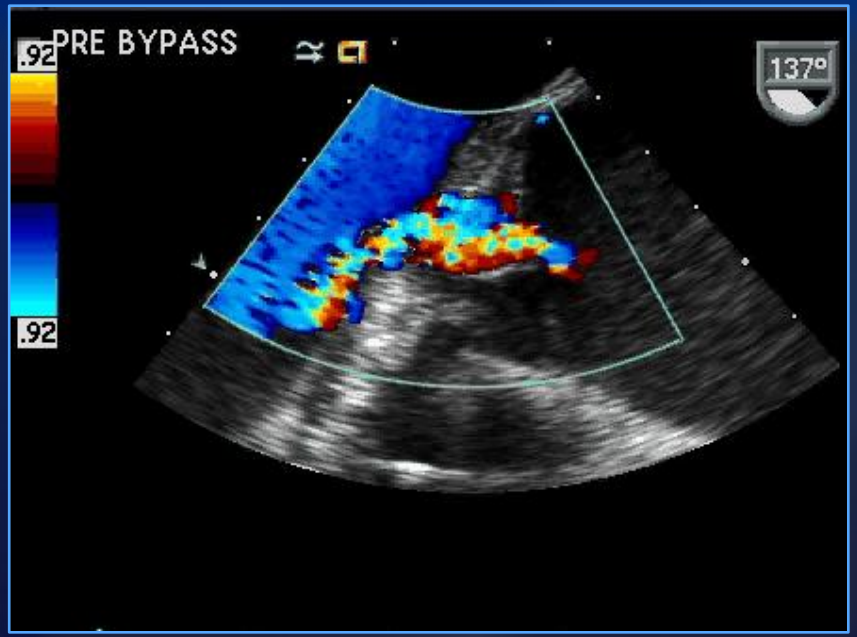

MAYO CLINIC
©2017 MFMER | 3645766-73

David Procedure

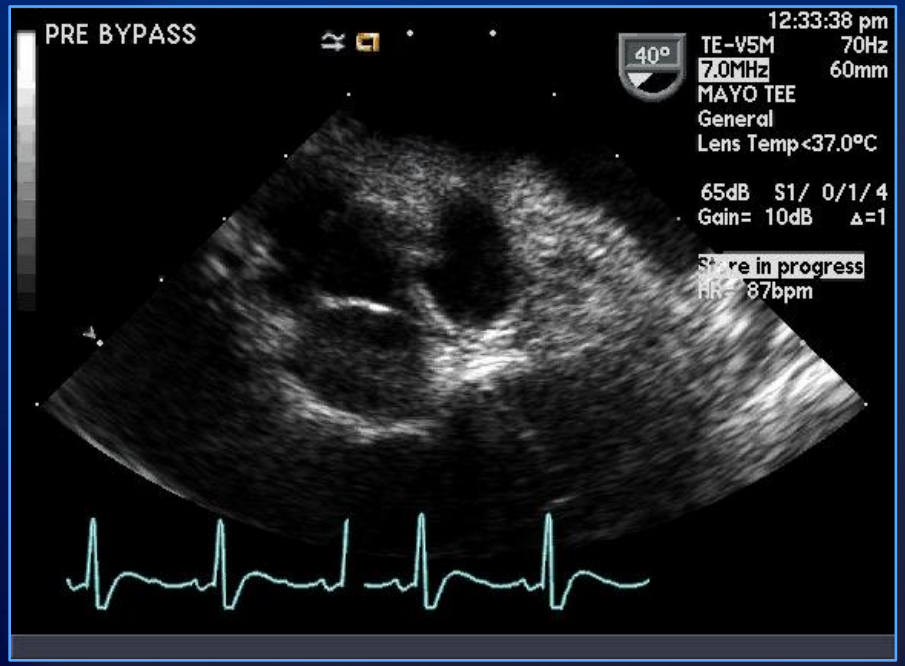

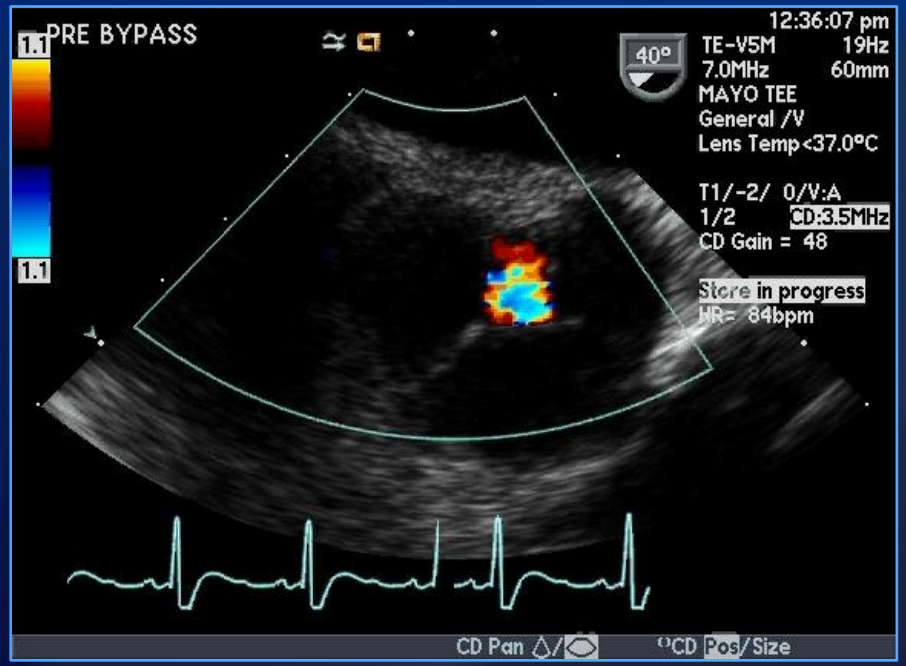

MAYO CLINIC
©2017 MFMER | 3645766-74

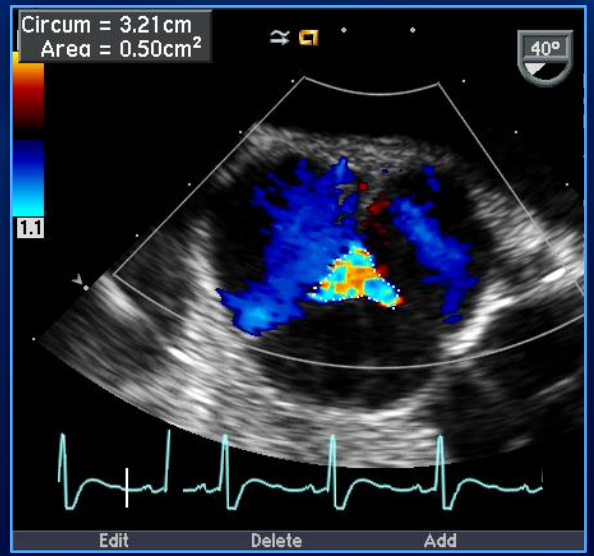

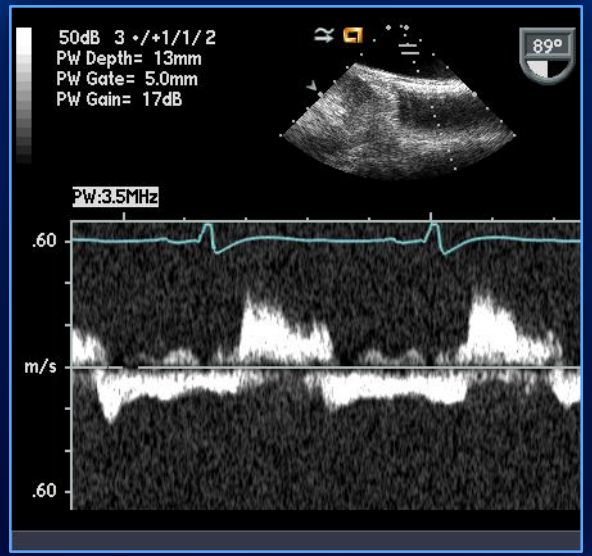

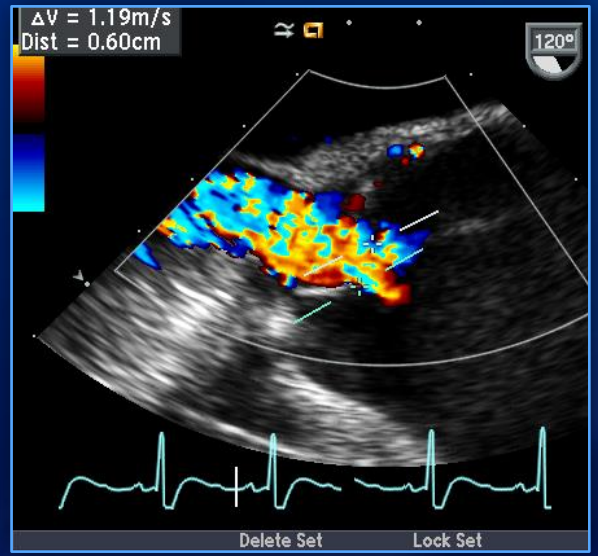

MAYO CLINIC
©2017 MFMER | 3645766-75

David Procedure

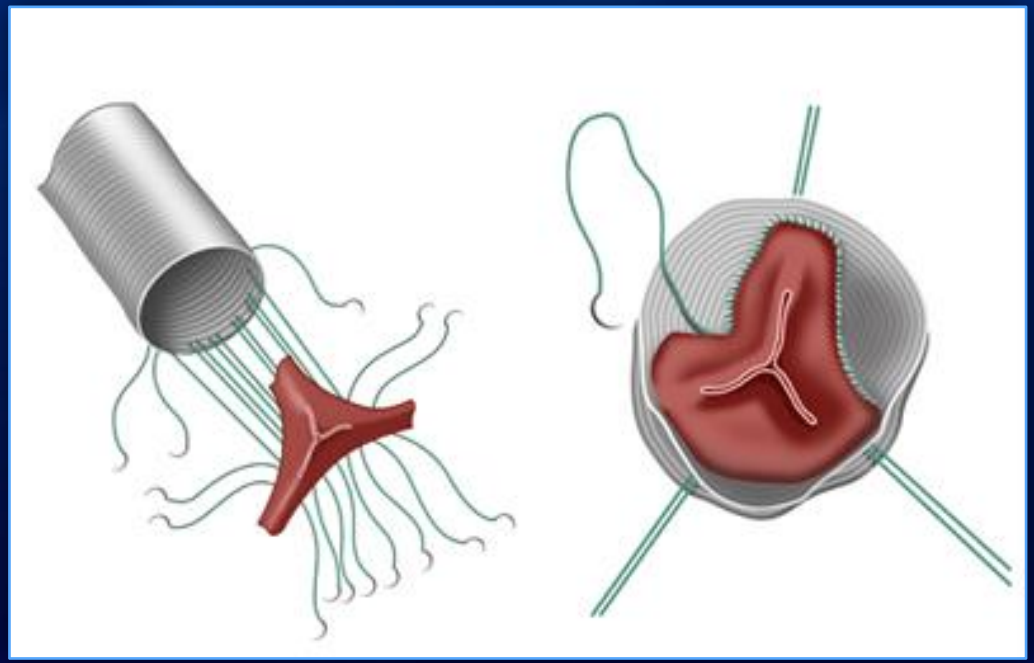

MAYO CLINIC

©2017 MFMER | 3645766-76

David Procedure
(and Bentall generally don’t have periprosthetic leaks!!)

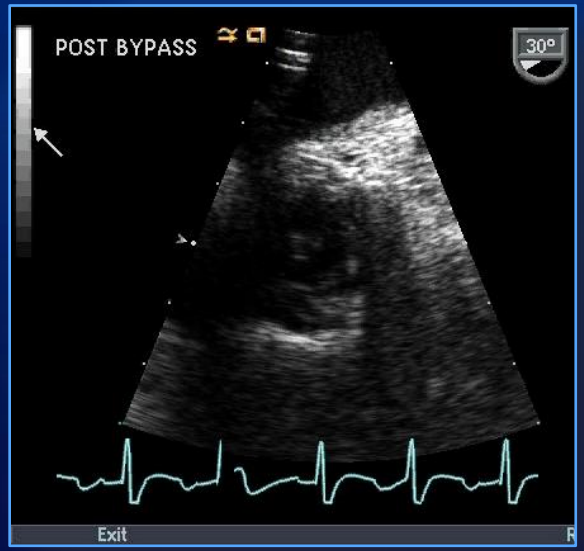

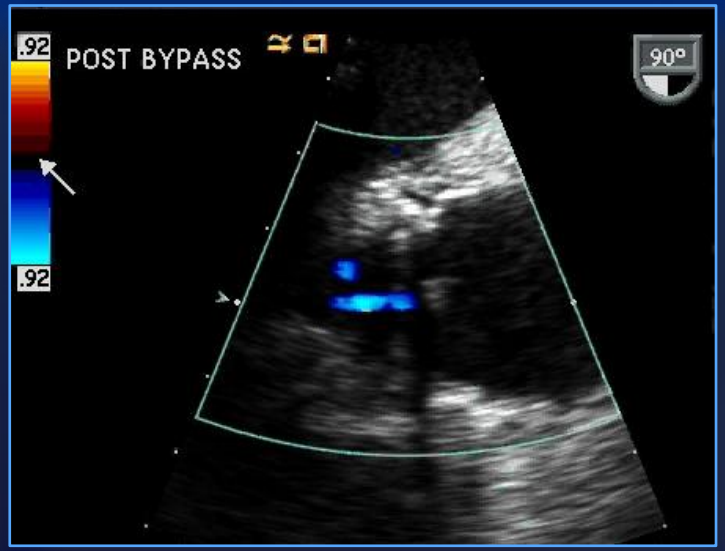

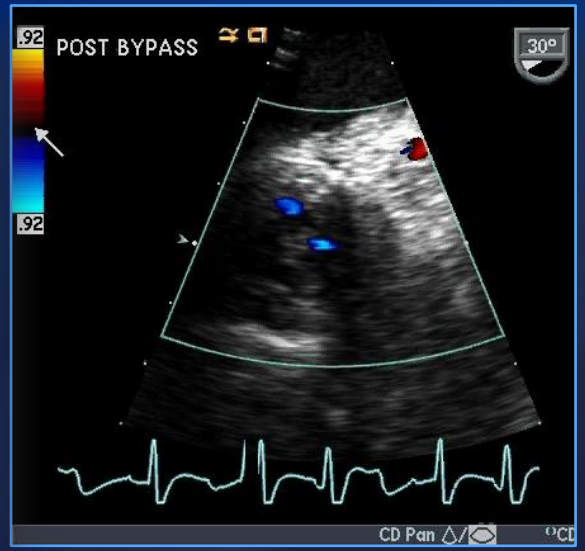

MAYO CLINIC
©2017 MFMER | 3645766-77

Coronary artery re-implantation

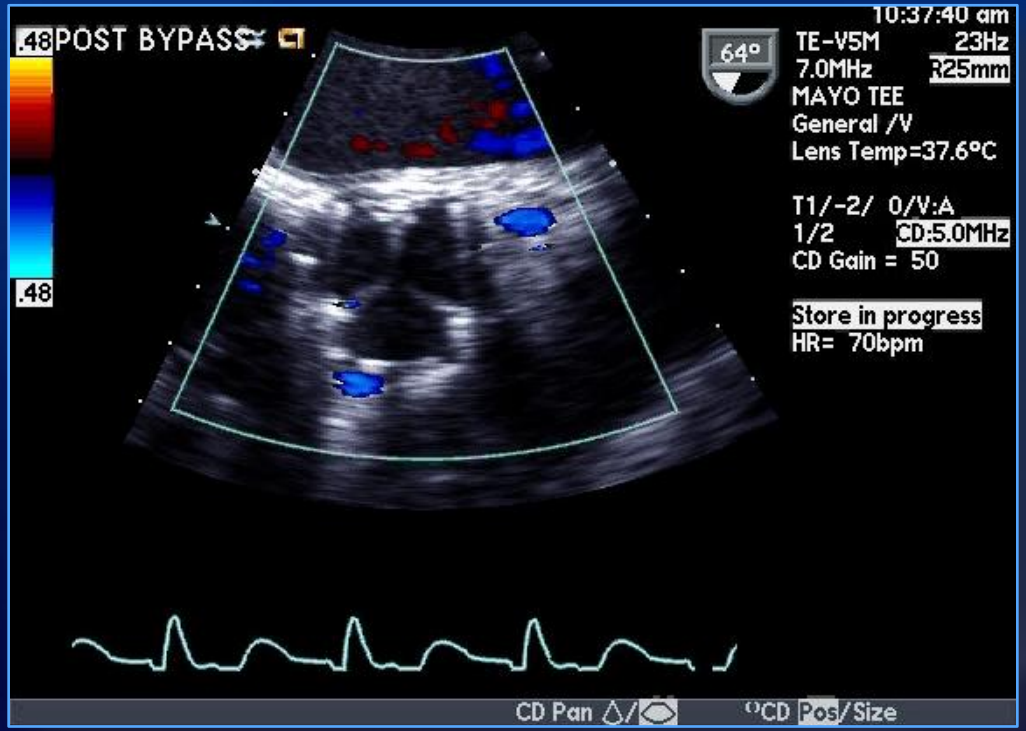

MAYO CLINIC
©2017 MFMER | 3645766-78

Coronary artery re-implantation

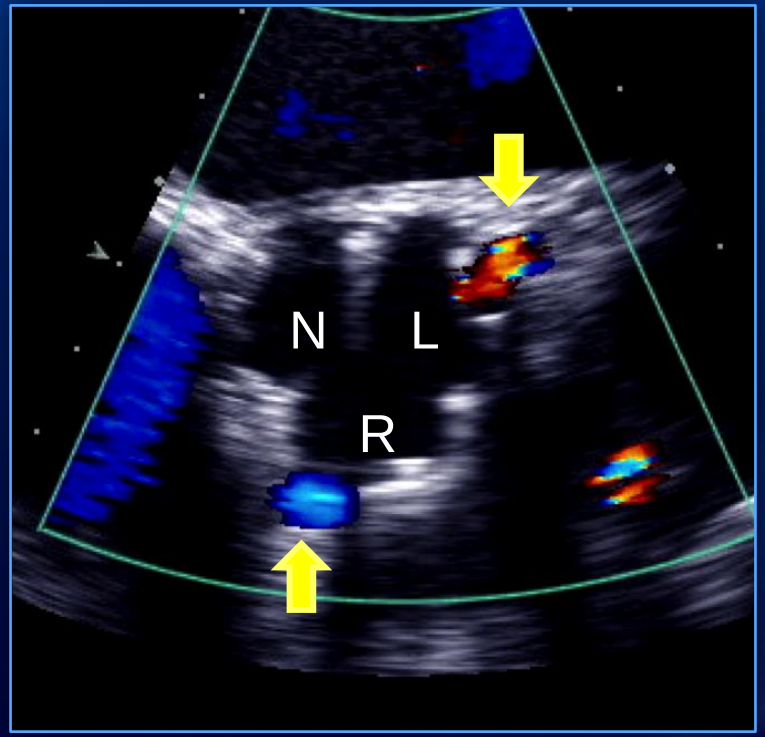

MAYO CLINIC
©2017 MFMER | 3645766-79

Intra-operative Imaging – IOTEE

a. Pre-bypass – Confirm, refine, search

b. Post-bypass – Most important, real-time clinical decision-making

Coronary reimplantation

MAYO CLINIC

©2017 MFMER | 3645766-80

Cabrol

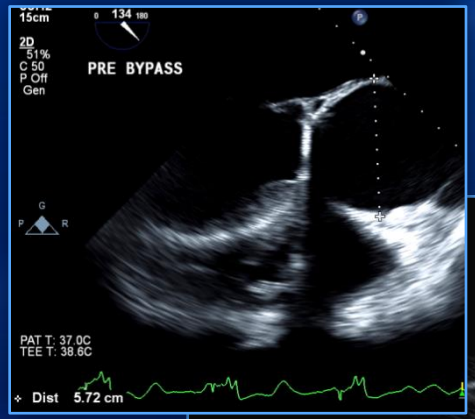

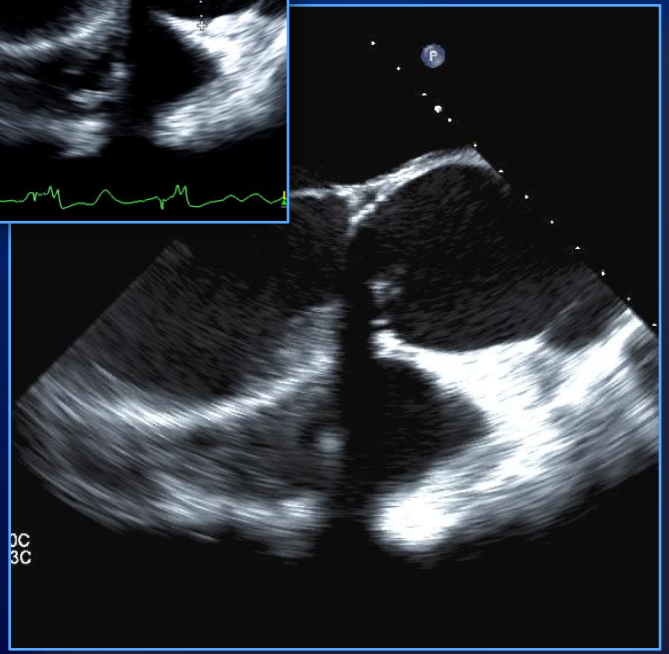

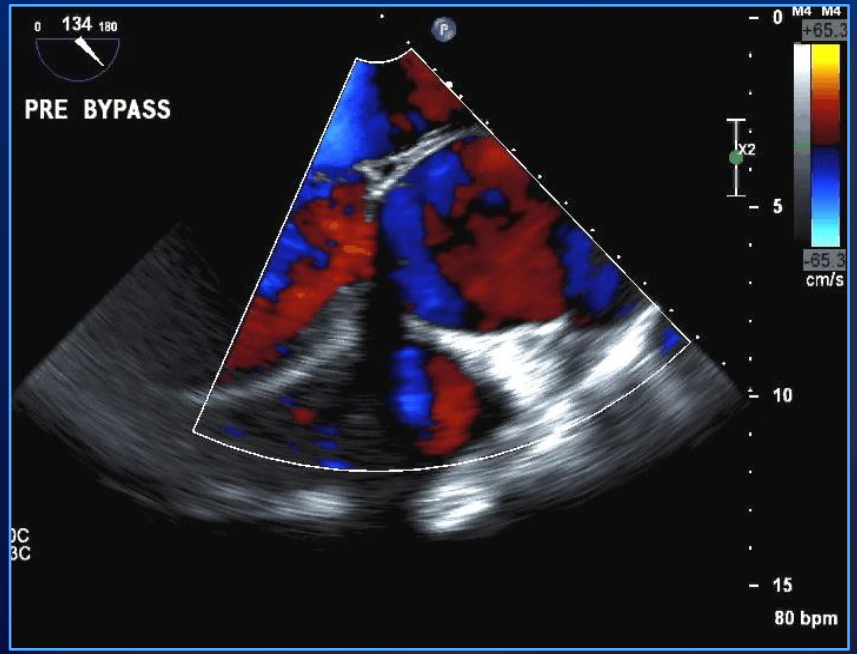

MAYO CLINIC
©2017 MFMER | 3645766-81

Evolution and Current Applications of the Cabrol Procedure and Its Modifications

Antonios Kourliouros, PhD, MRCS, Manish Soni, MD, MRCS, Sonia Rasoli, MD, Julia Grapsa, MD, Petros Nihoyannopoulos, MD, FRCP, Declan O'Regan, PhD, FRCR, and Thanos Athanasiou, PhD, FECTS

(Ann Thorac Surg 2011;91:1636–41)

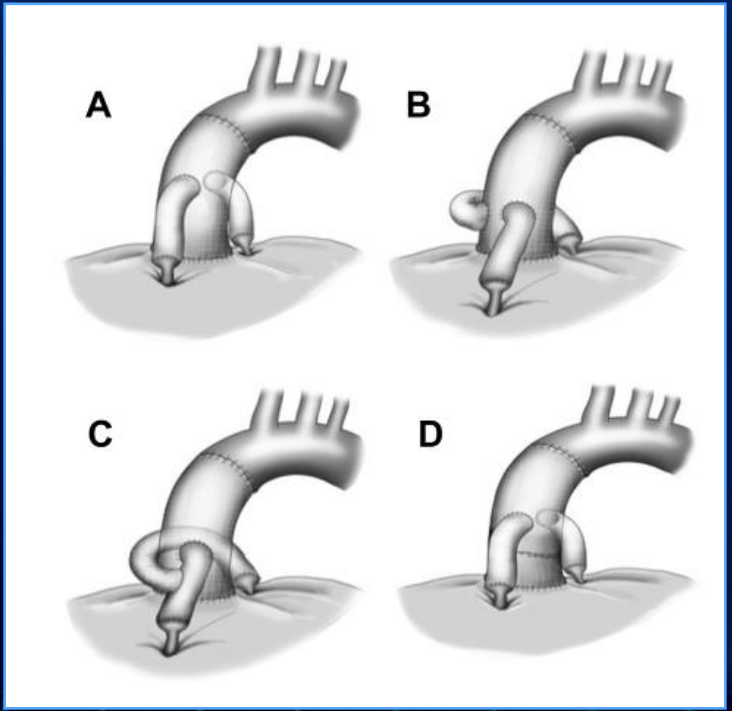

MAYO CLINIC

©2017 MFMER | 3645766-82

Cabrol

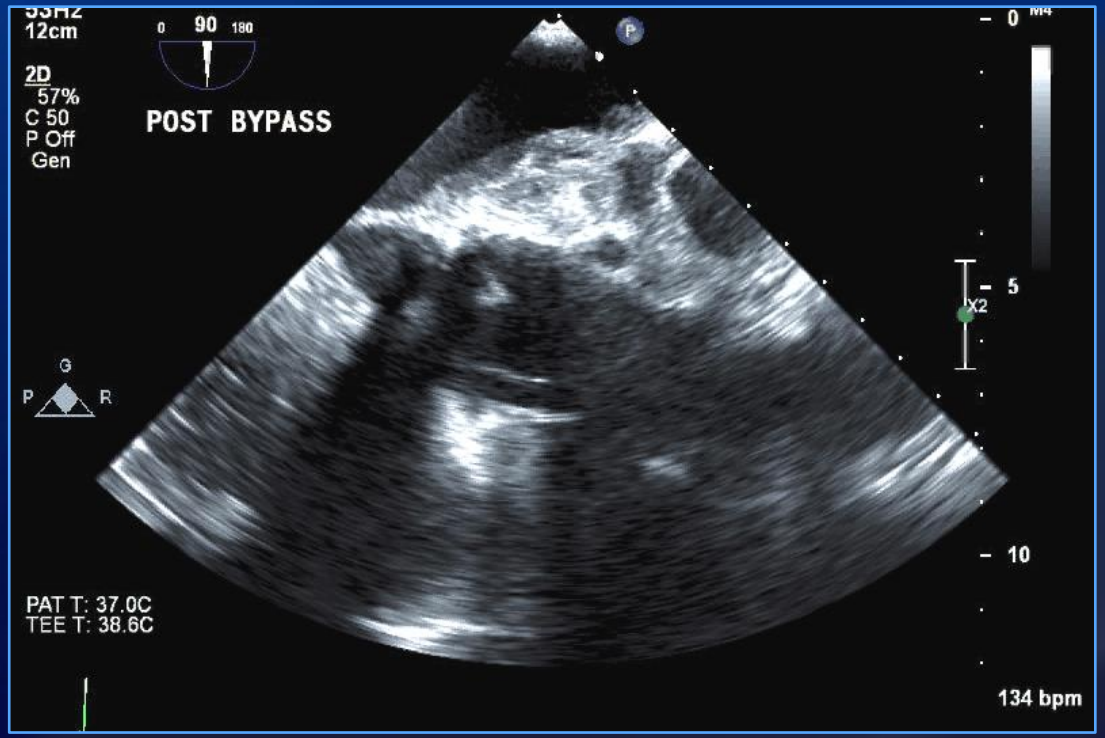

MAYO CLINIC
©2017 MFMER | 3645766-83

Cabrol

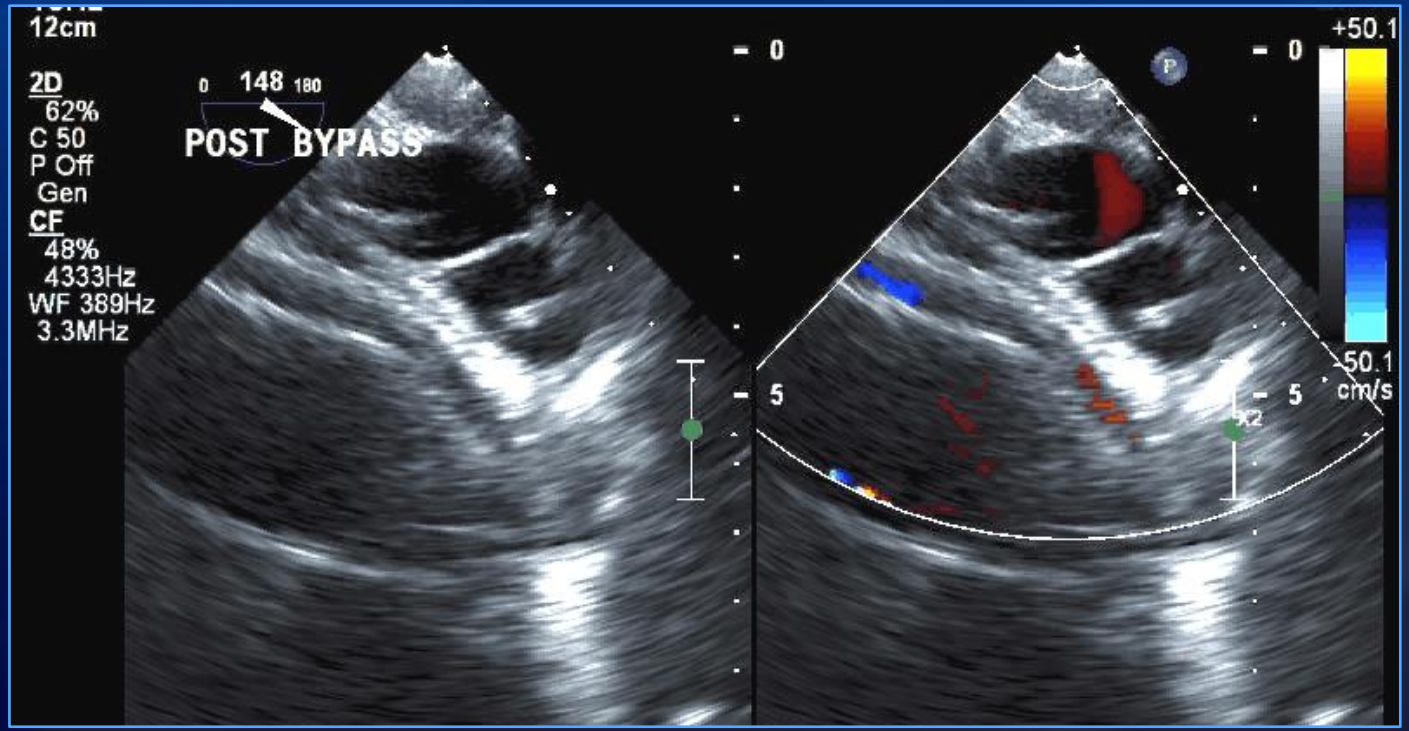

MAYO CLINIC
©2017 MFMER | 3645766-84

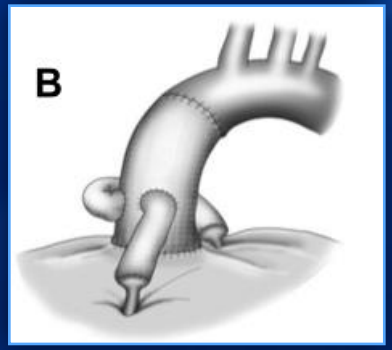

Hemi/semi Cabrol = left coronary

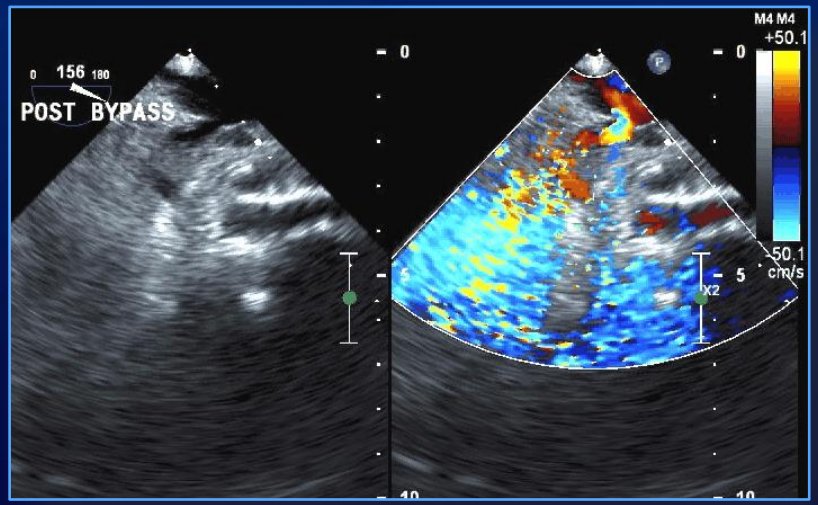

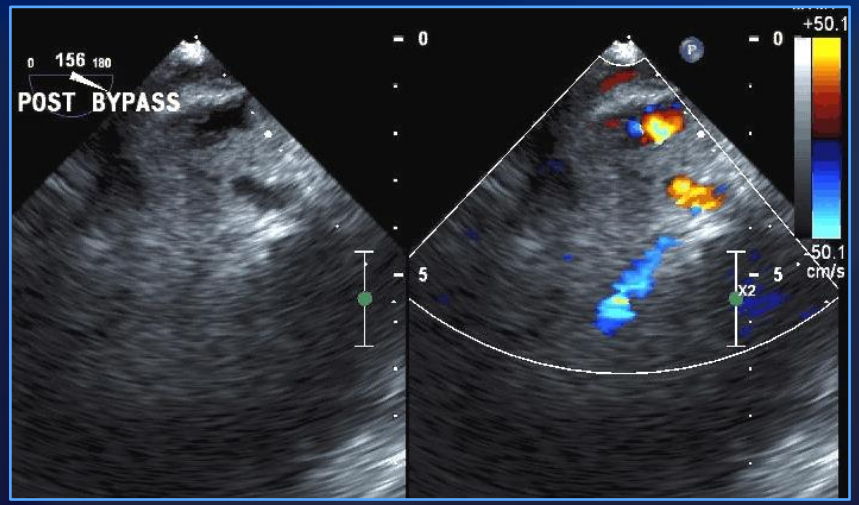

MAYO CLINIC
©2017 MFMER | 3645766-85

Cabrol

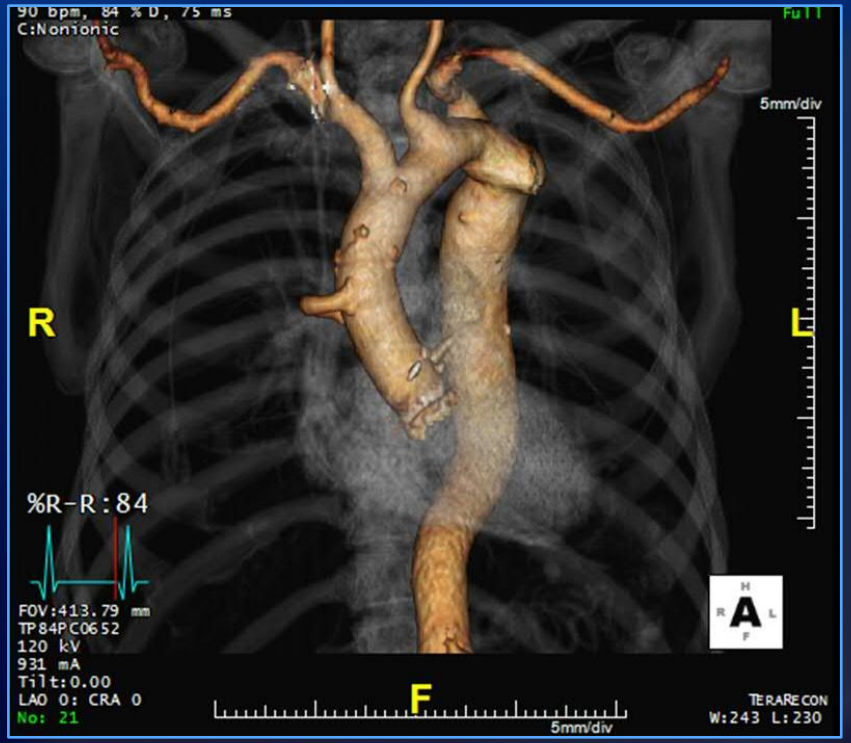

©2017 MFMER | 3645766-86

Cabrol

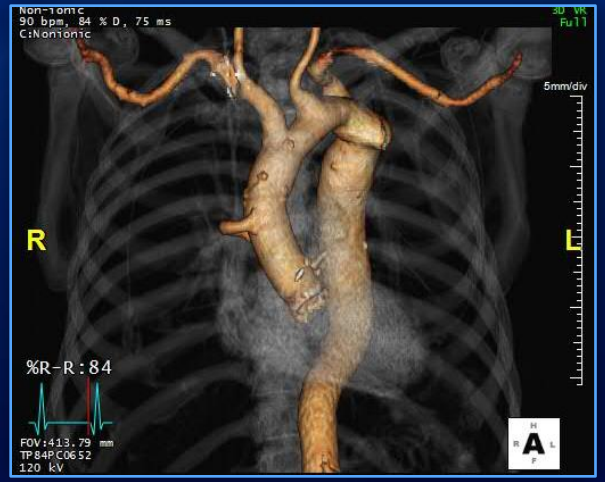

MAYO CLINIC
©2017 MFMER | 3645766-87

Cant always repair---
IOTEE

Perivalvular Leaks
Astute 2D

©2017 MFMER | 3645766-88

Communication

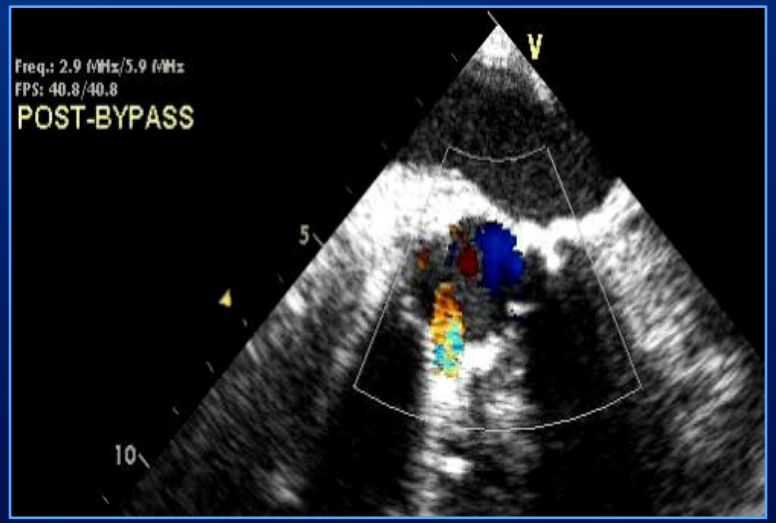

MAYO CLINIC
©2017 MFMER | 3645766-89

Communication-Prompted 2nd Bypass Run

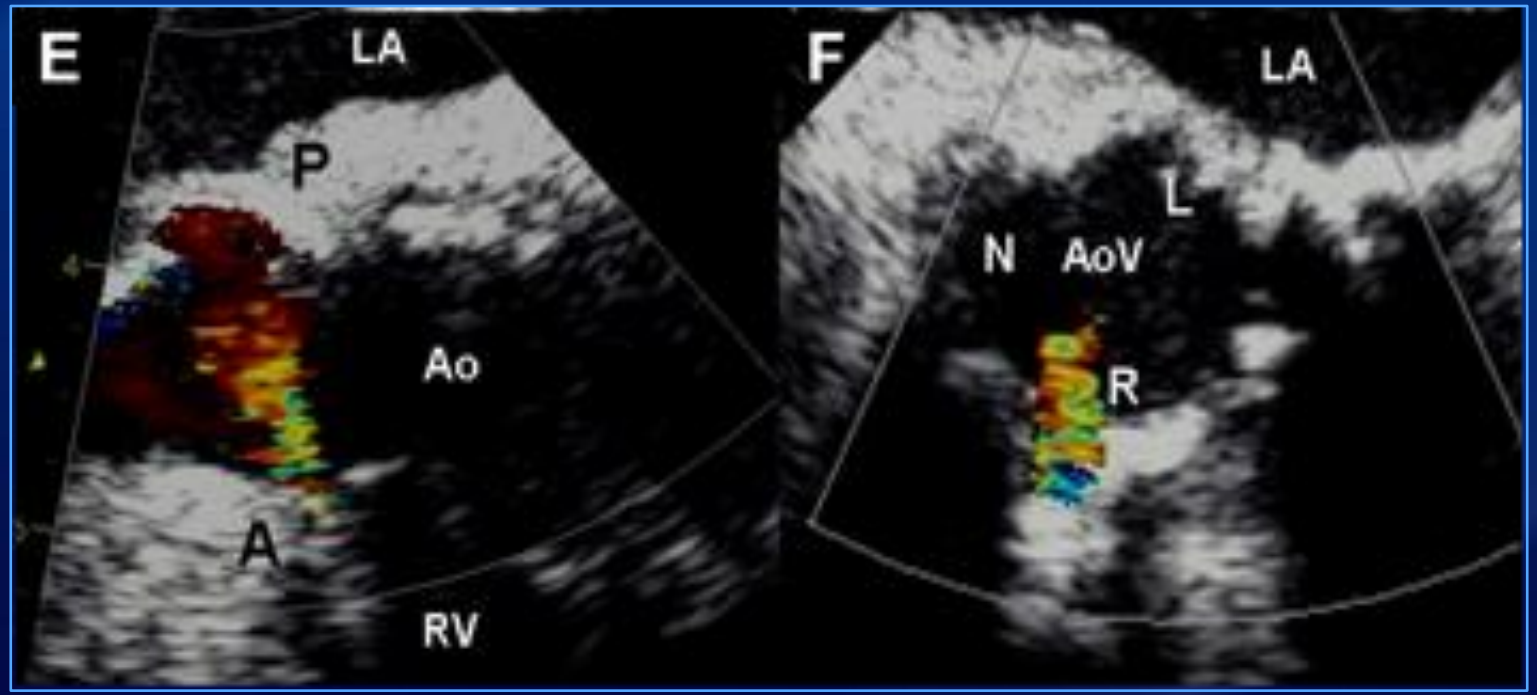

MAYO CLINIC
©2017 MFMER | 3645766-90

“Very Low” Periprosthetic Leaks

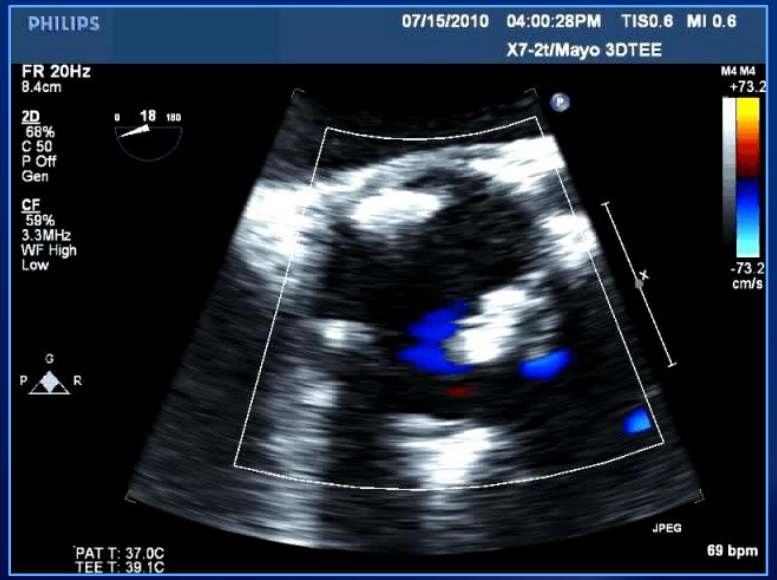

MAYO CLINIC
©2017 MFMER | 3645766-91

“Very Low” Periprosthetic Leaks

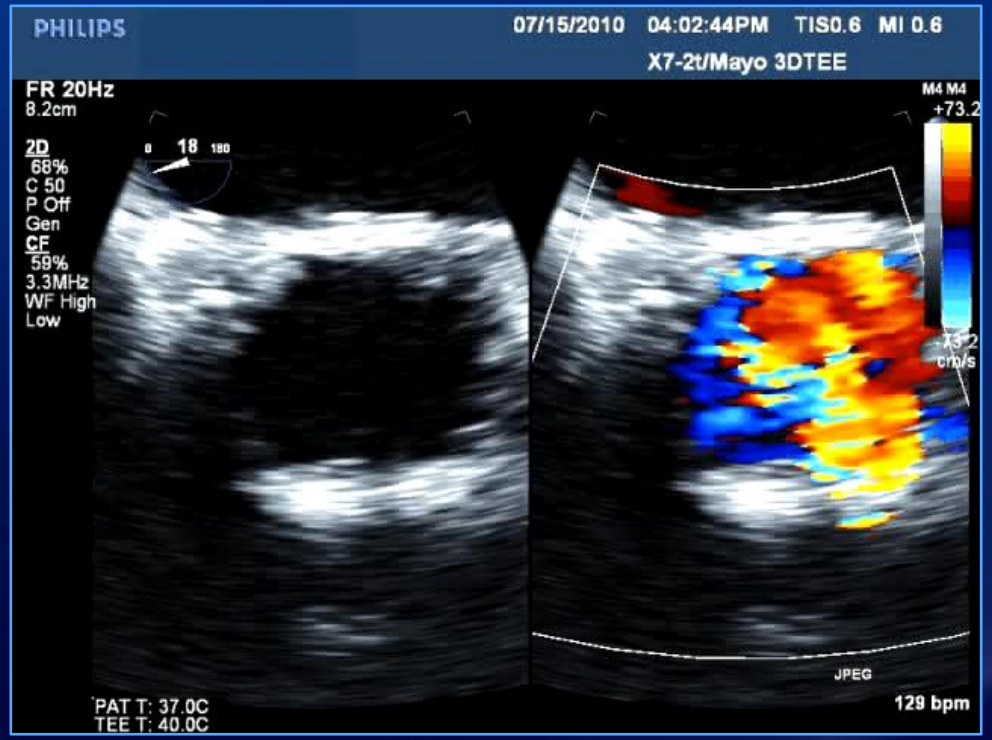

MAYO CLINIC
©2017 MFMER | 3645766-92

“Very Low” Periprosthetic Leaks

MAYO CLINIC
©2017 MFMER | 3645766-93

“Very Low” Periprosthetic Leaks

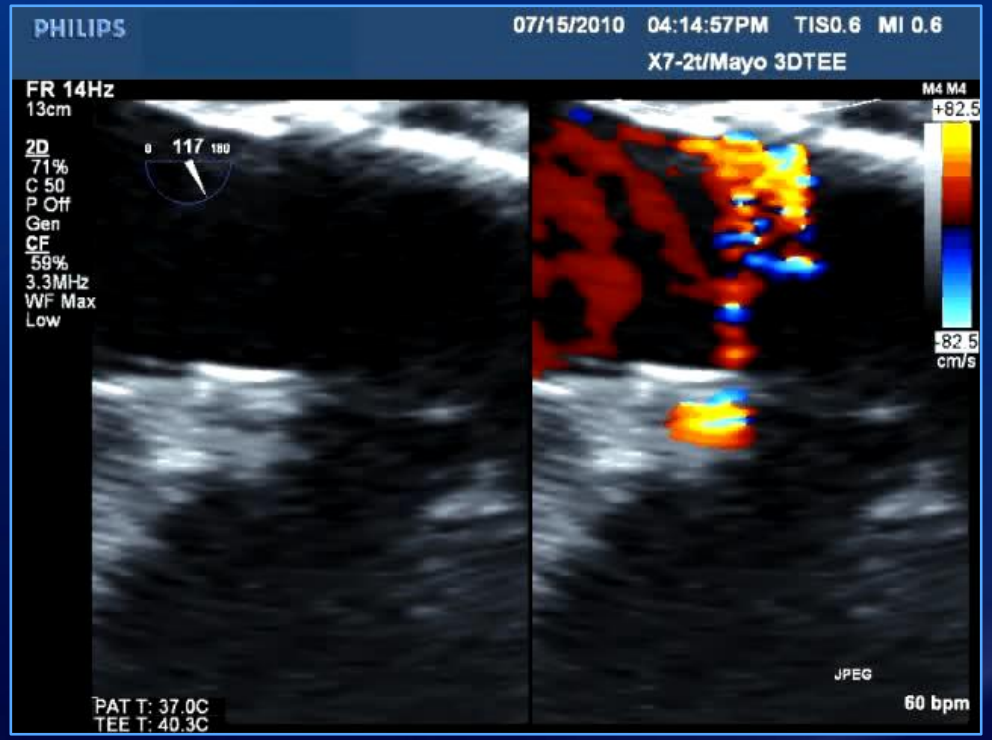

MAYO CLINIC
©2017 MFMER | 3645766-94

“Very Low” Periprosthetic Leaks

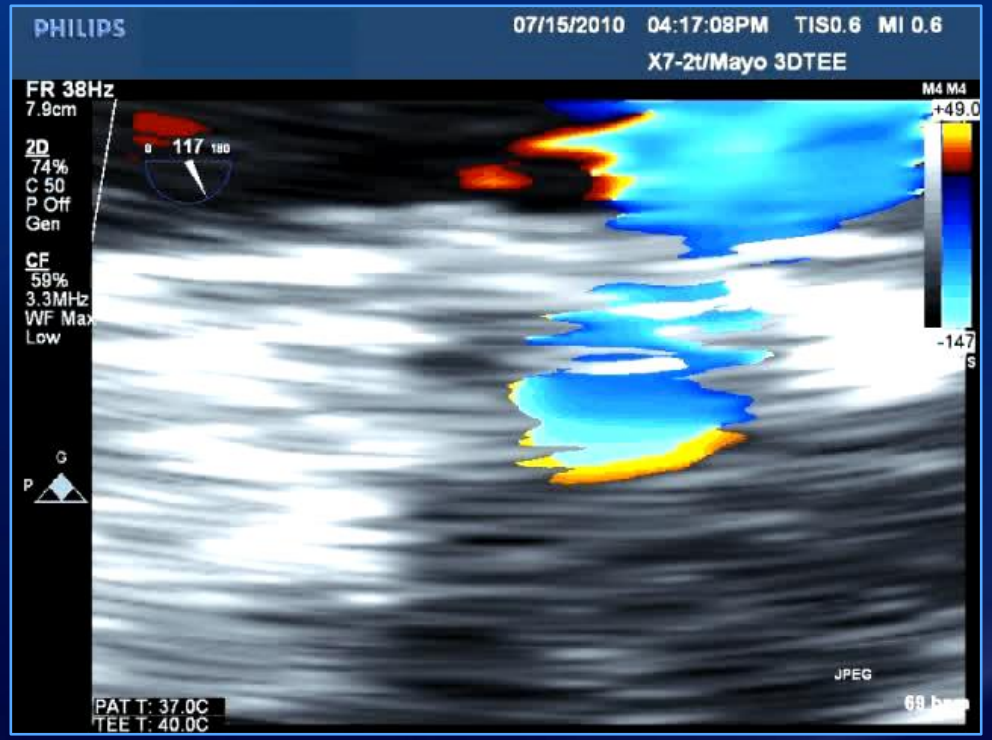

MAYO CLINIC
©2017 MFMER | 3645766-95

There is Something More Important:
Supreme Virtue

- Giving birth and nourishing
- Having without possessing
- Acting with no expectations
- Leading without trying to control

Tao te ching

MAYO CLINIC

©2017 MFMER | 3645766-96

Drs Pochettino and Sundt
Aorta surgeons

MAYO CLINIC

©2017 MFMER | 3645766-97

Dr Rakesh Suri

MAYO CLINIC

©2017 MFMER | 3645766-98

Dr Hartzell Schaff

MAYO CLINIC

©2017 MFMER | 3645766-99

Moral responsibility to patients and colleagues
to produce an echocardiographic report closest
to the truth…

©2017 MFMER | 3645766-100

Comprehensive Intra-operative Echocardiography in the Adult: Anatomy Mechanisms Communication

michelena.hector@mayo.edu

©2017 MFMER | 3645766-101