Reconstruction of the Aortic Valve and Root: A Practical Approach
September 13th-15th, 2017, Homburg/Saar, Germany

Root Repair in AI: The Brussels Approach

Laurent de Kerchove, MD, PhD
Departement of Cardiothoracic and Vascular Surgery
Cliniques Universitaires St-Luc, IREC, UCL, Brussels, Belgium

Cliniques universitaires SAINT-LUC UCL BRUXELLES

UCL Université catholique de Louvain

I.	II.	III.	IV.
I have received (a) research grant(s) / in kind support	I have been a speaker or participant in accredited CME/CPD ...	I have been a consultant / strategic advisor etc. ...	I am a holder of (a) patent / shares / stocks or ownership...
A	**A**	**A**	**A**
... from current sponsor(s)	... from current sponsor(s)	... for current sponsor(s)	... related to presentation
YES: X / NO:	YES: X / NO:	YES: X / NO:	YES: / NO: X
B	**B**	**B**	**B**
... from any institution	... from any institution	... for any institution	... not related to presentation
YES: / NO: X	YES: / NO: X	YES: / NO: X	YES: / NO: X

SCORE: 1234

Lesson from MV repair

- 30 years experience with MV repair

  - Valve repair must treat leaflet but also annulus pathology
  - Annulus dilatation is frequent in MI
  - Annuloplasty restore ratio between leaflet tissues and valve orifice area
  - Absence of annuloplasty increase recurrence of MI (*Flameng W. Circ. 2003)*

No one would do MV repair without some annuloplasty !

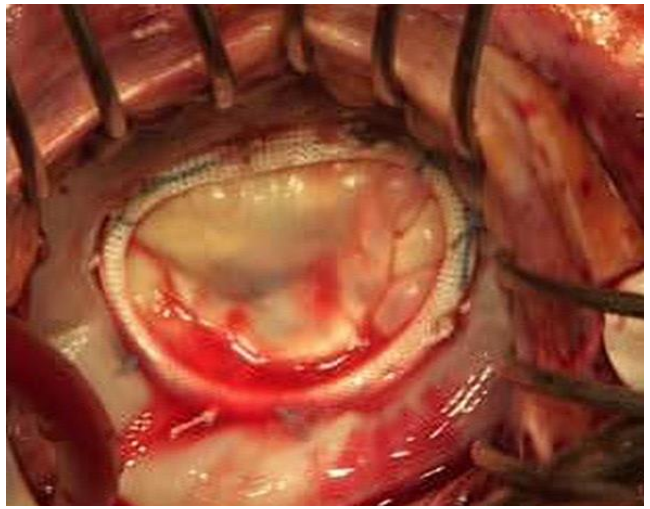

Aortic Root Anatomy

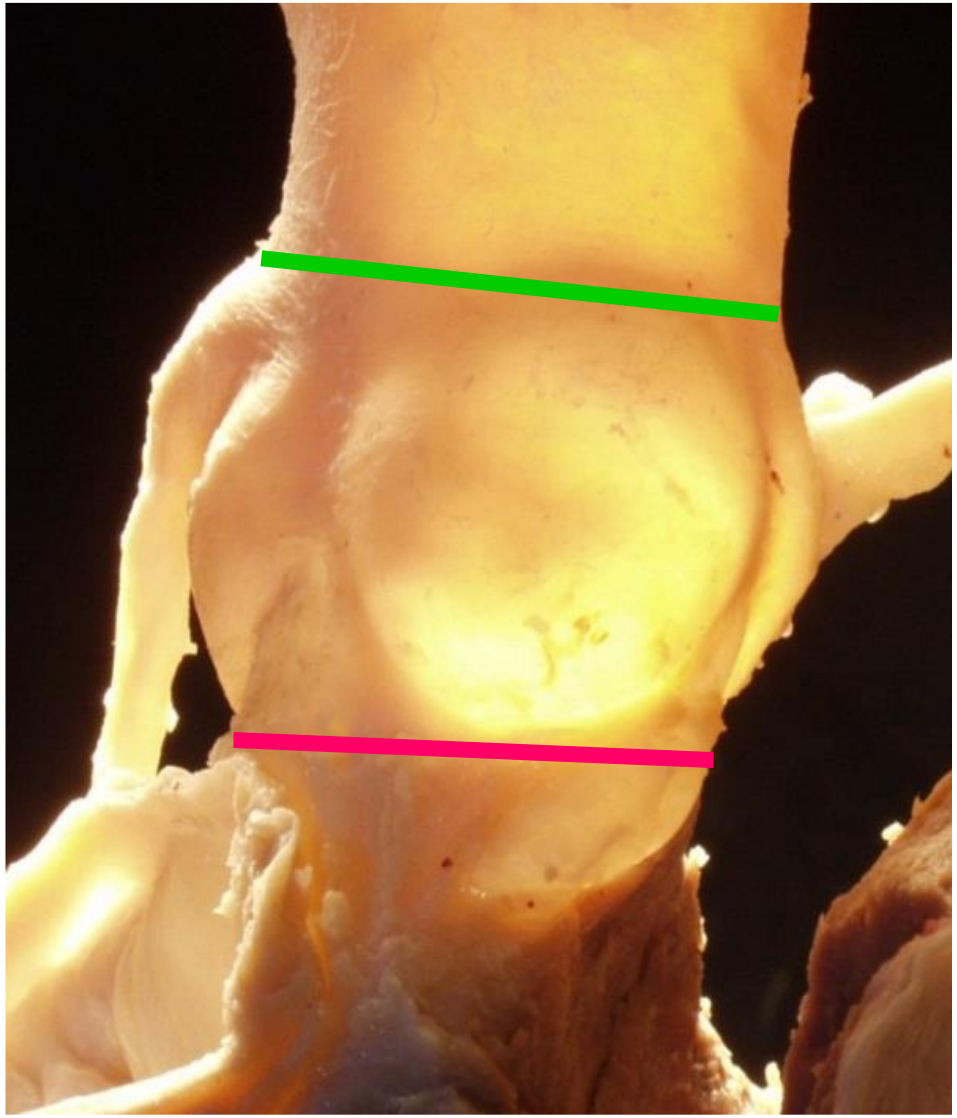

Sinotubular junction

Sinus of Valsalva

Ventriculoaortic junction

Aortic Root

≈ 3D AV annulus

Any AV repair for AR or Root dilatation must consider those three components

Physiopathology of AI: VAJ dilatation and AI

Table II. Degree of AR and aortic root size indexed by body surface area at follow-up study

	Mild AR (cm/m^2) (n = 67)	Moderate AR (cm/m^2) (n = 45)	Severe AR (cm/m^2) (n = 15)	p Value*
Aortic anulus	1.29 ± 0.23	1.38 ± 0.23	1.39 ± 0.11	0.055
Valsalva sinuses	1.89 ± 0.34	2.04 ± 0.31	2.09 ± 0.32	0.025
Supraaortic ridge	1.49 ± 0.30	1.71 ± 0.35	1.76 ± 0.43	0.001
Ascending aorta	1.97 ± 0.42	2.16 ± 0.49	2.19 ± 0.47	0.049

127 pts with chronic AR, 74% TAV, 16% BAV

Padial LR. Am. Heart. J. 1997

84 pts BAV with AR

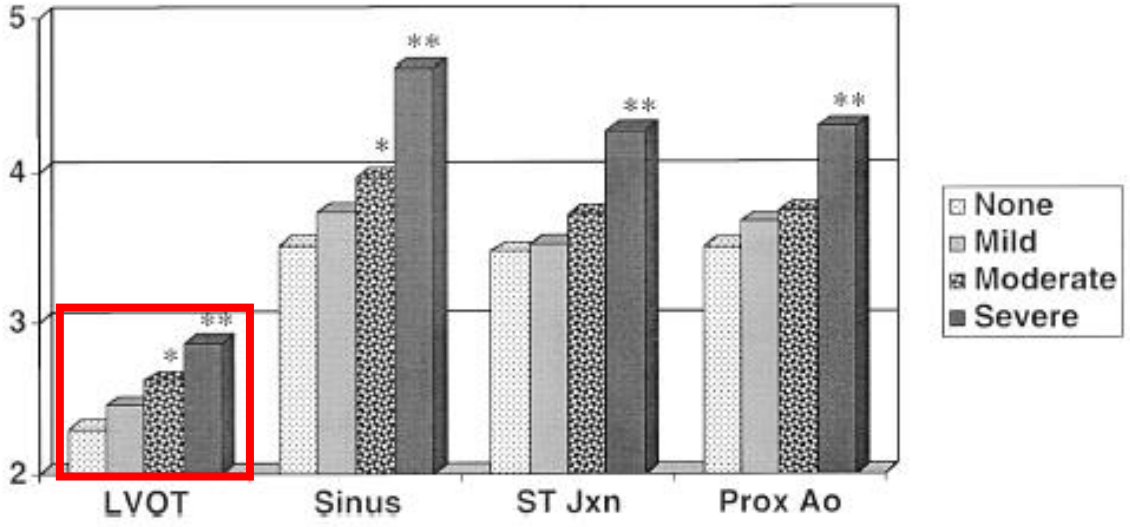

Keane M.G. Circulation. 2000

VAJ dilatation

Normal VAJ

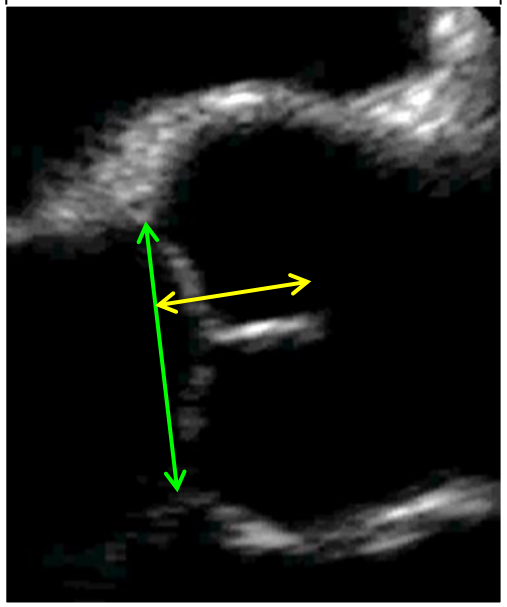

Dilated VAJ

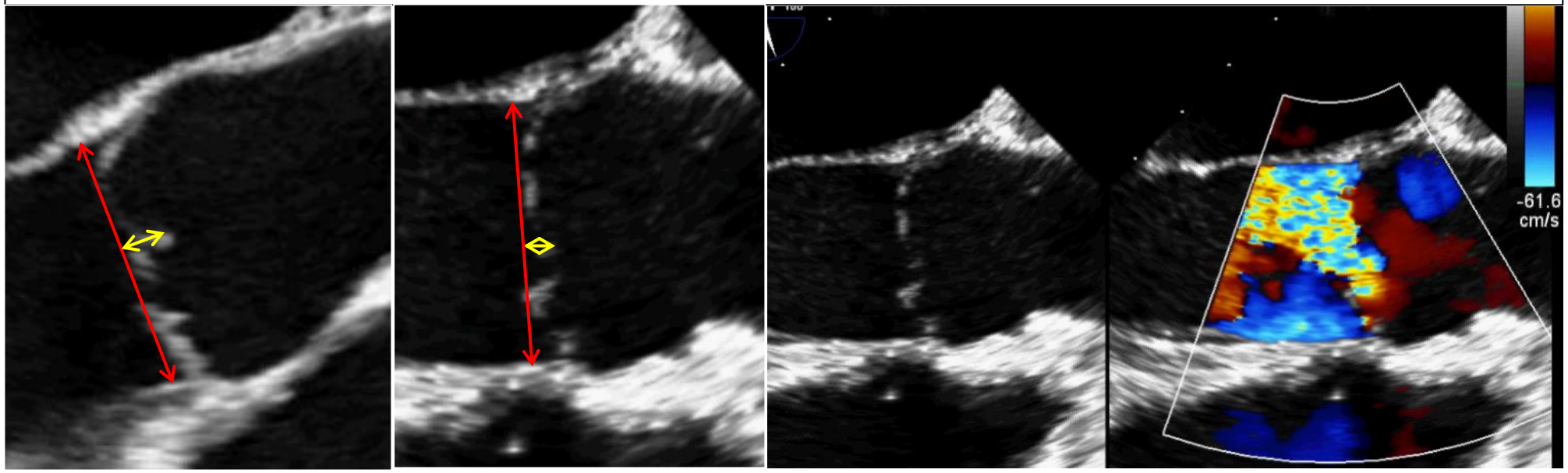

Mecanism of AI in VAJ dilatation

↑VAJ size → ↓↓ Coapt length ↓ Effective height → AI & Prolapse

↑ Stress

↑ free margin length
Rupture fenestration

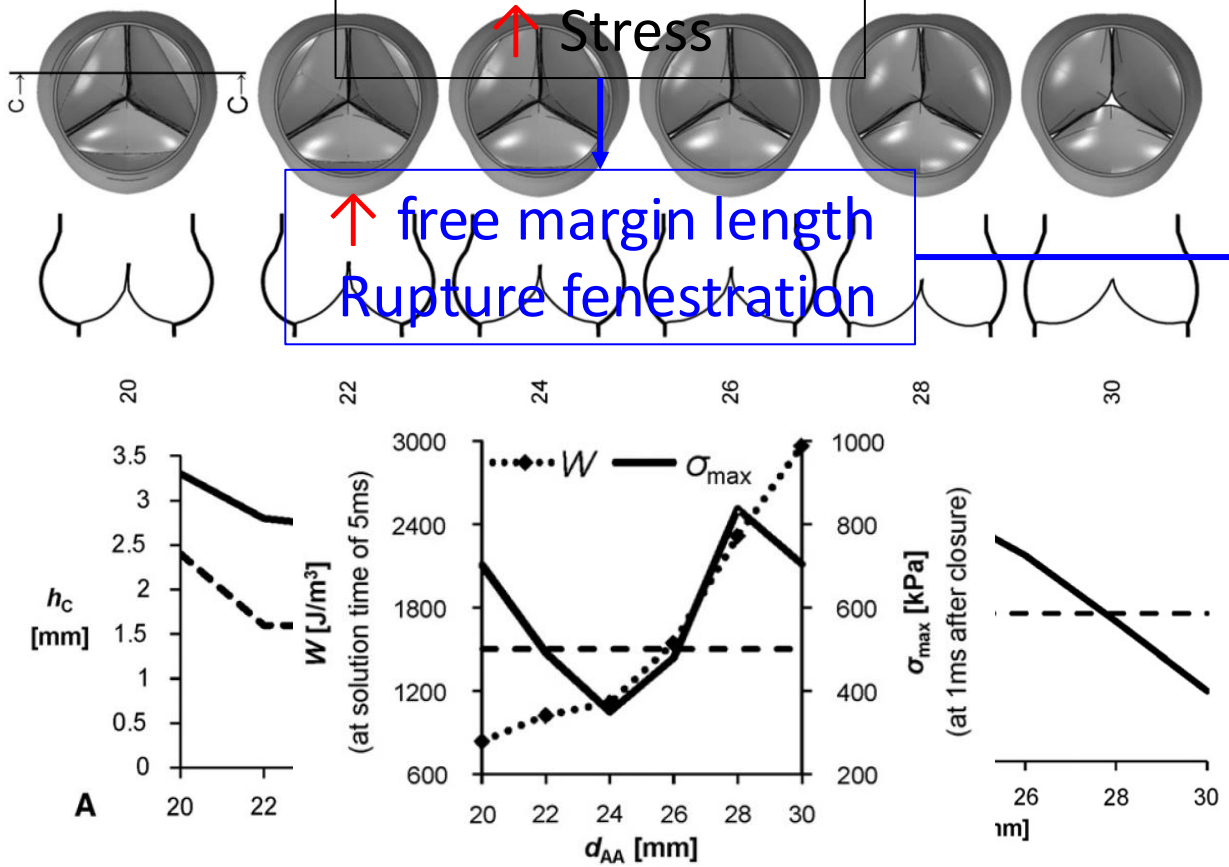

Marom G. JTCVS 2013

VAJ Size in Normal and Pathological Settings

	Normal TAV N=32	AI or aneurism TAV N=37	AI or aneurism BAV N= 27
2D echo	22.8 ± 2.4	26.1 ± 4.1[&]	30 ± 3.9[&$]
3D small Ø	21.8 ± 2.5	25.1 ± 4.7[&]	28.1 ± 3.5[&$]
3D long Ø	26.9 ± 2.2	27.6 ± 4.9	30.8 ± 4[&$]
Small/long ratio	0.8 ± 0.1	0.9 ± 0.1[&]	0.9 ± 0.1[&]

* $p < 0.05$ vs normal TAV; [&] $p < 0.001$ vs normal TAV; [$] $p < 0.001$ vs repaired TAV

	AI or aneurism TAV		AI or aneurism BAV	
	AI ≤ 1	**AI ≥ 2**	**AI ≤ 1**	**AI ≥ 2**
2D echo	23.4 ± 2.5	27.2 ± 3.9*	26.6 ± 2.6*	31.3 ± 3.8[$&]
3D small Ø	22.5 ± 3.4	26.1 ±4.5*	25.3 ± 2.4	29.2 ± 3.3[$&]
3D long Ø	25.4 ± 3.8	28.3 ± 4.8	27.8 ± 1.7	32.1 ± 4.3[$&]
Small/long ratio	0.9 ± 0.1	0.9 ± 0.1	0.9 ± 0.1	0.9 ± 0.1

* $p < 0.05$ vs TAV without AR; [$] $p < 0.05$ vs TAV with significant AR; [&] $p < 0.05$ vs BAV without AR

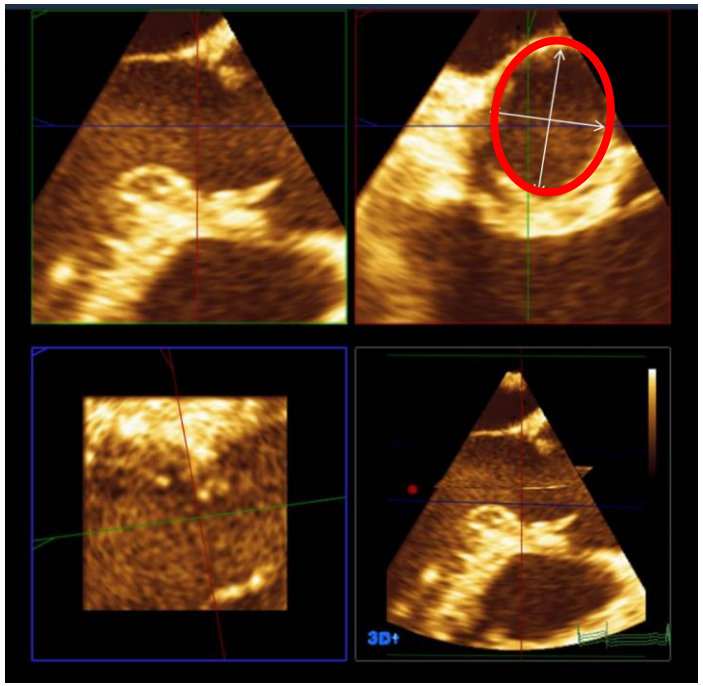

Ratio 0,8

Watremez C., Anesth., Clin. Univ. St-Luc, Brussels, unpublished data

VAJ Annuloplasty Techniques

Circumclusion

Taylor 1958, Carpentier 1990

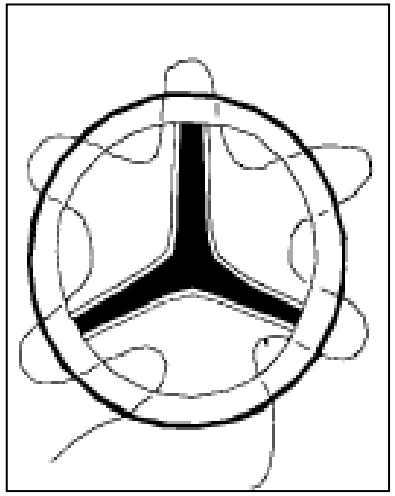

Commissural annoplasty

C. Cabrol 1966

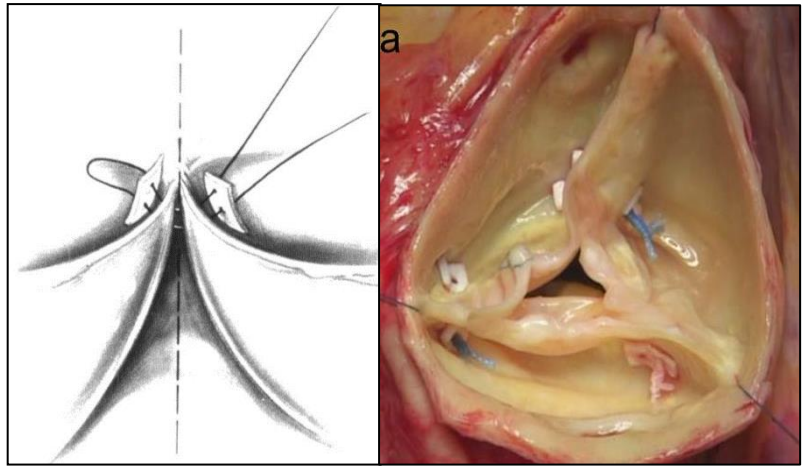

Reimplantation

T. David 1992

Partial external band

T. David 1996

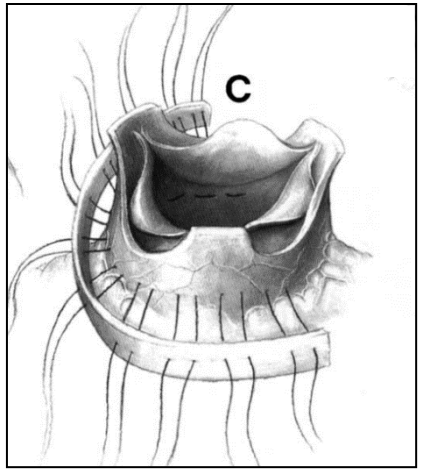

External Ring

E. Lansac 2006

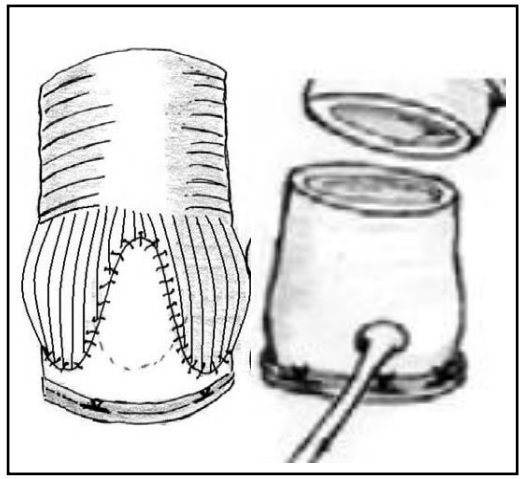

Suture Annuloplasty

H-J. Schäfers 2013

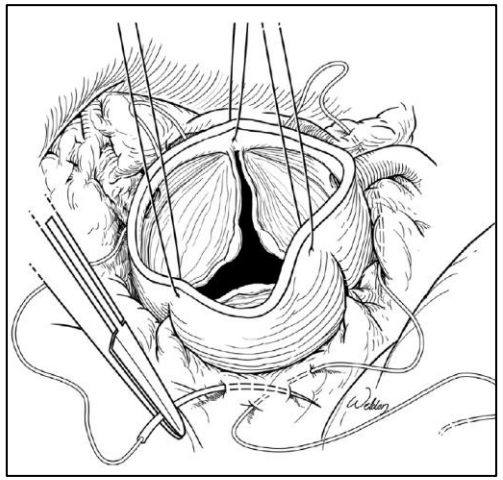

Internal Rigid Ring

J.S. Rankin 2012

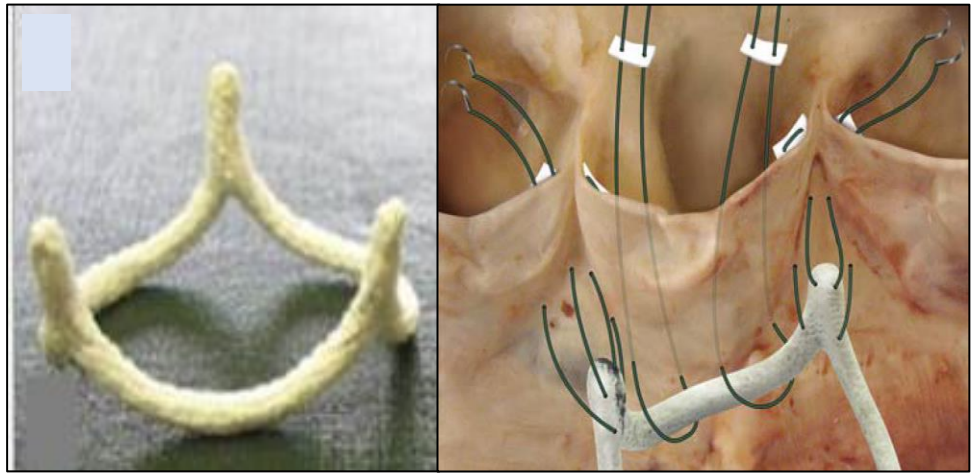

Effect of VAJ Annuloplasty on Coaptation

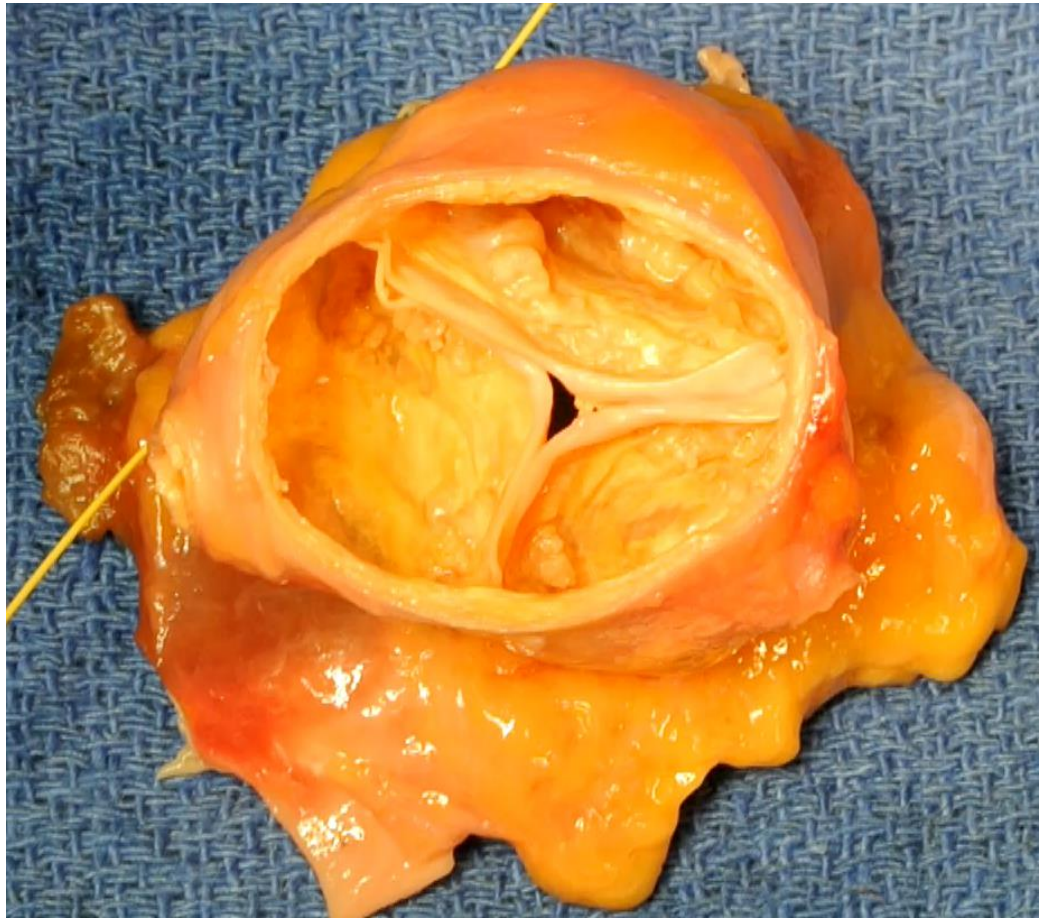

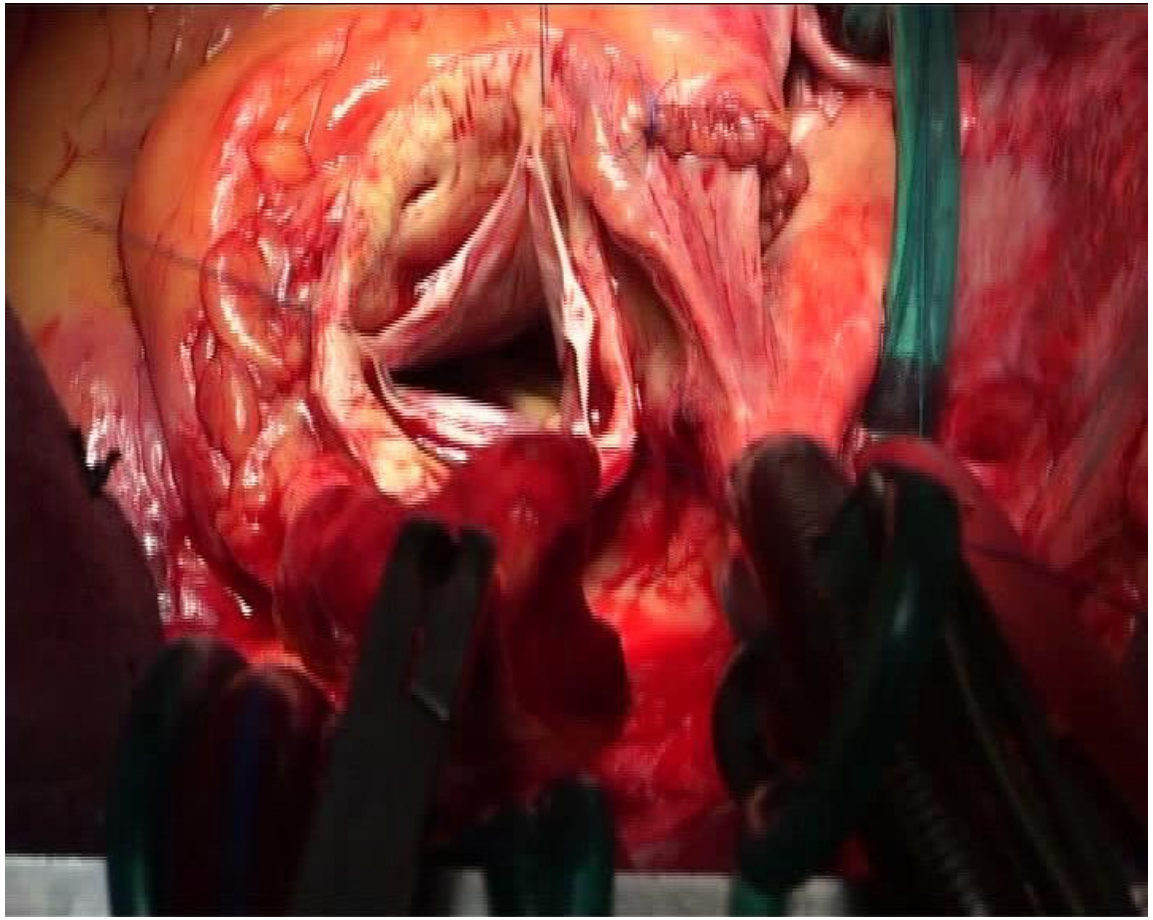

Increases coaptation length and surface (not the effective height!)

Functional Classification of AI

AI Class	Type I Normal cusp motion with FAA dilatation or cusp perforation				Type II Cusp Prolapse	Type III Cusp Restriction
	Ia	Ib	Ic	Id		
Mechanism	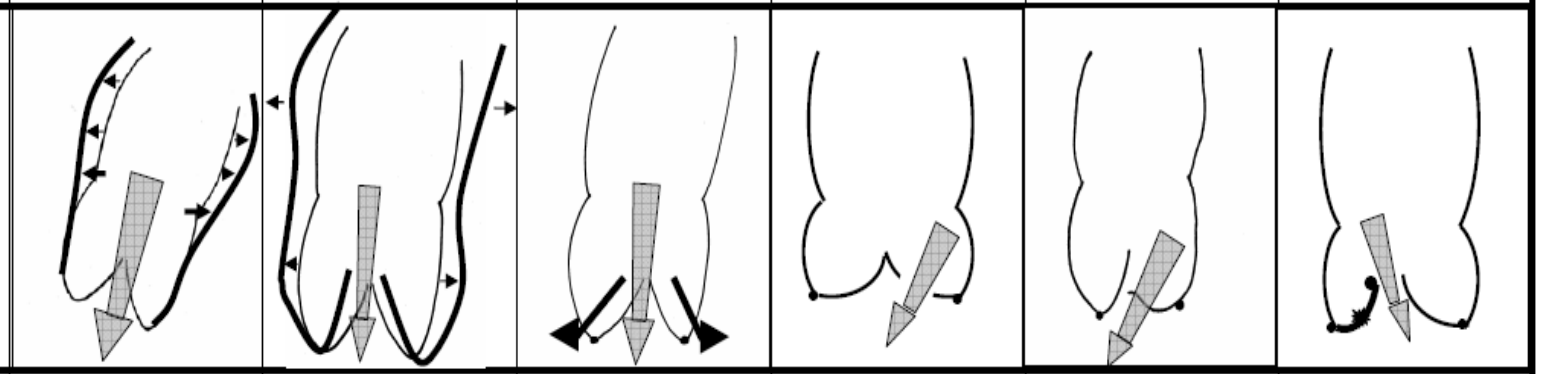					
Repair Techniques (Primary)	STJ remodeling *Ascending aortic graft*	Aortic Valve sparing: *Reimplantation or Remodeling with SCA*	SCA	Patch Repair *Autologous or bovine pericardium*	Prolapse Repair *Plication* *Triangular resection* *Free margin Resuspension* *Patch*	Leaflet Repair *Shaving* *Decalcification* *Patch*
Anulopl.	SCA	VSReimpl.	STJ Annuloplasty	SCA	SCA	SCA

El Khoury G.
Cur. Op. Card. 2005

Functional Classification of AI

Root <45mm

SCA:

Root >45mm

VSR:

TAV

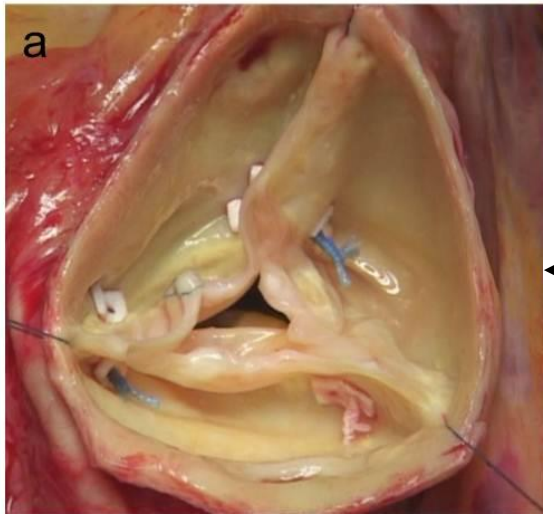

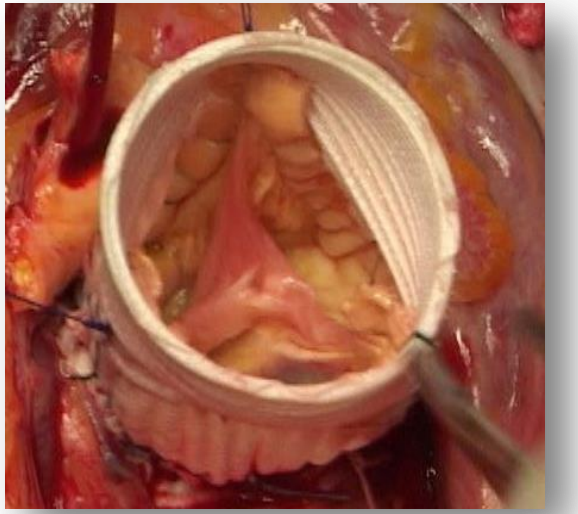

BAV

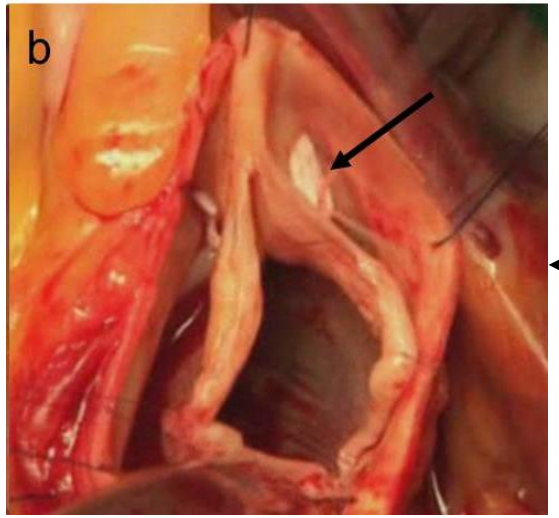

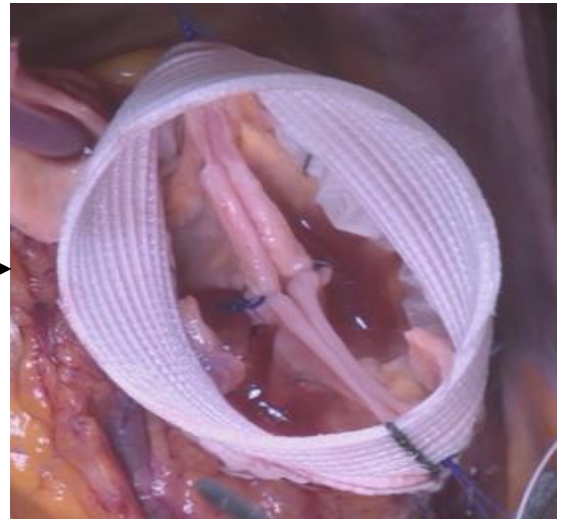

Systematic Anuloplasty !

Brussels AV repair: ***Fate of SCA*** – *Acute complication*

Cusp perforation !

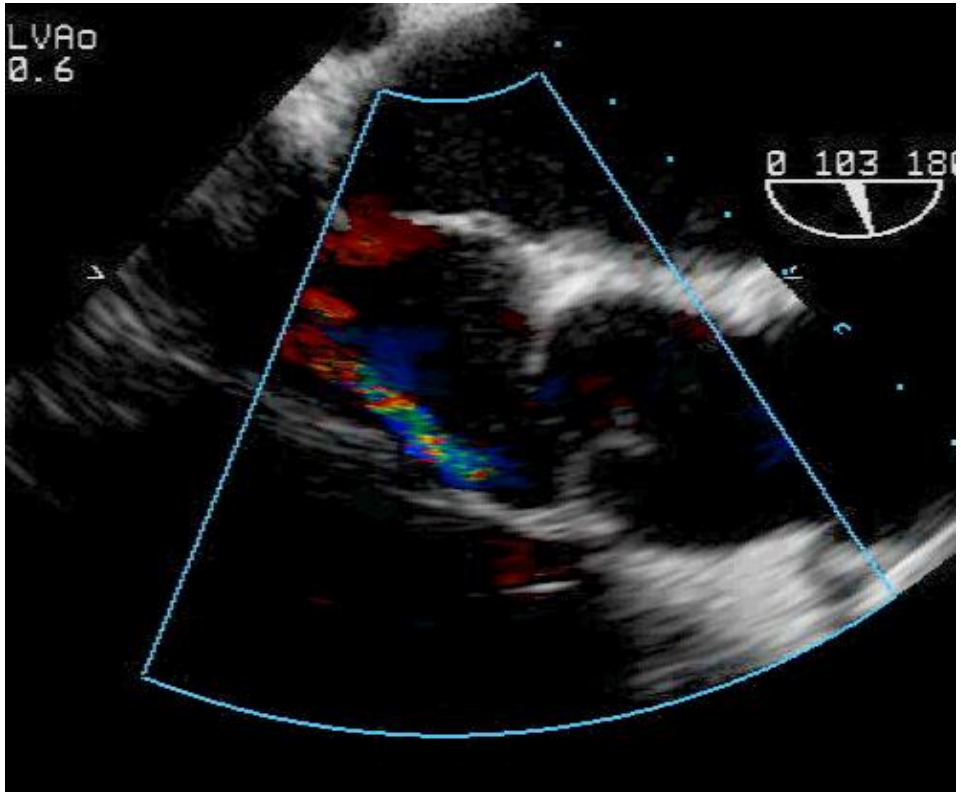

Fistula Aorta – RV !

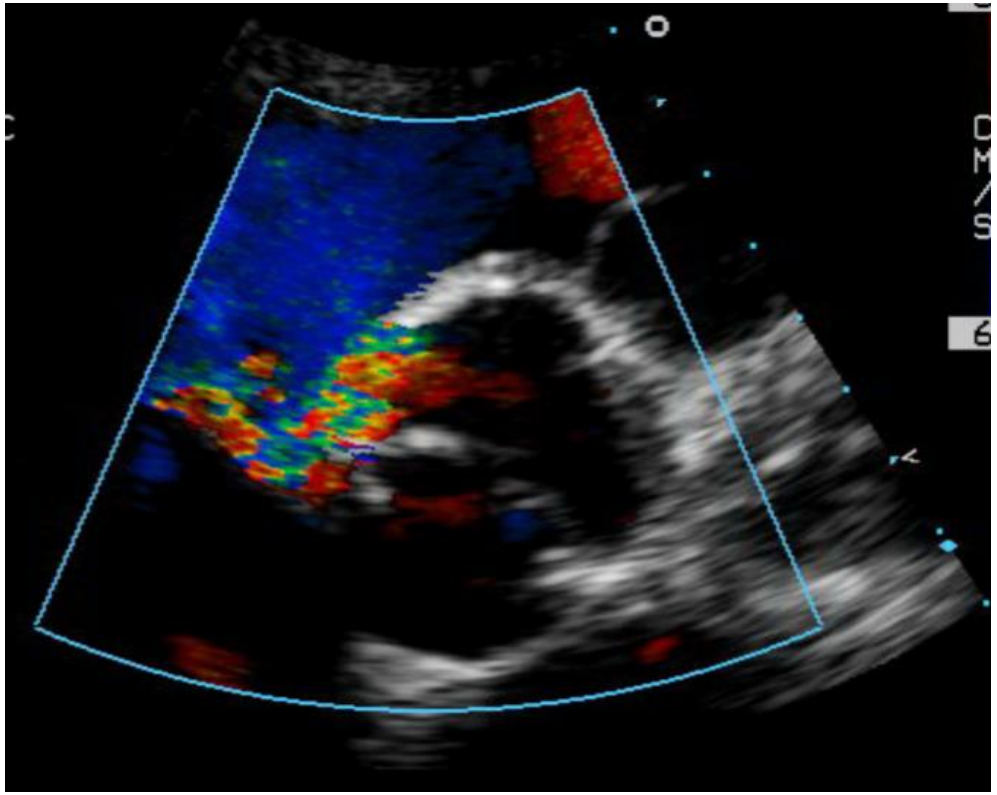

Brussels AV repair: *Results of BAV repair*

TABLE E1. Early and late aortic valve reoperations

Year	Interval	Valve type	Aortic root intervention	Raphé repair	Other cusp repair technique(s)	Failure mode	Mechanism of failure	Type of AV reoperation
Early AV reoperations								
1997	day 7	1	SCA	Direct suture	FMP	AI	Suture dehiscence	Re-repair
1998	day 12	0	Remodeling; SCA	—	FMP	AI	Cusp prolapse	Ross procedure
1998	day 6	0	SCA	—	Patch on perforation	AI	Coaptation defect	Ross procedure
2006	day 10	1	SCA	Shaving	FMP; FMR	Fistula	Aorta–right ventricle fistula	Re-repair
2008	day 6	1	SCA	Shaving	FMP; direct suture of perforation	AI	Suture dehiscence	Re-repair
Late AV reoperations								
1996	8 y	1	AA replacement	Direct suture	Decalcification	AS	Calcification	Bioprosthesis
2000	7 y	1	SCA	Shaving	FMP; FMR	AI+AS	Cusp prolapse, calcification	Bioprosthesis
2001	2 y	1	SCA	Patch*	—	AI	Cusp prolapse	Ross procedure
2002	6 y	1	SCA	Direct suture	FMR	AI	Cusp prolapse (PTFE rupture), calcification	Ross procedure
2002	6.5 y	0	Remodeling; SCA	—	FMP	AI	Endocarditis	Re-repair
2002	6.5 y	1	SCA	Direct suture	FMR	AI	Cusp prolapse	Re-repair
2007	2 y	0	SCA	—	FMP; FMR; patch on perforation	AI	Cusp prolapse	Bioprosthesis

SCA, Subcommissural annuloplasty; *AA*, ascending aorta; *AI*, aortic insufficiency; *AV*, aortic valve; *AS*, aortic stenosis; *PTFE*, polytetrafluoroethylene; *FMP*, free margin plication; *FMR*, free margin resuspension (with 7-0 PTFE). *Tricuspid valve autograft patch was used in this patient.

3/4 Recurrent Regurgitation !

(prolapse)

M. Boodhwani et al. J Thorac Cardiovasc. Surg. 2010;140:276-84

Brussels AV repair: *Results of BAV repair*

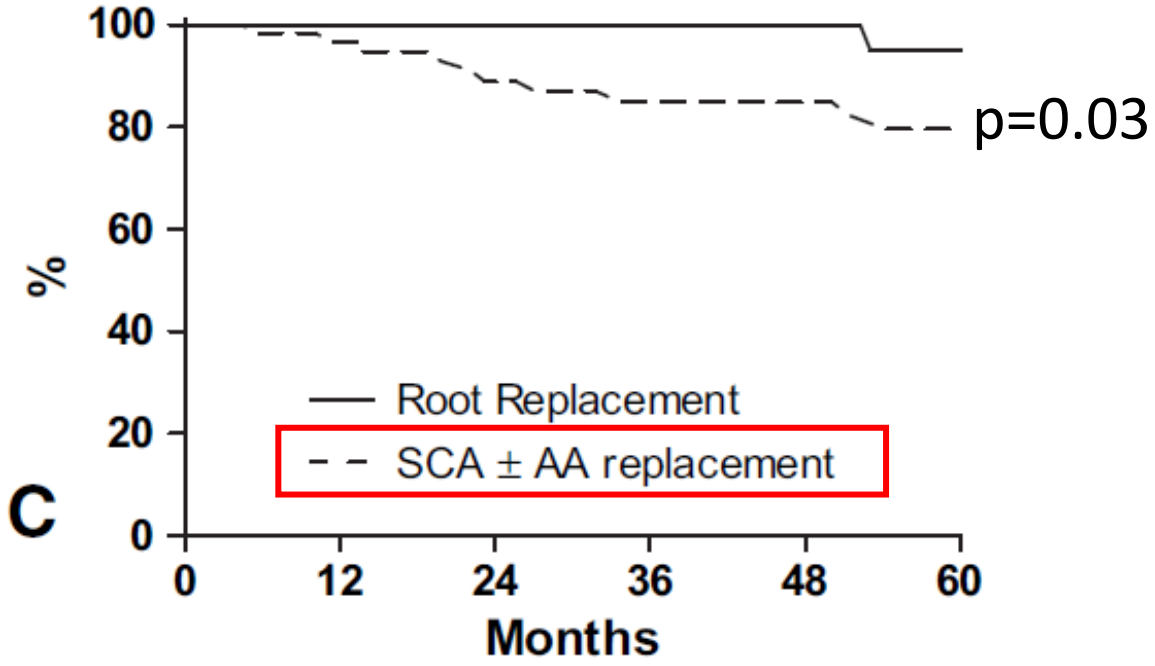

No. at risk							
Root Rep	52	47	40	32	26	20	13
SCA ± AA	65	56	47	39	35	26	20

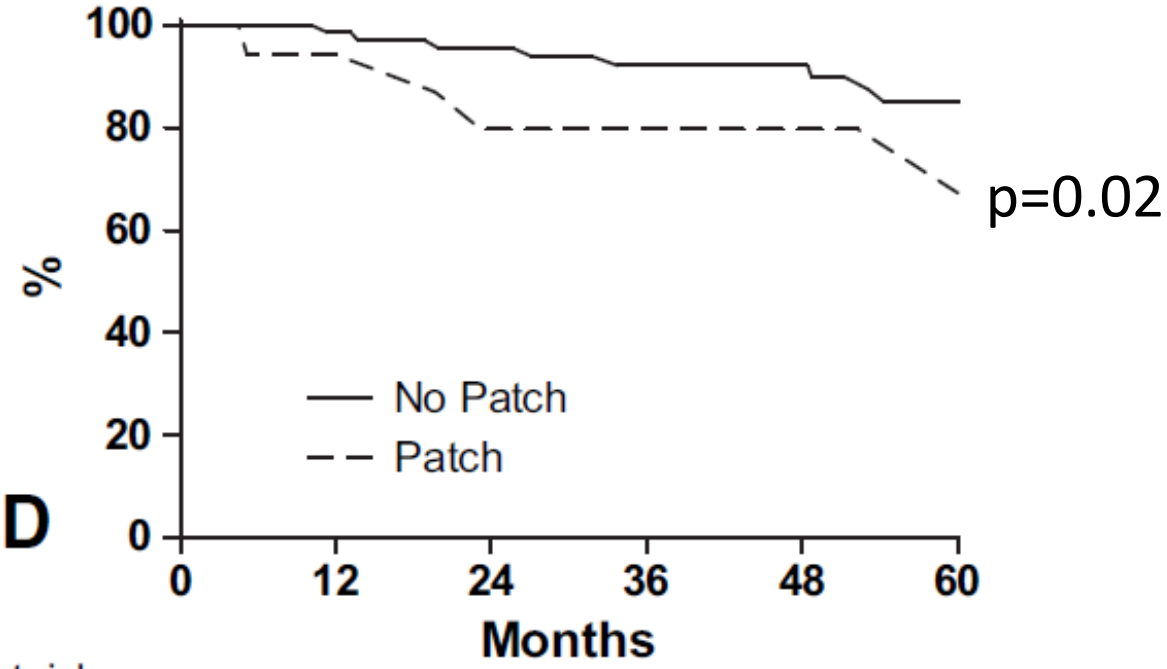

No. at risk						
Patch	19	14	12	10	9	6
No Patch	77	71	62	50	43	31

M. Boodhwani et al. J Thorac Cardiovasc. Surg. 2010;140:276-84

Rate of VS Reimplantation over year at St-Luc, Brussels

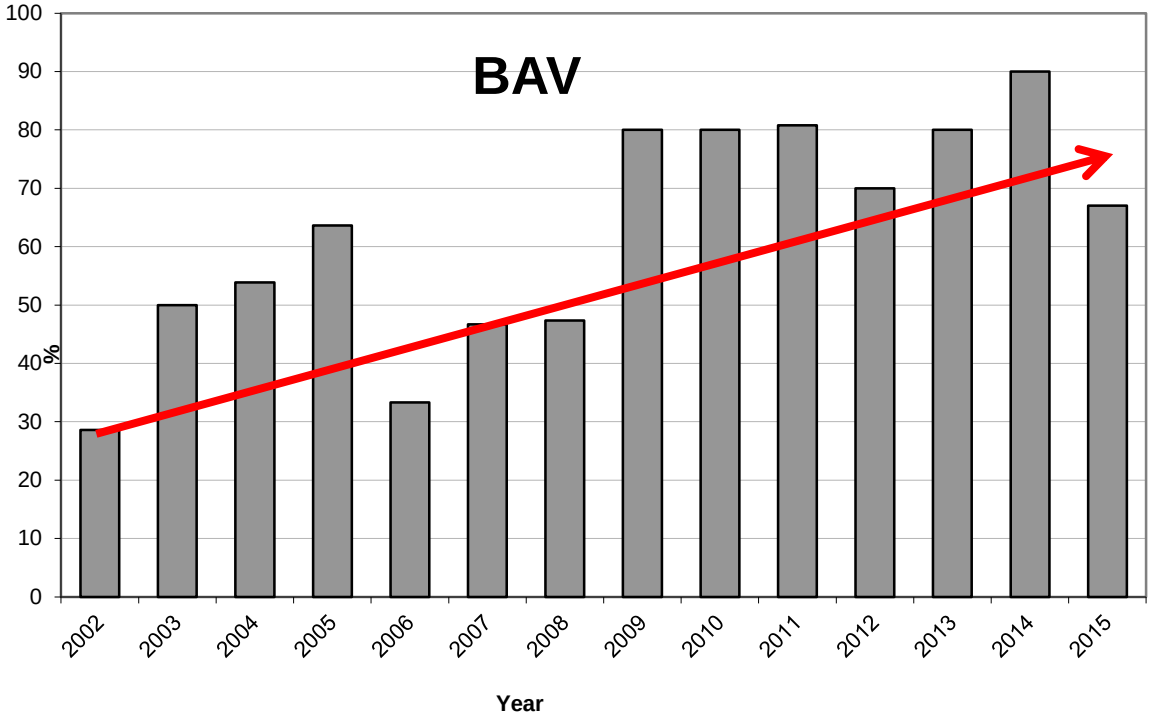

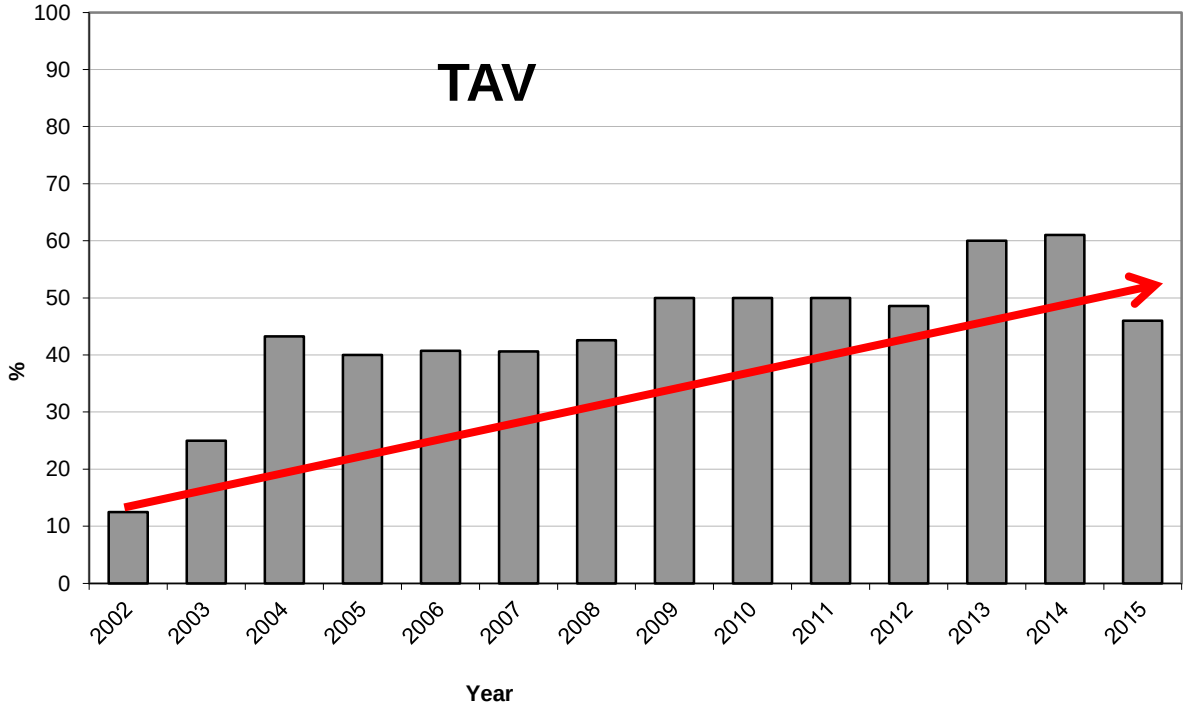

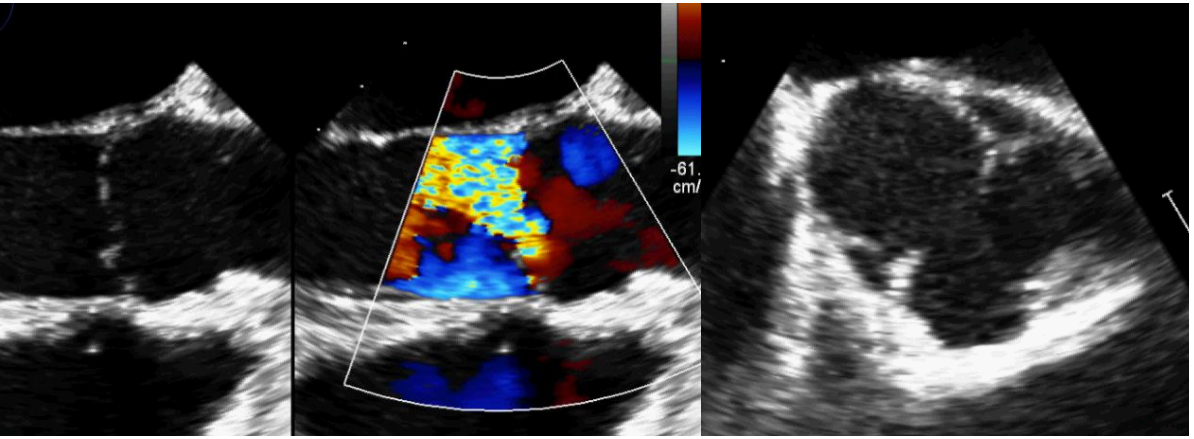

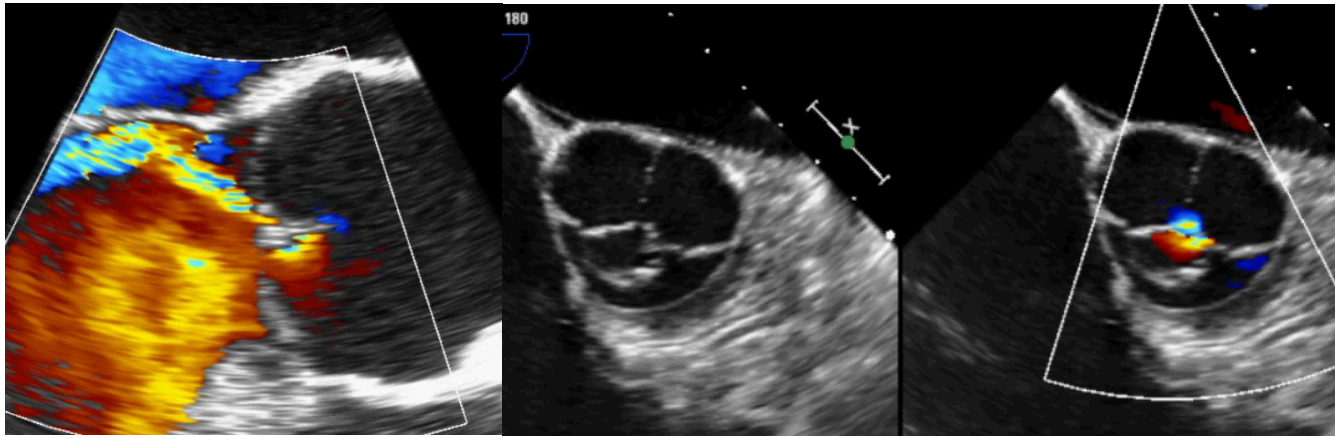

Role of VAJ size and annuloplasty in AV repair

- SCA technique

BAV

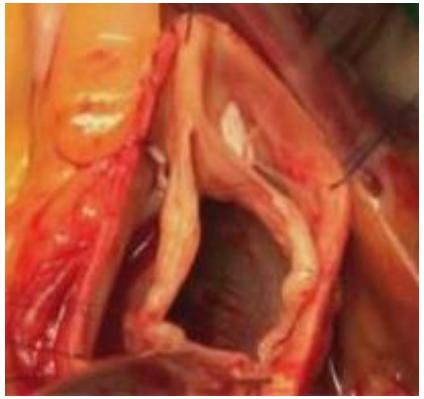

FF AR >1+

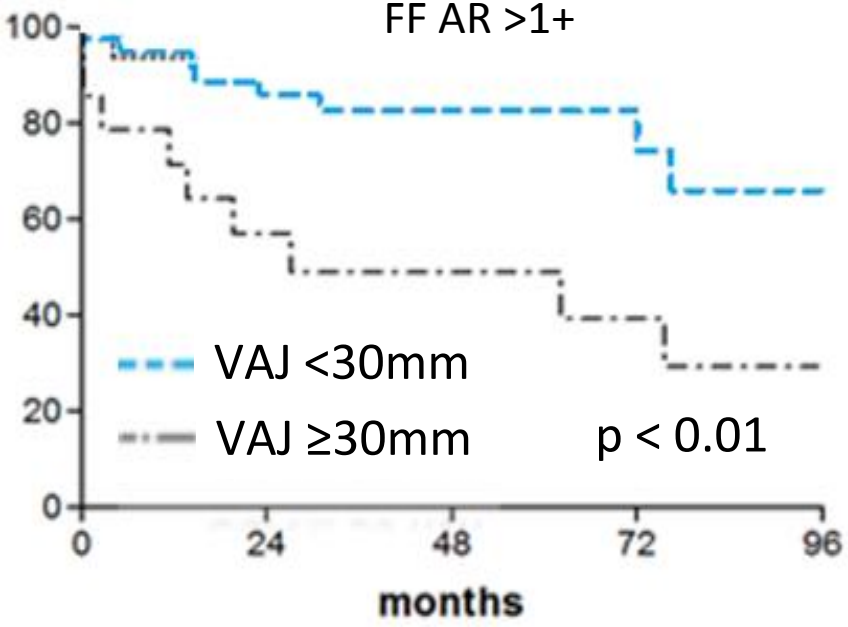

Navarra E. EJCTS 2013

TAV

FF AR >1+

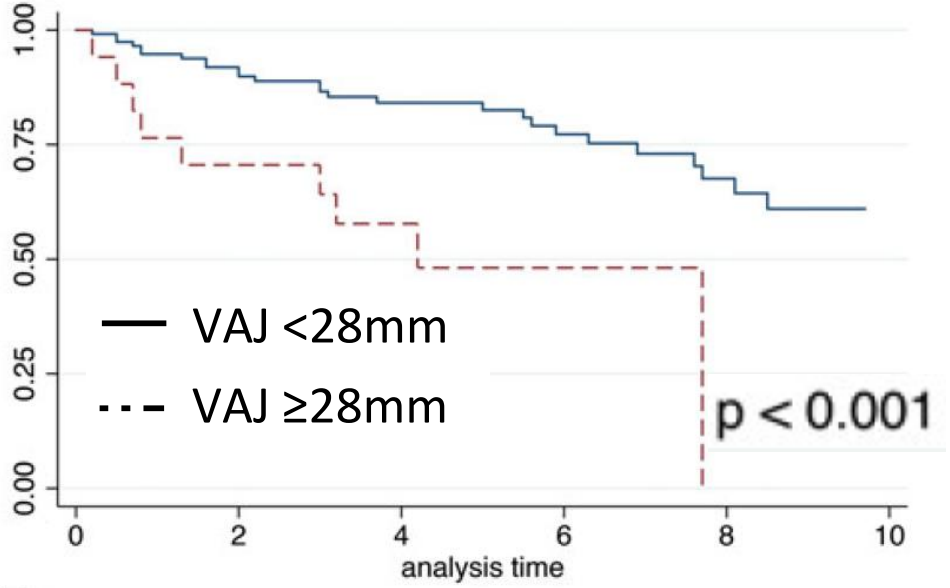

De Kerchove L. EJCTS 2015

Effect of VAJ size on AV repair durability

✓ *Hanke T., Sievers H.J. JTCVS 2009:*

- 191 VSRR, 76% TAV
- 56% Remodeling

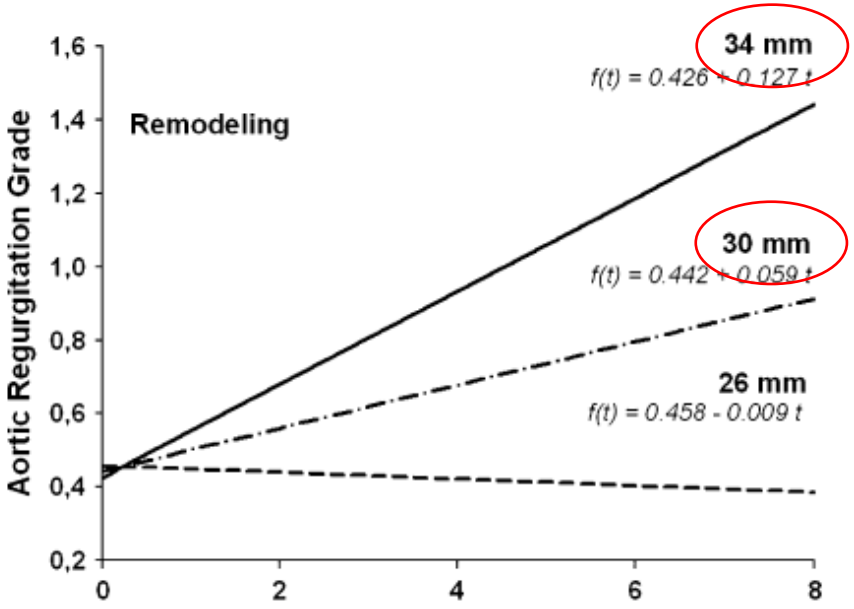

✓ *Kunihara T., Schäfers H.J. JTCVS 2012:*

- 430 VSRR, 70% TAV,
- 93% remodeling

✓ *Schäfers H.J. JTCVS 2016:*

- 747 Remodeling, 58% TAV,

TABLE 2. Risk factors by multivariate Cox regression analysis (−2 log-likelihood function = 161.87, chi-square = 72.79, $P < .001$)

Variable	*P* value	HR	95% CI
Diameter of AV junction (mm)	<.001	1.43	1.21-1.69
Use of annuloplasty	.01	1.28	1.89-66.26
Myocardial ischemia (min)	.04	0.96	0.93-1.00
Effective height	<.001	0.58	0.43-0.79
Use of pericardial patch	<.001	6.24	2.30-16.90

AV, Aortoventricular; *CI*, confidence interval; *HR*, hazard ratio.

Role of VAJ size and annuloplasty in AV repair

- VSR technique

BAV

(Hospit. mortality: 0%)

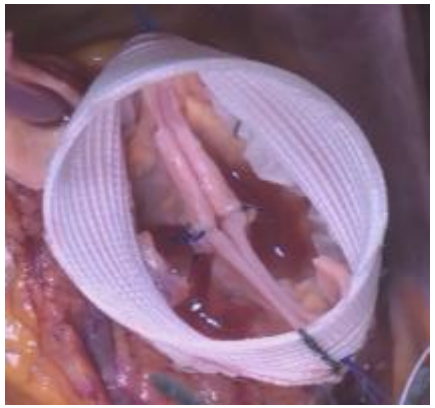

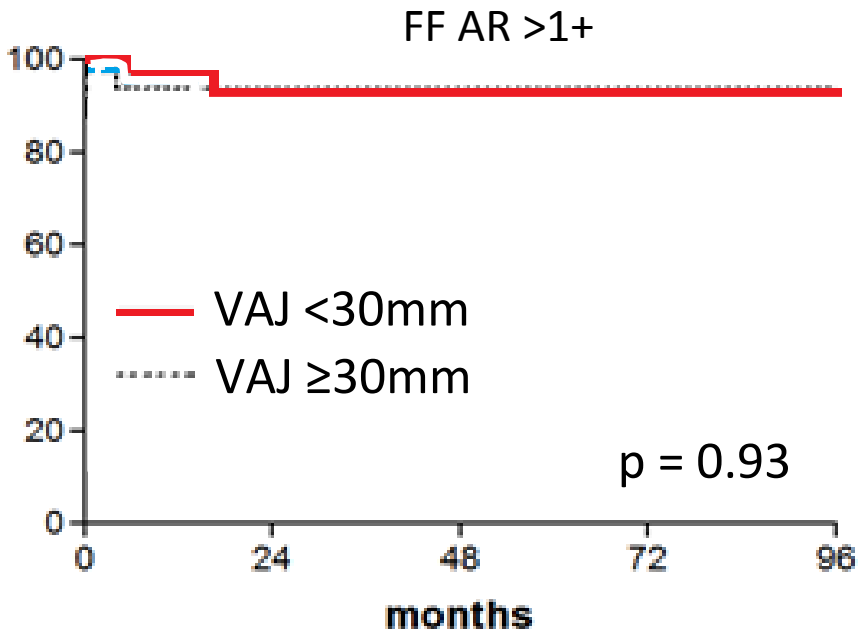

Navarra E. EJCTS 2013

TAV

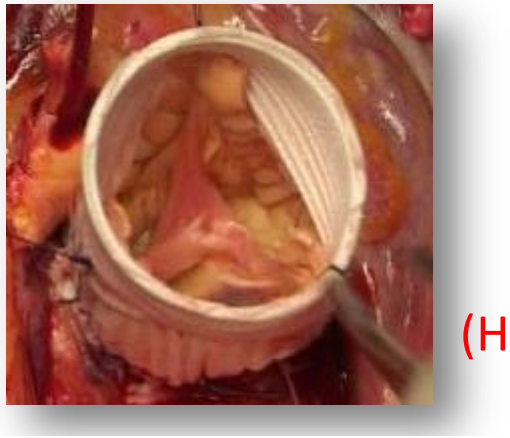

(Hospit. mortality: 0.6%)

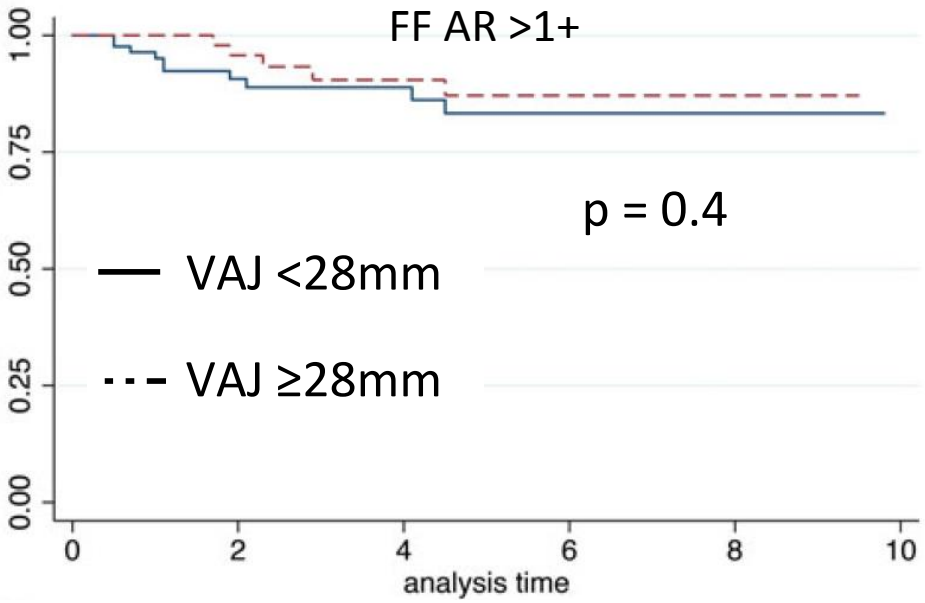

De Kerchove L. EJCTS 2015

Role of VAJ size and annuloplasty in AV repair

- SCA versus VSR technique (matched groups)

BAV

FF AR >1+

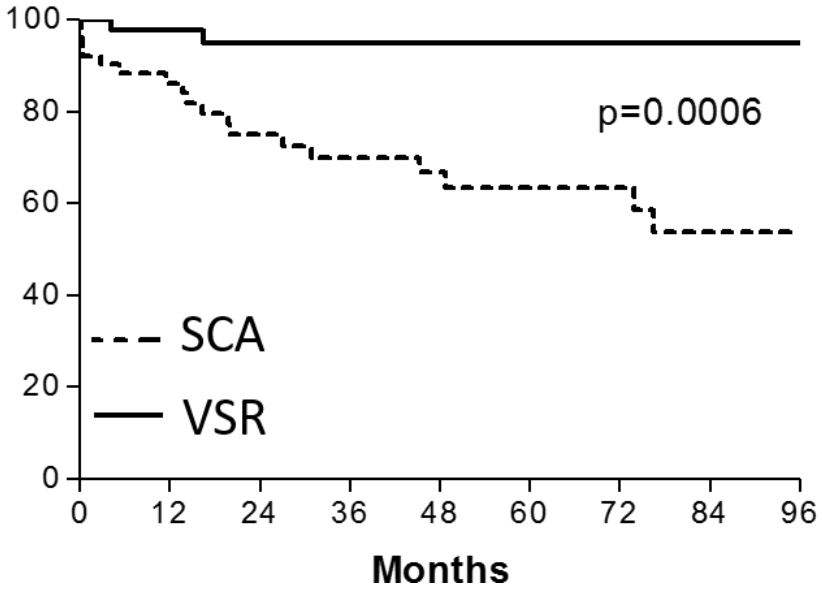

De Kerchove L. JTCS 2010

TAV

FF AR >1+

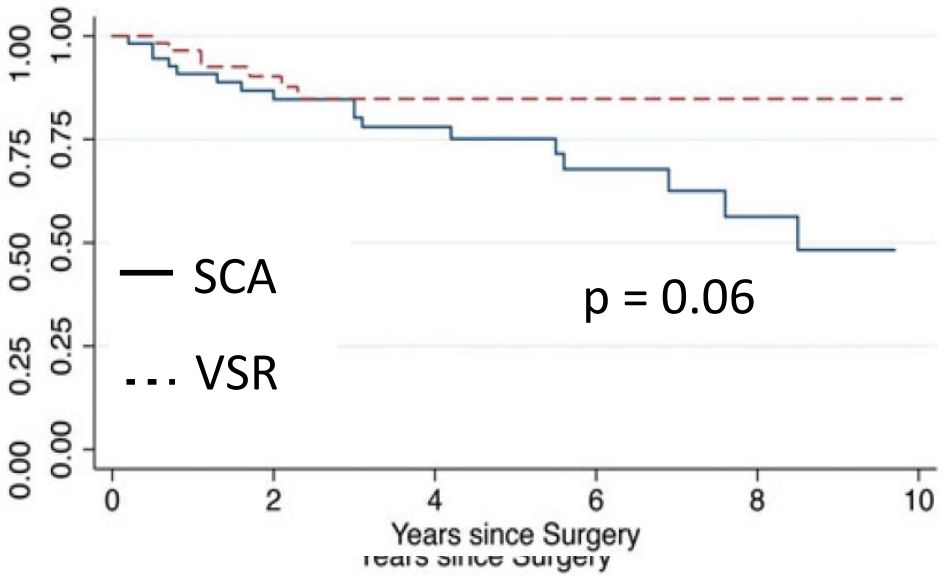

De Kerchove L. EJCTS 2015

VAJ size after SCA

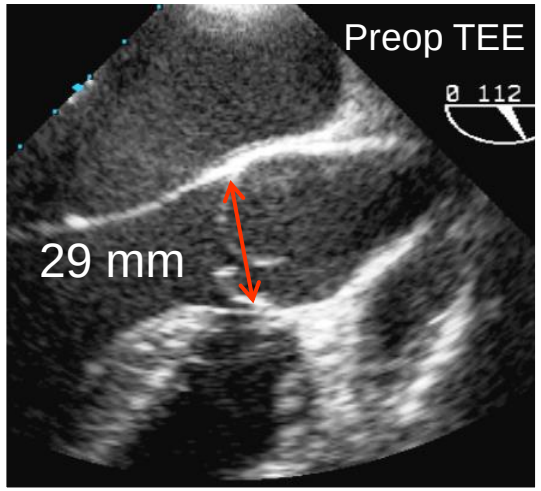

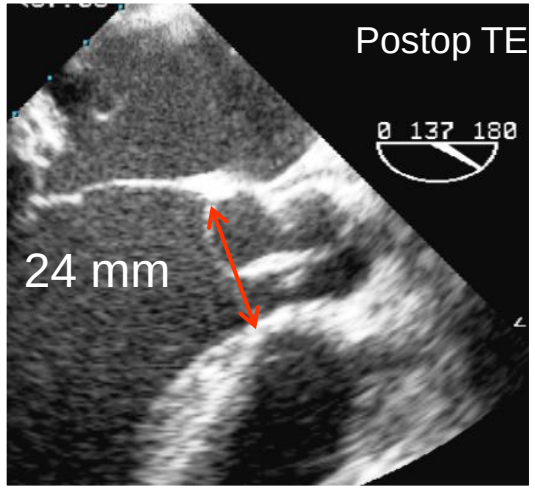

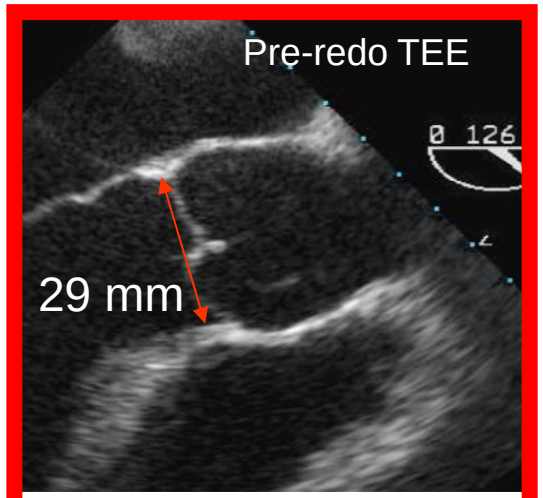

30 y♂: **BAV**, rapher res+direct closure, cusps resusp (Gtx), SCA

→ 6.5 y later: AI 3+

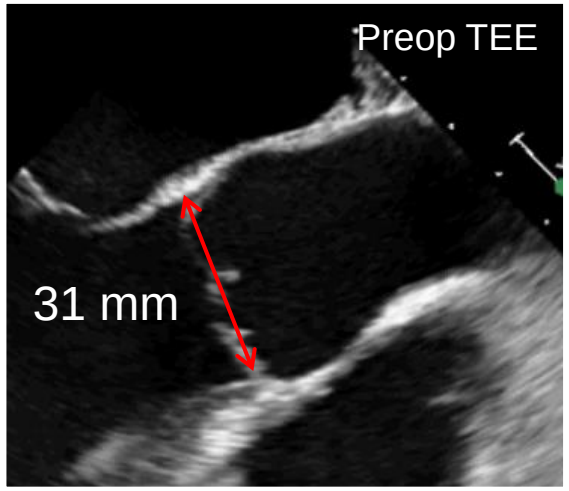

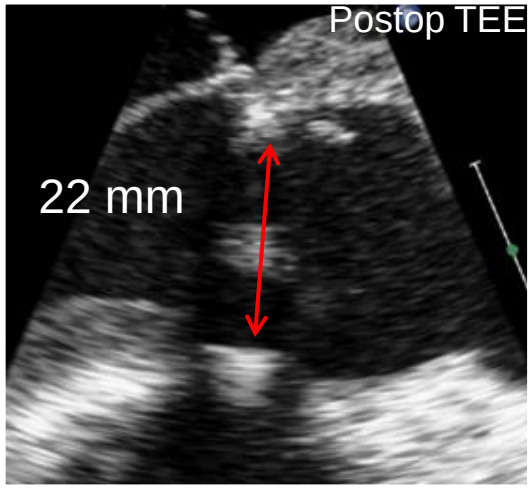

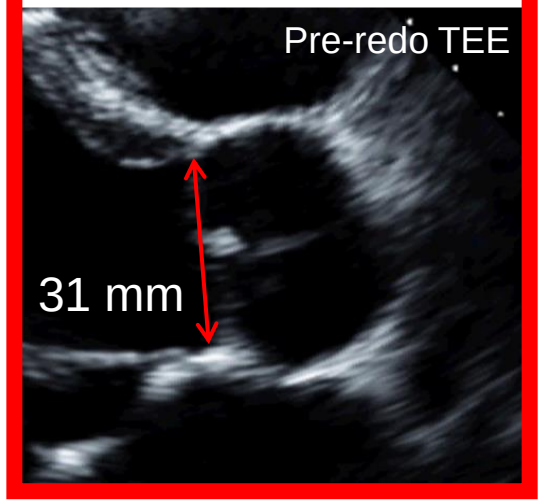

41 y ♂: **TAV**, RC plication and resuspension (Gtx), SCA

→ 2 y later : AI 3+

Recurrent VAJ dilatation !

VAJ dilatation occurs in most patients with SCA in TAV repair

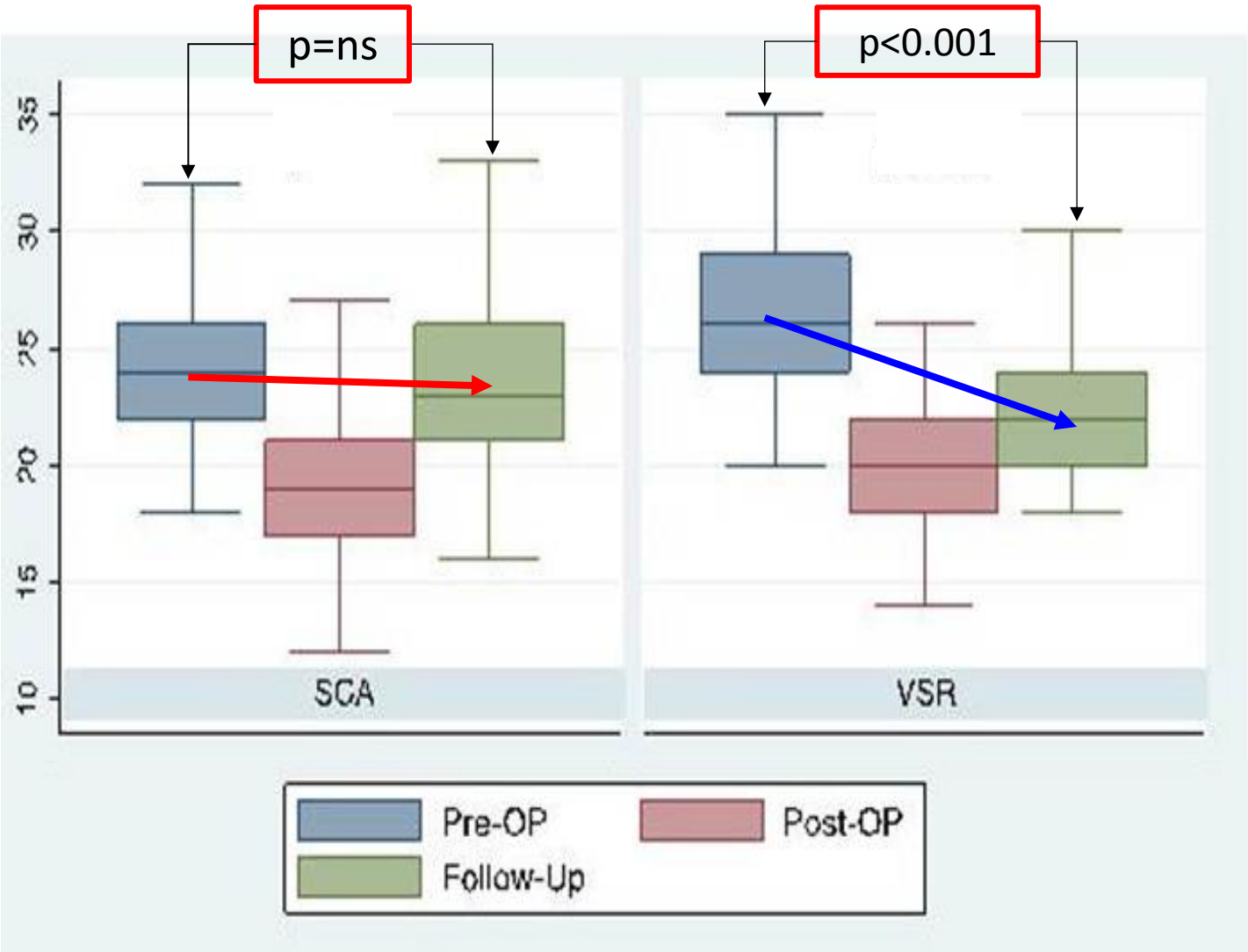

De Kerchove L. EJCTS 2015

Brussels AV repair: *Why is VSR so efficient?*

1. Circumferential prosthetic annuloplasty → **Stable over time**
2. Remodel BAV geometry to 180°
3. Optimal Coaptation

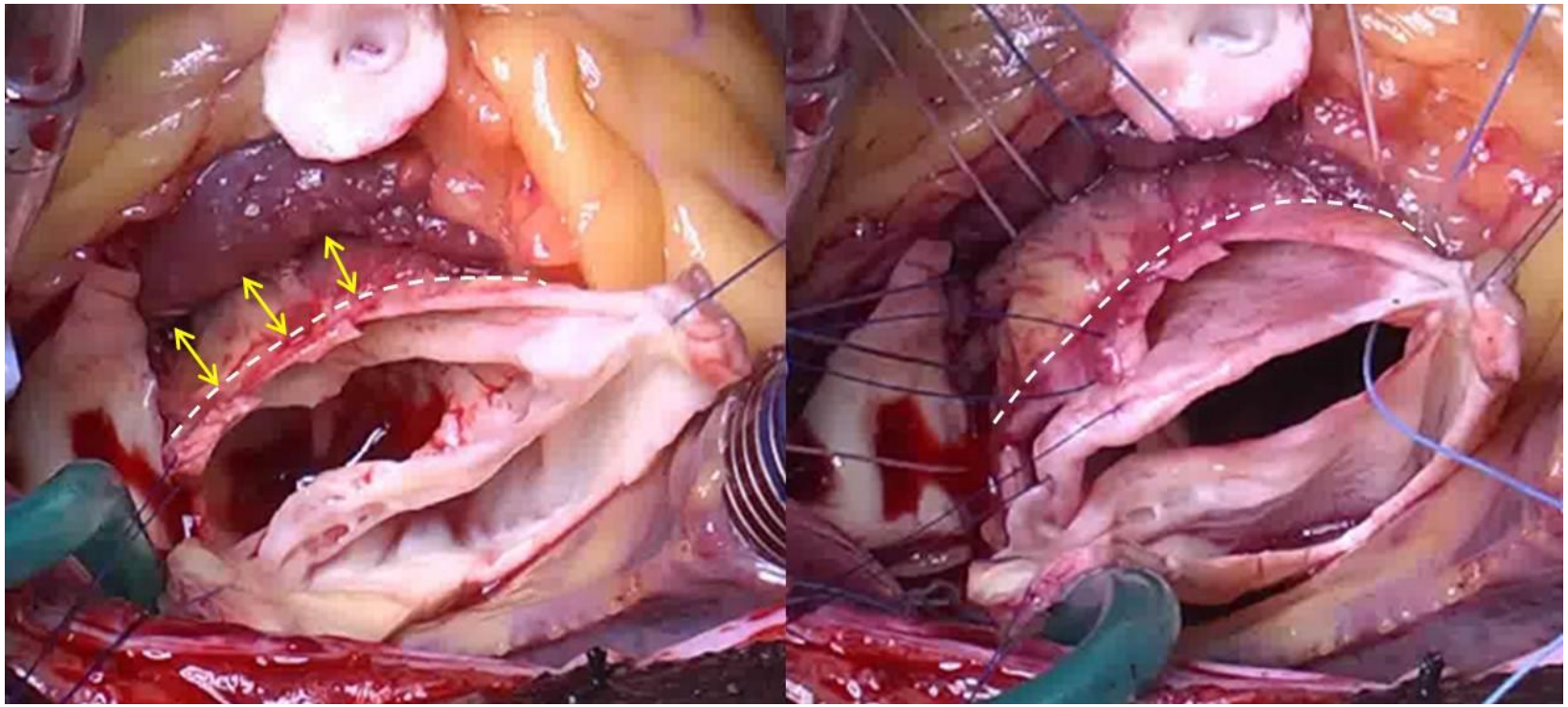

Brussels AV repair: ***Why is VSR so efficient?***

1. Circumferential prosthetic annuloplasty → **Stable over time**
2. Remodel BAV geometry to 180°
3. Optimal Coaptation

"Assymetric annuloplasty"

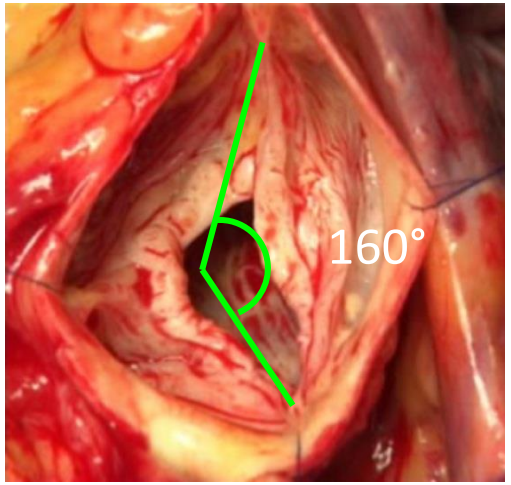

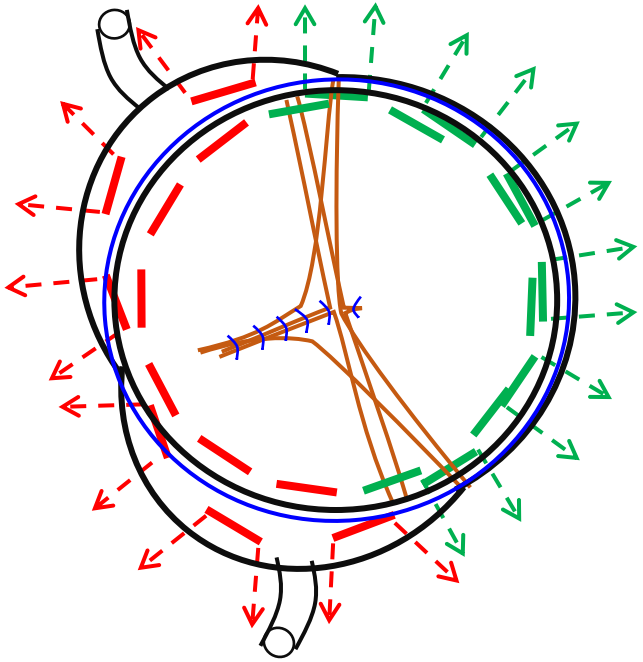

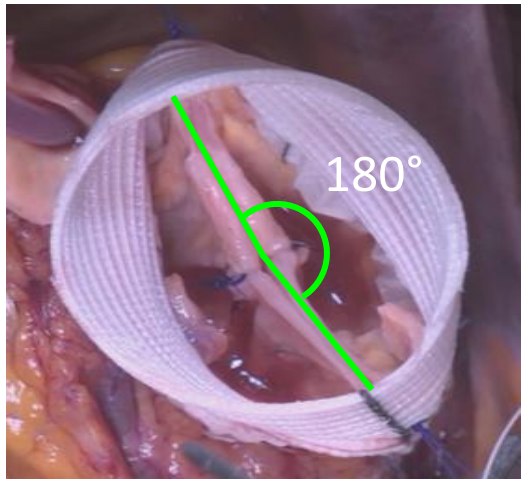

Brussels AV repair: *Why is VSR so efficient?*

1. Circumferential prosthetic annuloplasty → **Stable over time**
2. Remodel BAV geometry to 180° → **Durable configuration**
3. Optimal Coaptation

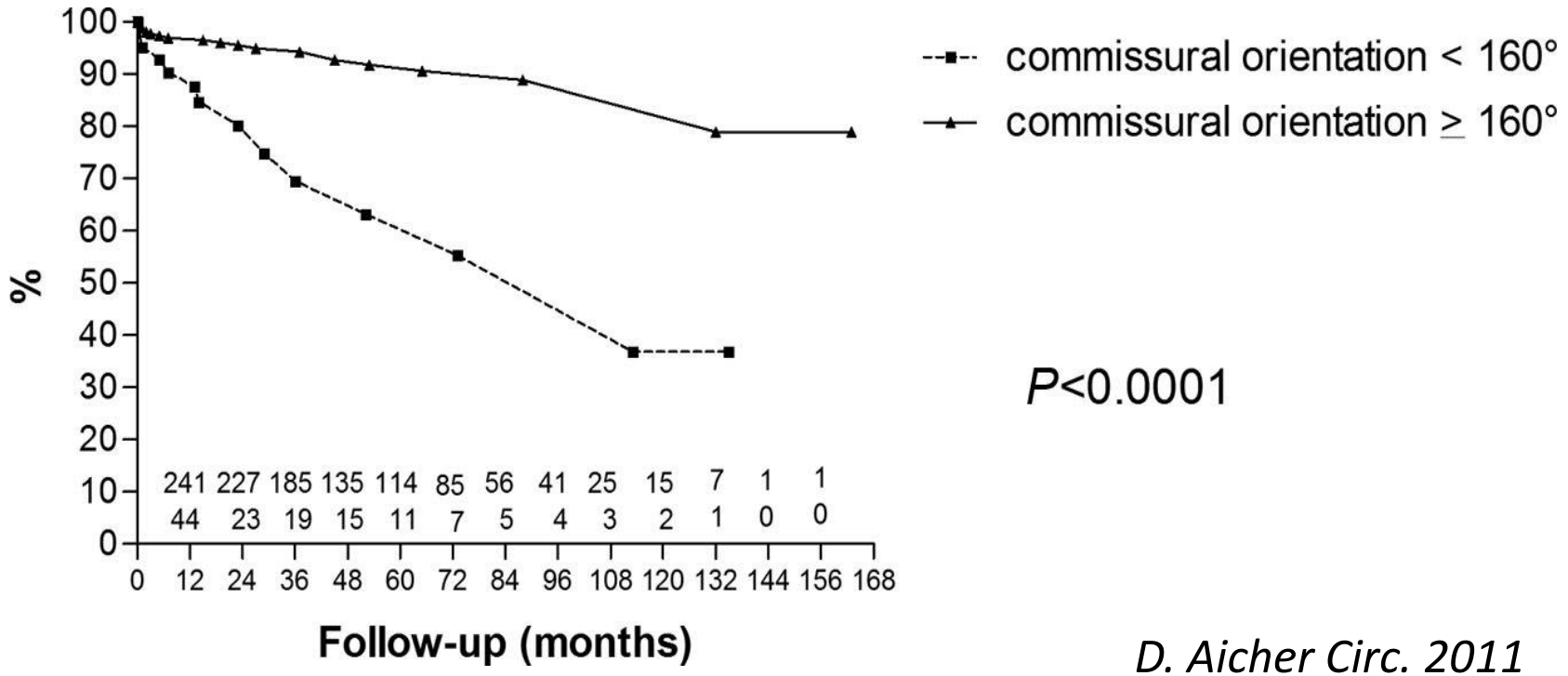

D. Aicher Circ. 2011

Brussels' BAV repair: *Why is VSR so efficient?*

1. Circumferential prosthetic annuloplasty → **Stable over time**
2. Remodel BAV geometry to 180° → **Durable configuration**, **Reduce the need of patch**
3. Optimal Coaptation

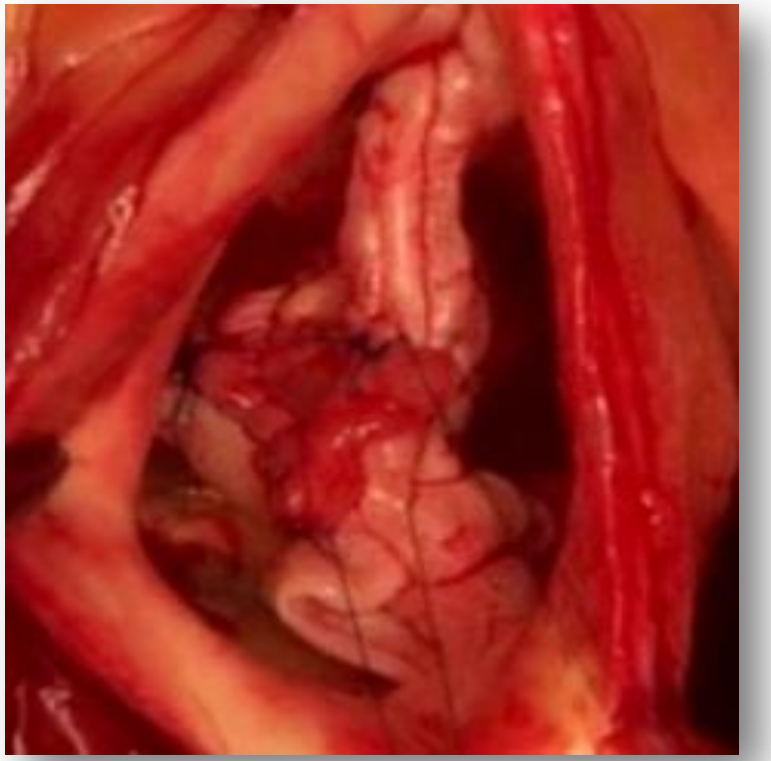

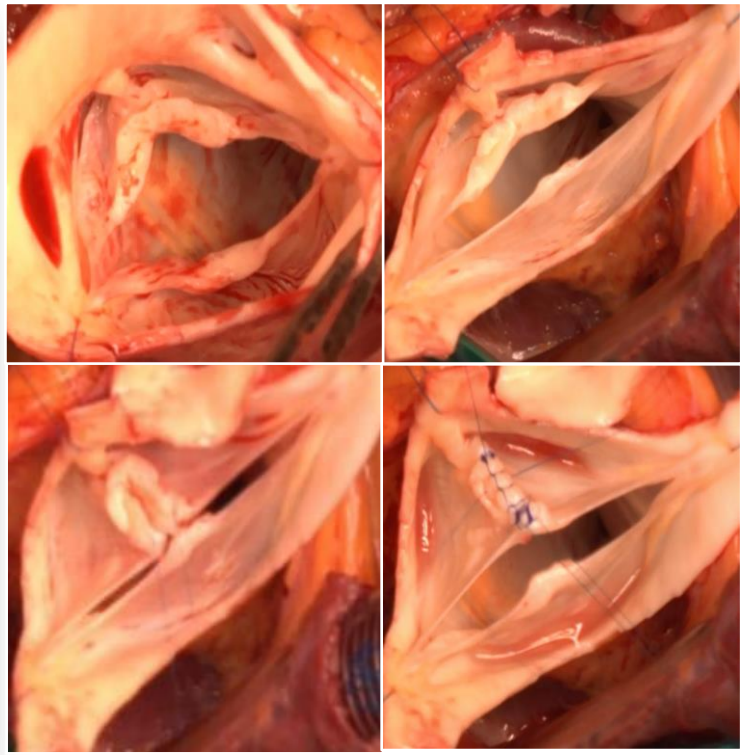

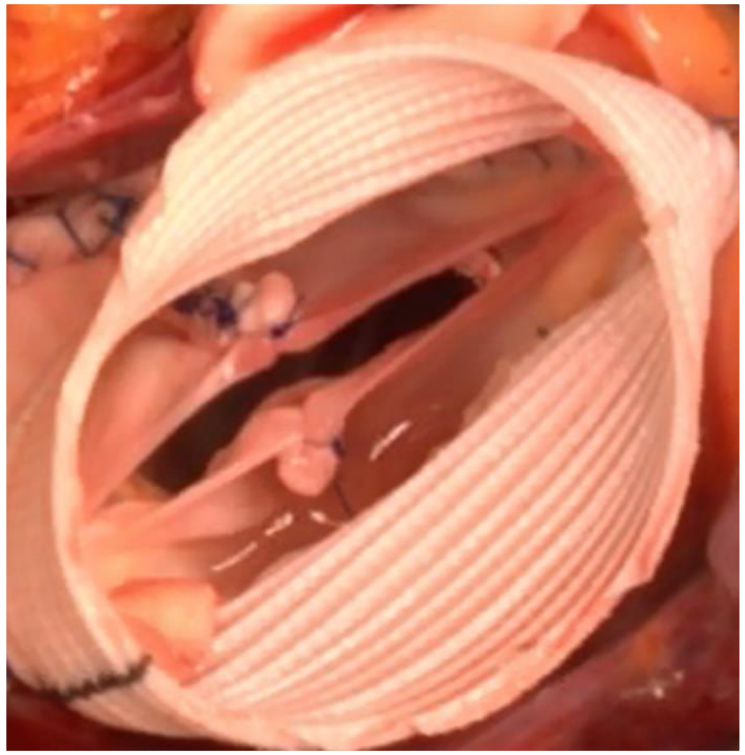

Brussels' BAV repair: *Why is VSR so efficient?*

1. Circumferential prosthetic annuloplasty → **Stable over time**
2. Remodel BAV geometry to 180° → **Durable configuration**, **Reduce the need of patch**
3. Optimal Coaptation

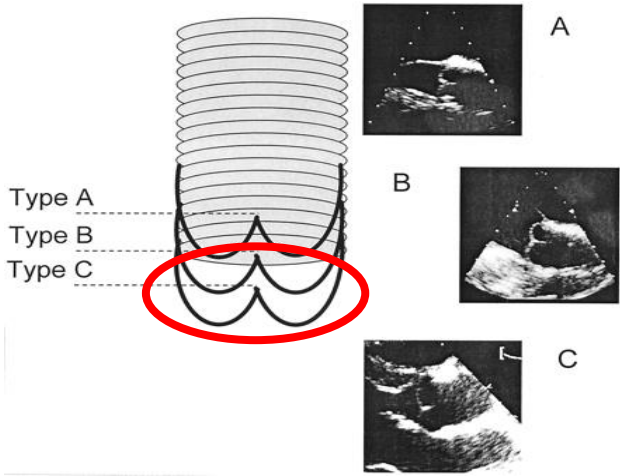

Pethig K. ATS 2002

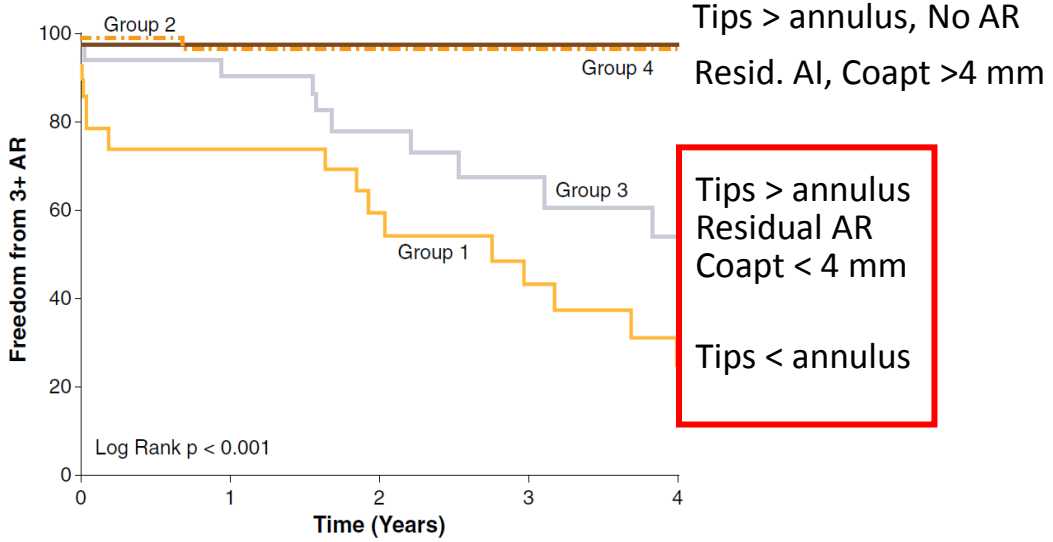

le Polain JB. JACC Card. Im. 2009

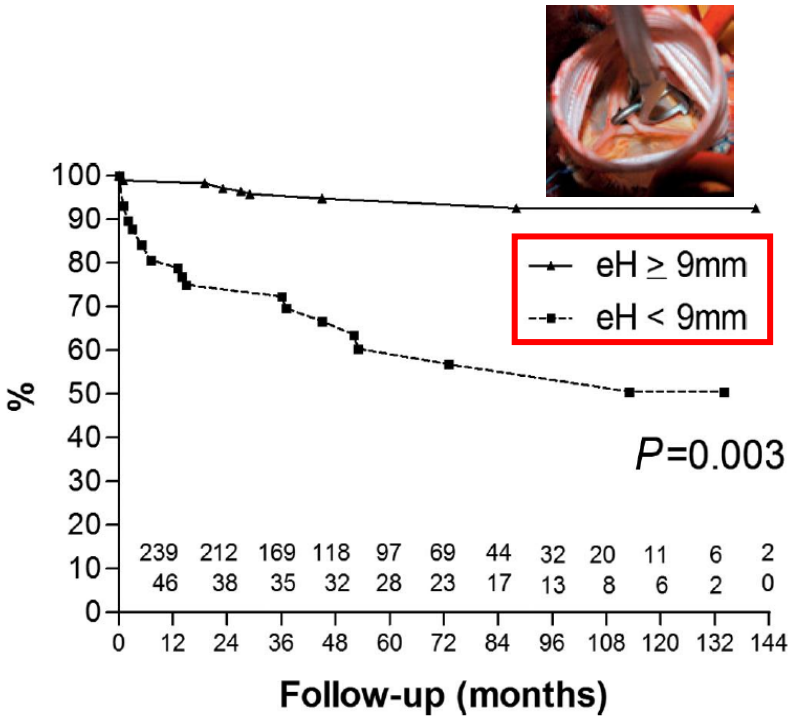

Aicher D. Circ. 2011

Brussels' BAV repair: ***Brussels VSR cohort 440 pts (2000-2017)***

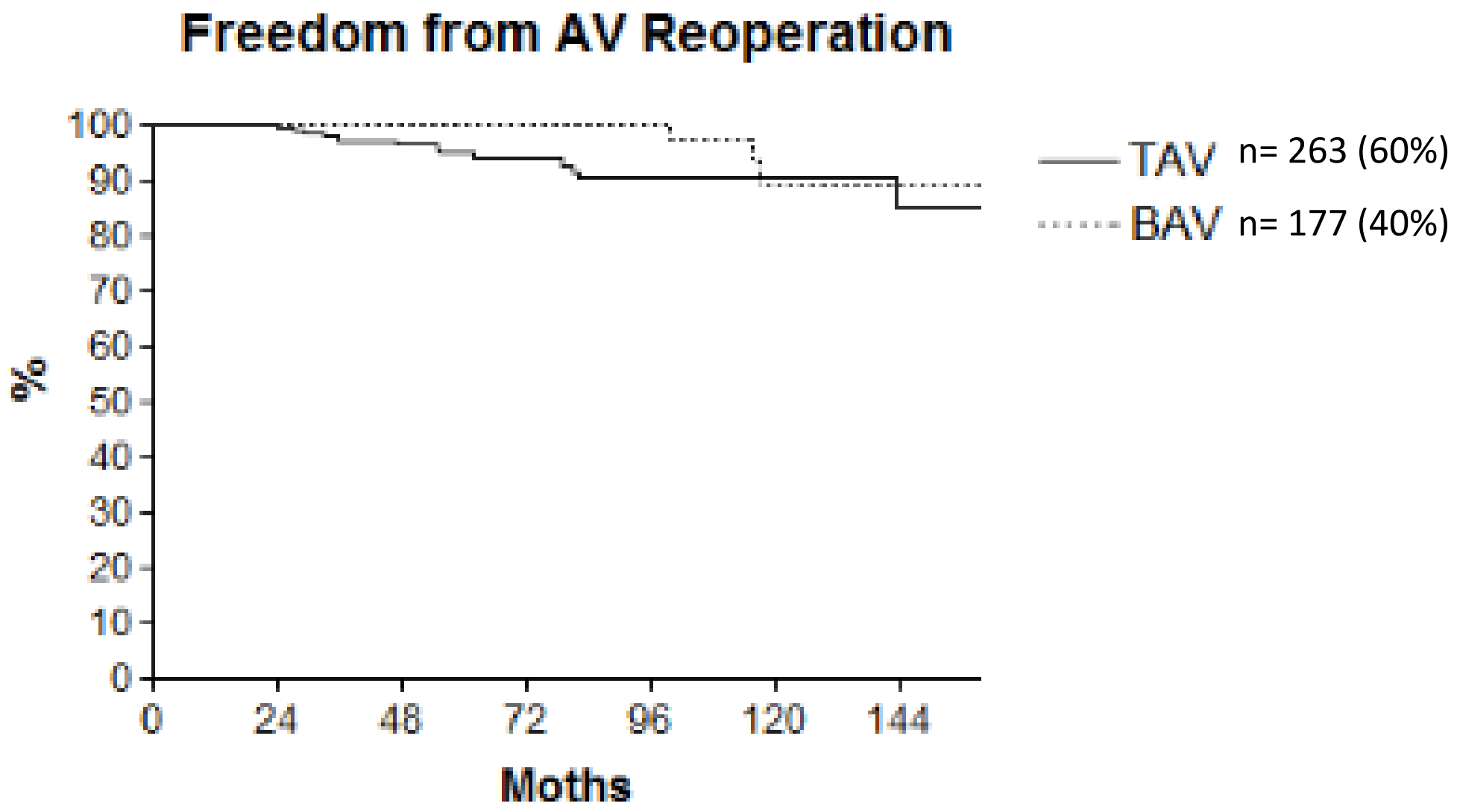

Brussels AV repair: *Current Approach of Root Repair in AI*

Normal Root (<40 mm)

Dilated Root (>40 mm)

Normal VAJ (<28 mm)
«Old patient» (>50 y)

Large VAJ (≥28 mm)
Frequent in young patient

Large VAJ (>28 mm)
Remodel BAV geometry 180°

Subcom. annuloplasty

External Ring Annuloplasty

VS Reimplantion

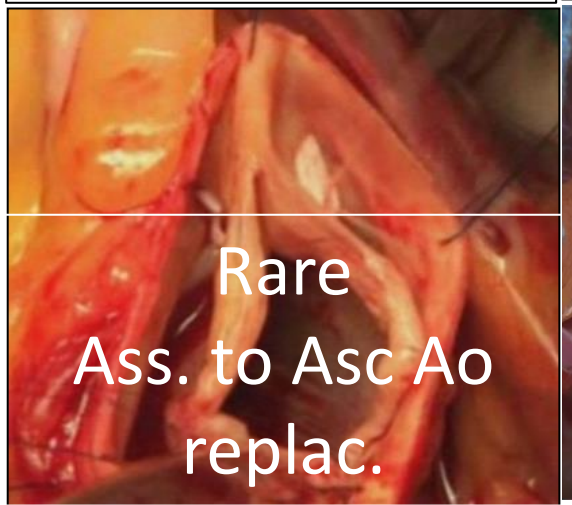

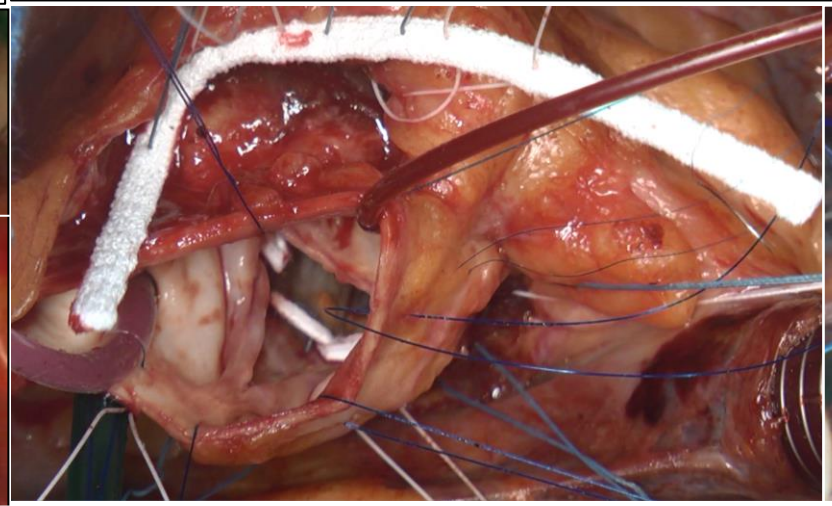

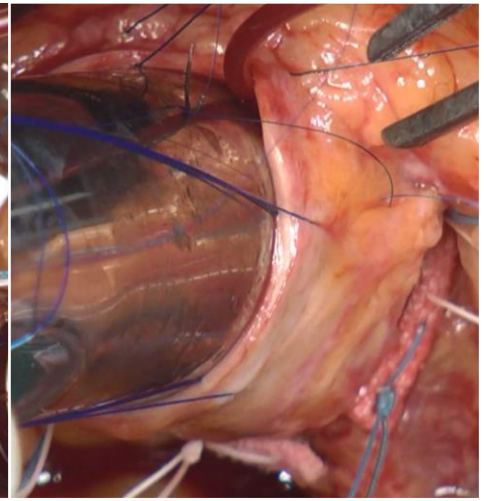

VAJ Ring Annuloplasty: St-Luc Technique

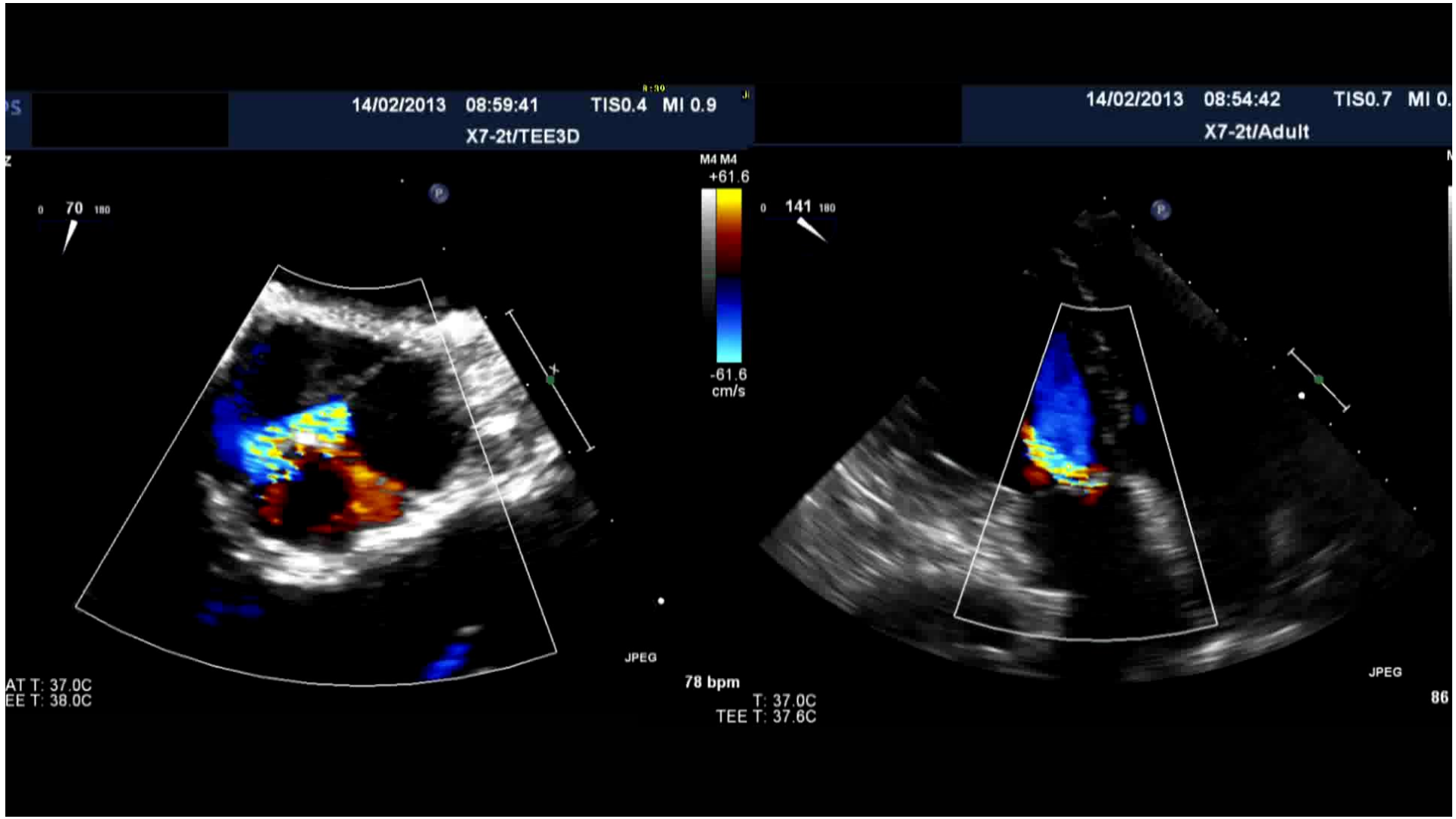

Conclusions

- AI disease is frequently associated with some degree of dilatation of one or more components of the aortic root especially in BAV but also in TAV. AV repair require correction and stabilization of all dilated component (VAJ, STJ, Sinus).

- VAJ dilatation is an independent risk factor of recurrent AI after AV repair without annuloplasty or with SCA.

- The SCA is a relatively unstable technique over time and therefore is not appropriate to treat patients with dilated VAJ (≥ 28 mm).

- Circumferential annuloplasties (VS reimplantation, external ring) are efficient techniques in case of VAJ dilatation, associated with low hospital mortality/morbidity and excellent repair durability.

Thank you

Effect of circumferential VAJ annuloplasty on repair durability

✓ *Schneider U., JTCVS 2016:*

- 268 isolated BAV repair
- 164 (61%) suture annuloplasty
- Hospit. mortality: 0% in annuloplasty group

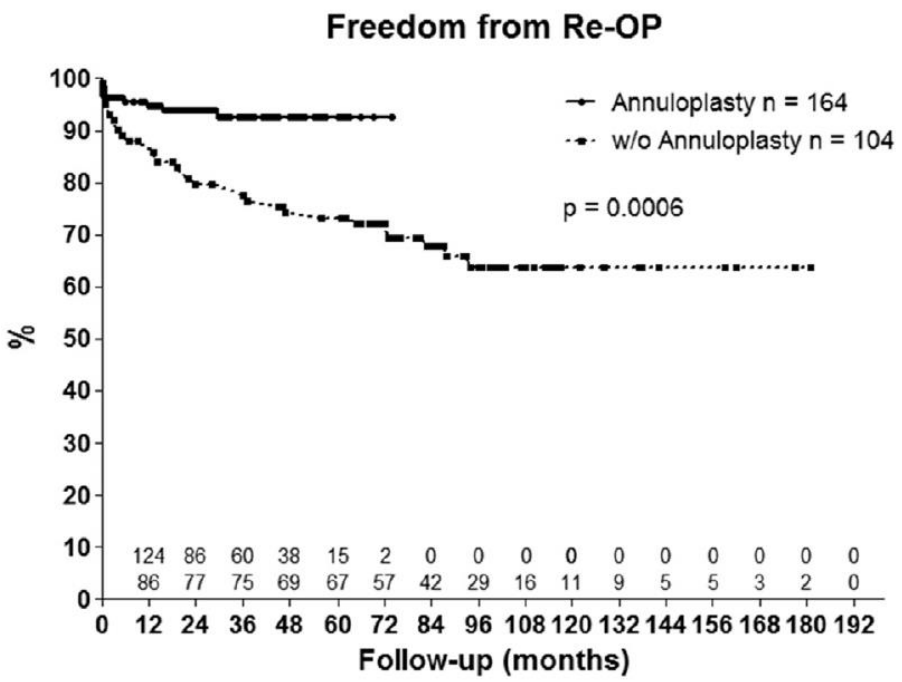

✓ *Lansac E., JTCVS 2016:*

- 232 AV repair with External Ring annuloplasty
- Ring if VAJ ≥ 25 mm
- Remodeling 64%, isolated AV repair 27%, Asc Ao replac. 9%
- Hospit. mortality: 1.4%, not valve related

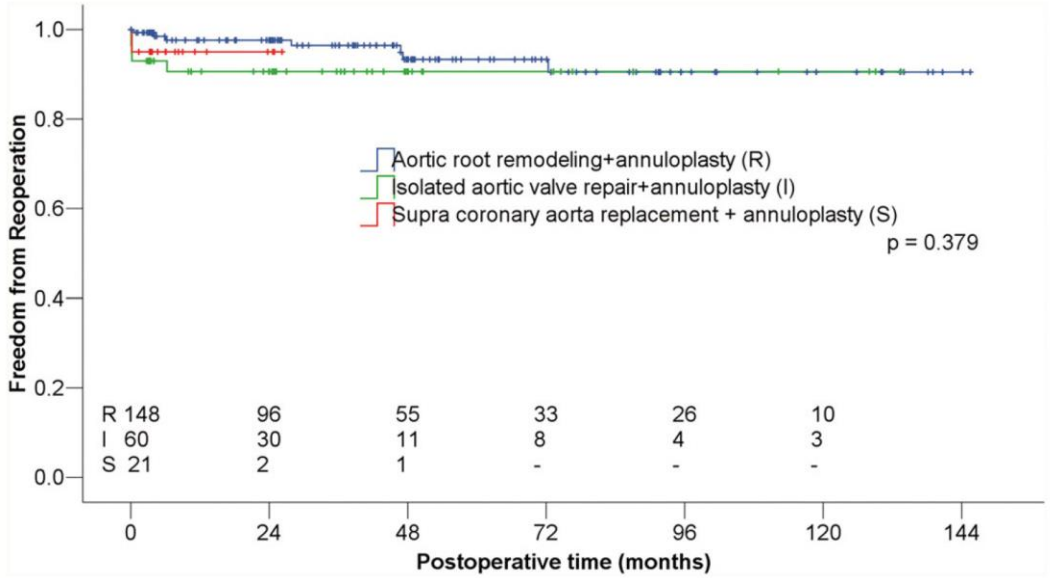

VAJ annuloplasty sizing

- ✓ *Objective is to achieve normal VAJ size: 20 – 26 mm*

- ✓ *Sizing based on cusp size: gH/VAJ= 0.6 - 0.8 (gH: [16 – 22], VAJ: [20 – 27]) (eH ≈ 9mm)*
  - *Swanson M., Circ Res 1974, Silver M., Am J Cardiol 1985, Kunzelman K., JTCVS 1994, N. Khelil ATS 2015*
  - *gH/VAJ=0.7 David T., JTCVS 1992, Gleason T. JTCVS2005*

- ✓ *Sizing based on patient size (BSA): normal AVA= 2cm²/m²*
  - *Svensson L., ATS 2003: VSReimpl., male: 1.5m² Hegar dilator 19mm, 2m²- 21mm, 2.5 m²- 23mm*
  - *H-J. Schäfers, JTCVS 2013: Suture annuloplasty, Hegar dilator 23mm (<1.8 m²), 25mm (>1.8 m²)*

- ✓ *Sizing based on preoperative VAJ size and device characteristics: Extensible External Ring*

	Aortic annular base Ø (Hegar dilators, mm)				
	25–27	28–30	31–33	34–39	>40
Tube graft Ø (mm)[a] supravalvular STJ ring Ø (mm)[b]	26	28	30	32	34
Subvalvular annuloplasty ring Ø (mm)	25	27	29	31	33

Lansac E., JTCVS 2016

VAJ annuloplasty sizing: *VAJ thickness !*

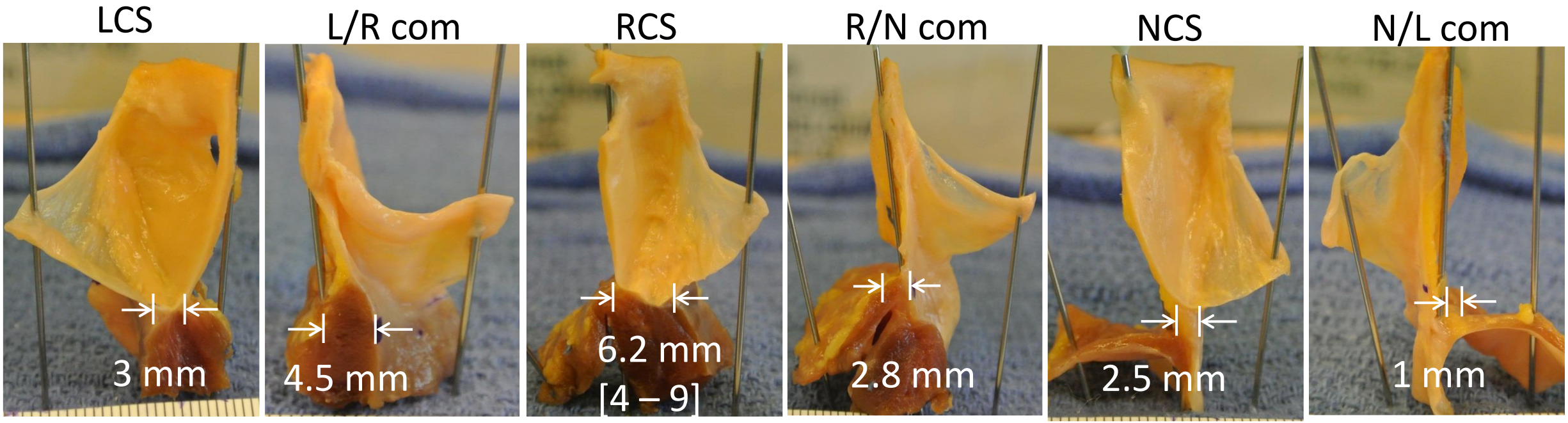

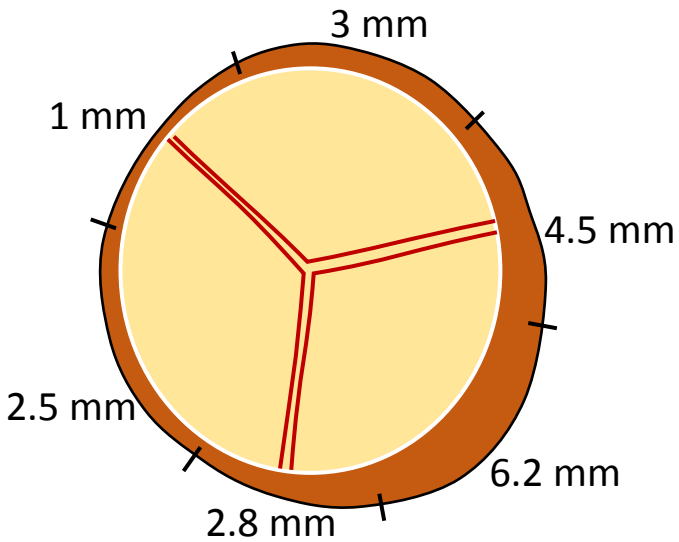

Mean AVJ thickness = 3.2 mm

With external graft or ring,

expected final AVJ diameter

= graft/ring Ø – 6 to 7 mm

Graft / Ring diameter	Expected AVJ diameter
26	± 20
28	± 22
30	± 24
32	± 26
34	± 28

Indications for VAJ annuloplasty

Aortic valve repair for AI

Normal Root (<45 mm)

Dilated Root (≥45 mm)

Normal VAJ (<26 mm)

Large VAJ (>26 mm)

- Large VAJ (> 28 mm)
- Root wall disease, +>40 mm
- Modify valve geometry (BAV)

(>26 mm)

(<26 mm)

No Annuloplasty

Ring annuloplasty

Reimplantation

Remod.+ Anpl

Remodeling

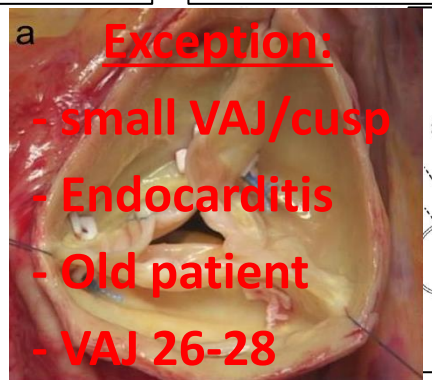

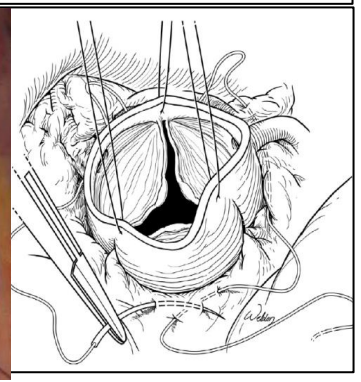

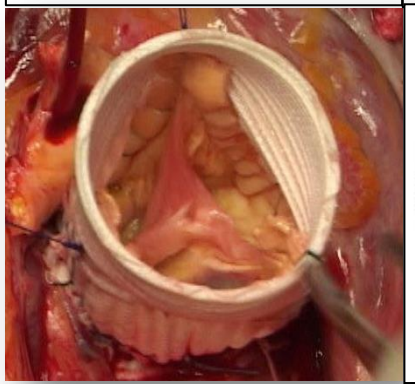

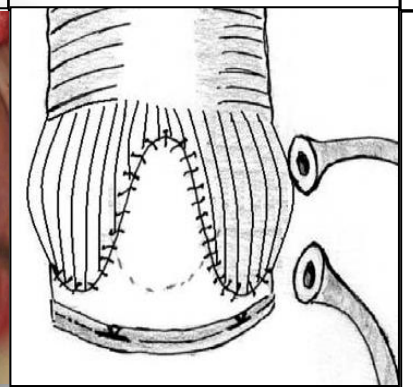

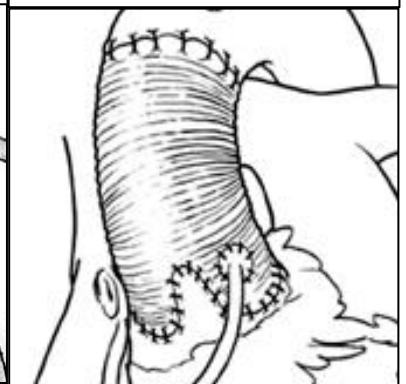

VAJ Ring Annuloplasty Techniques

		Stitch	ProsthetiC	Circumferential	External	Internal	Flexible	Rigid
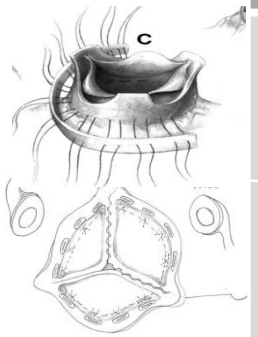	**Partial External Band David et al.**	-	X	-	X	-	X	-
	Internal band Izumoto et al.	-	X	X	-	X	X	-
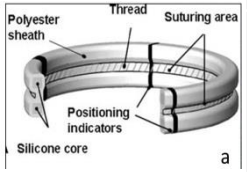	**Coroneo ring Lansac et al.**	-	X	X	X	(felt)	X	-
	**Aortic frame Rankin et al.**	-	X	X	-	X	-	X
	**Annulplasty Suture Schäfers et al.**	X	-	X	X	-	X	-
	**Annuloplasty Ring Sievers et al.**	-	X	X	-	X	-	X

Effect of ring annuloplasty on aortic root morphology

External ring

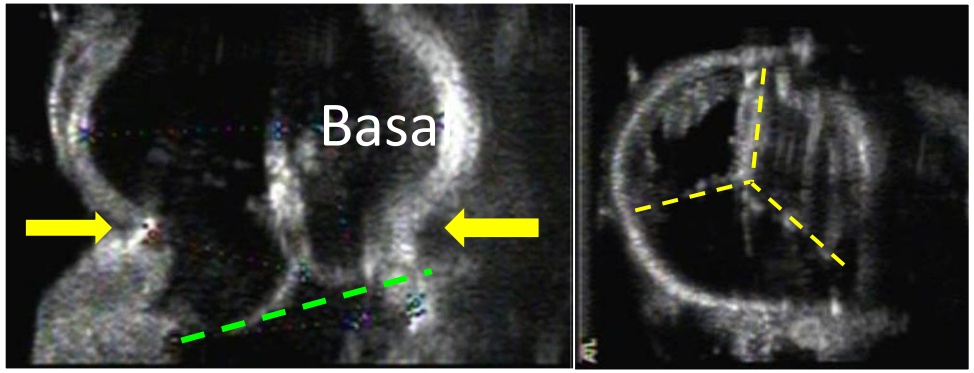

Internal Ring

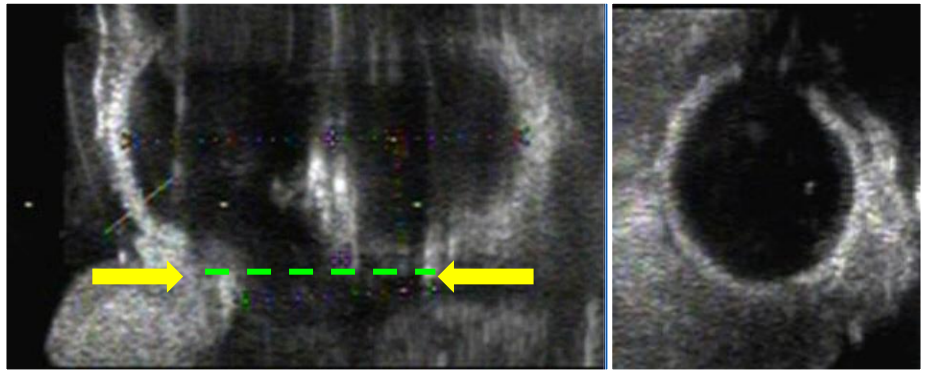

De Kerchove EJTCS 2012

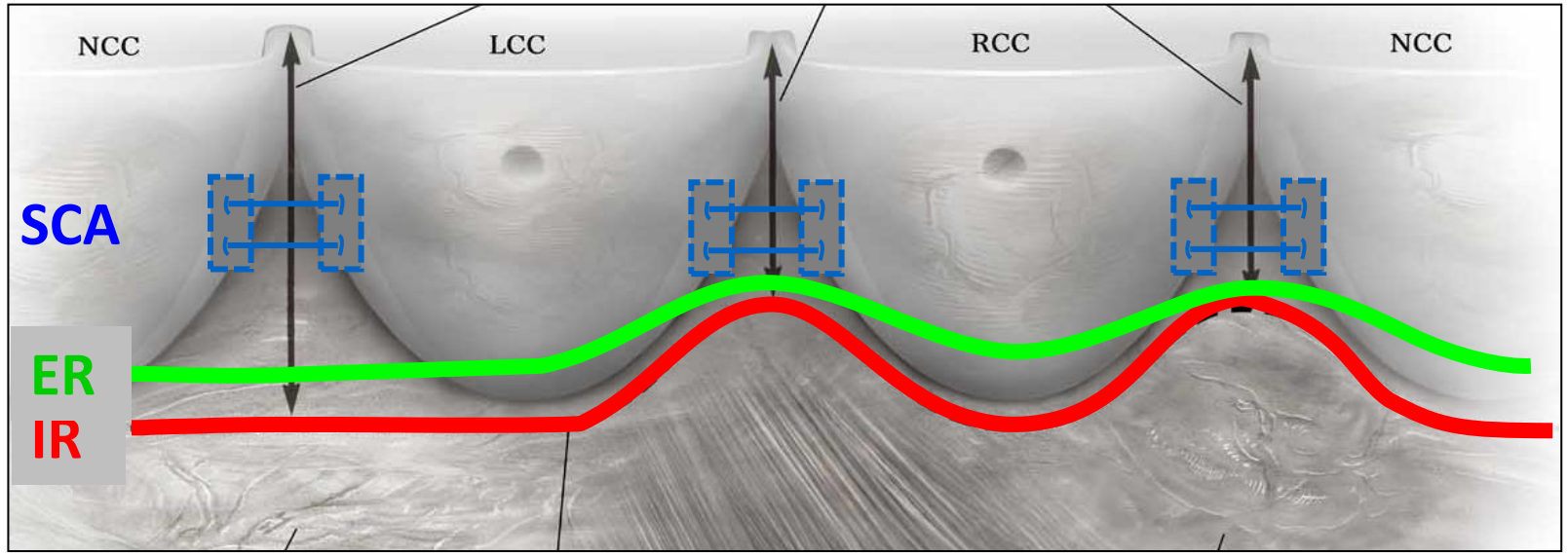

VAJ Ring Annuloplasty Techniques

Partial *(SCA)* - Rapid & easy - Unstable, recurrence?	**> ? <**	***Circumferential*** - More complex - More efficient and stable
Internal - Intravascular - Cusp proximity - Strictly subvalvular	**> ? <**	***External*** - Extravascular - Suboptimal position (septum)
Souple - More adaptable - Final Ø less predictable	**> ? <**	***Rigid*** - Less adaptable - Final Ø more predictable

Additional studies are necessary to evaluate the effect on valve function and repair durability of those new techniques

Early complication of SCA

- Cusp perforation
- Fistula Aorta – RV
- Aortic wall tear

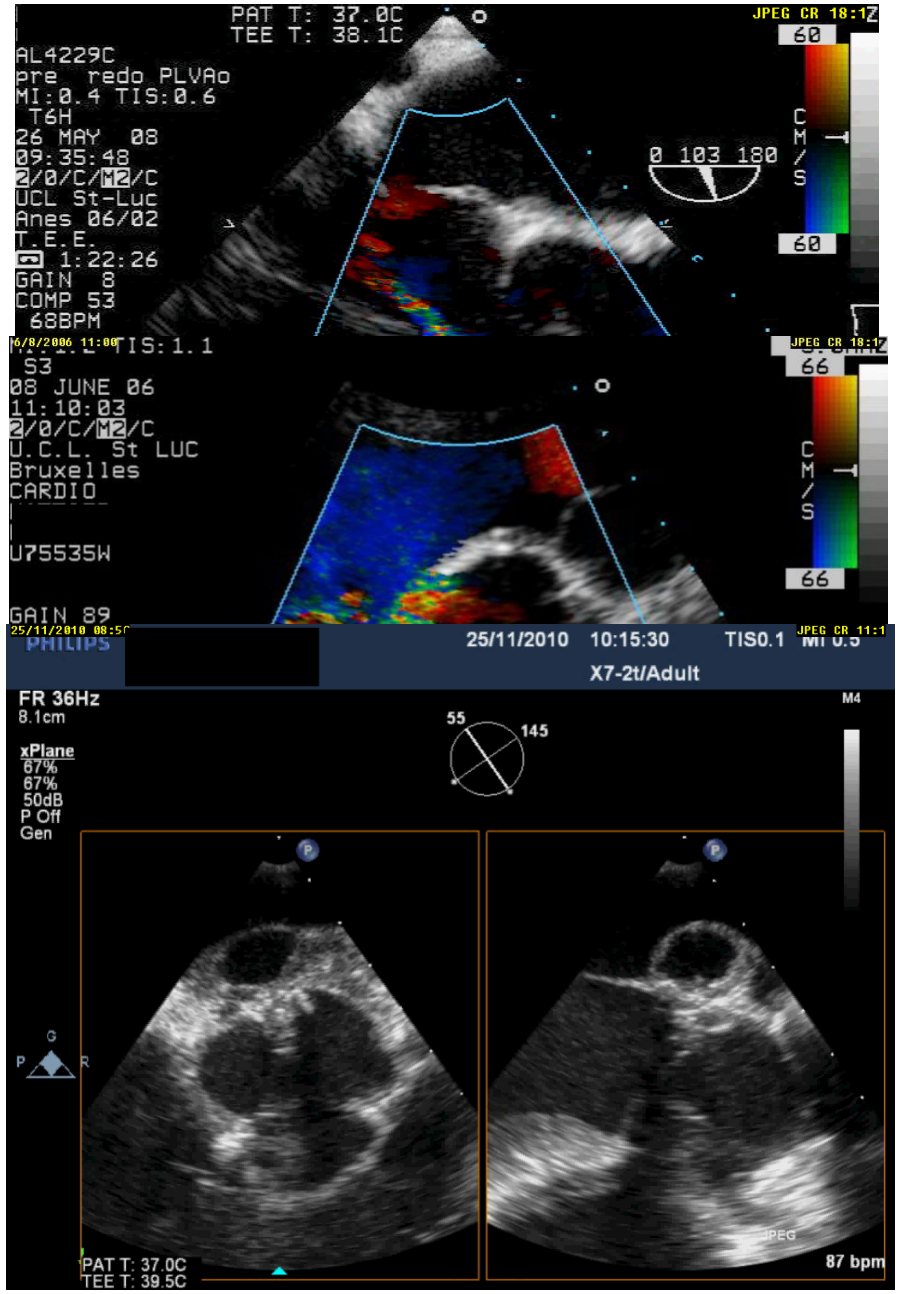

VAJ size in normal and pathological settings

	AI or Ao aneurism TAV (mm)	AI or Ao aneurism BAV (mm)
Navarra E. EJCTS 2013	-	28 mm(2D echo)
de Kerchove L. EJCTS 2015	25.2mm (2D echo)	-
Lansac E. EJCTS 2016	(2/3 TAV, 1/3 BAV) 28.3 mm (Hegar dilator)	
Schäfers H.J. JTCS 2013	27.6 (2D echo) 30.2 (Hegar dilator)	29.7(2D echo) 31.8 (Hegar dilator)

→ 2D echo measure ≈ Hegar dilator measures +2-3 mm