





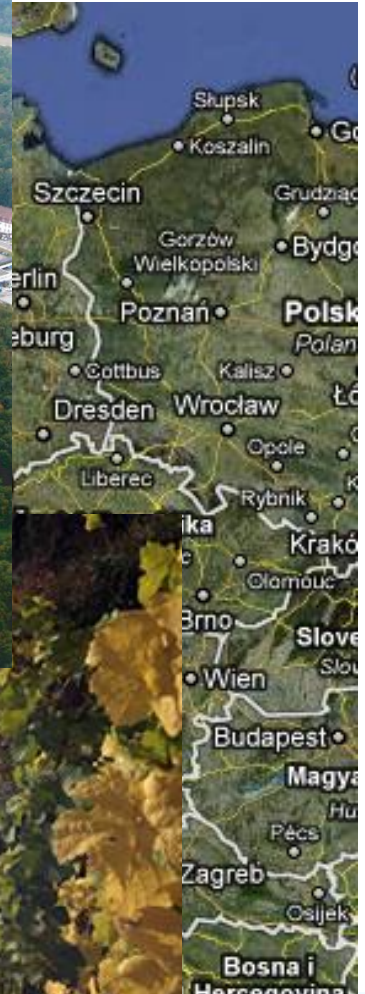
Aortic Valve Repair - Alternative to Replacement

H.-J. Schäfers

Dept. of Thoracic and Cardiovascular Surgery
University Hospital of Saarland
Homburg/ Saar
Germany



chäfers



Aortic Valve - Historic Repair Attempts

THE SURGICAL CORRECTION OF AORTIC INSUFFICIENCY BY CIRCUMCLUSION

WARREN J. TAYLOR, M.D. (BY INVITATION), WENDELL B. THROWER, M.D. (BY INVITATION), HARRISON BLACK, M.D., AND DWIGHT E. HARKEN, M.D.
BOSTON, MASS.

J. Thoracic Surg.
February, 1958

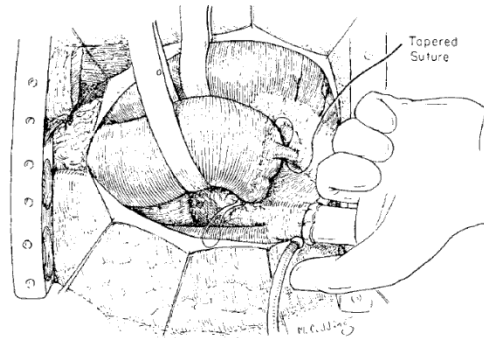
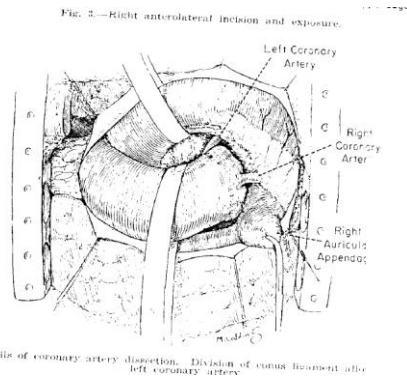


Fig. 6.—Double-tapered suture ligature passed under coronary arteries, anchored in relation to neutral (noncoronary) cusp. Finger as guide is in right atrium.

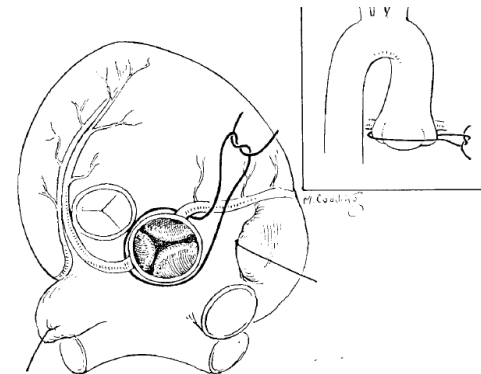
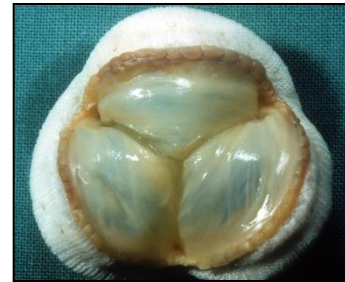
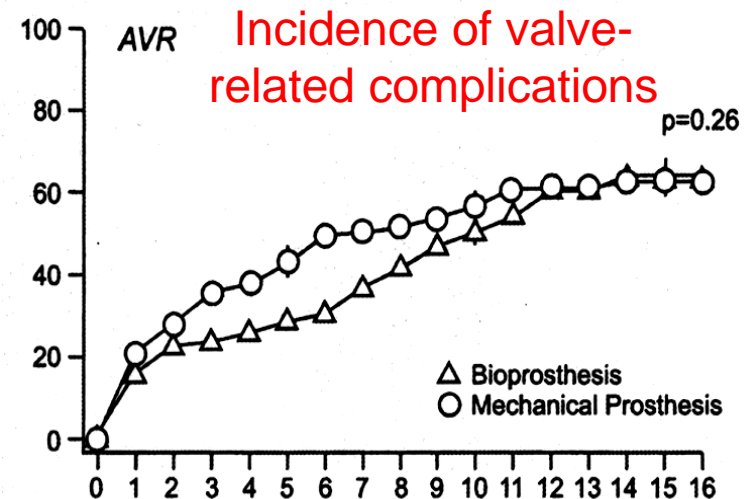


Fig. 7.—Location of circumcluding ligature.

Aortic Valve Replacement

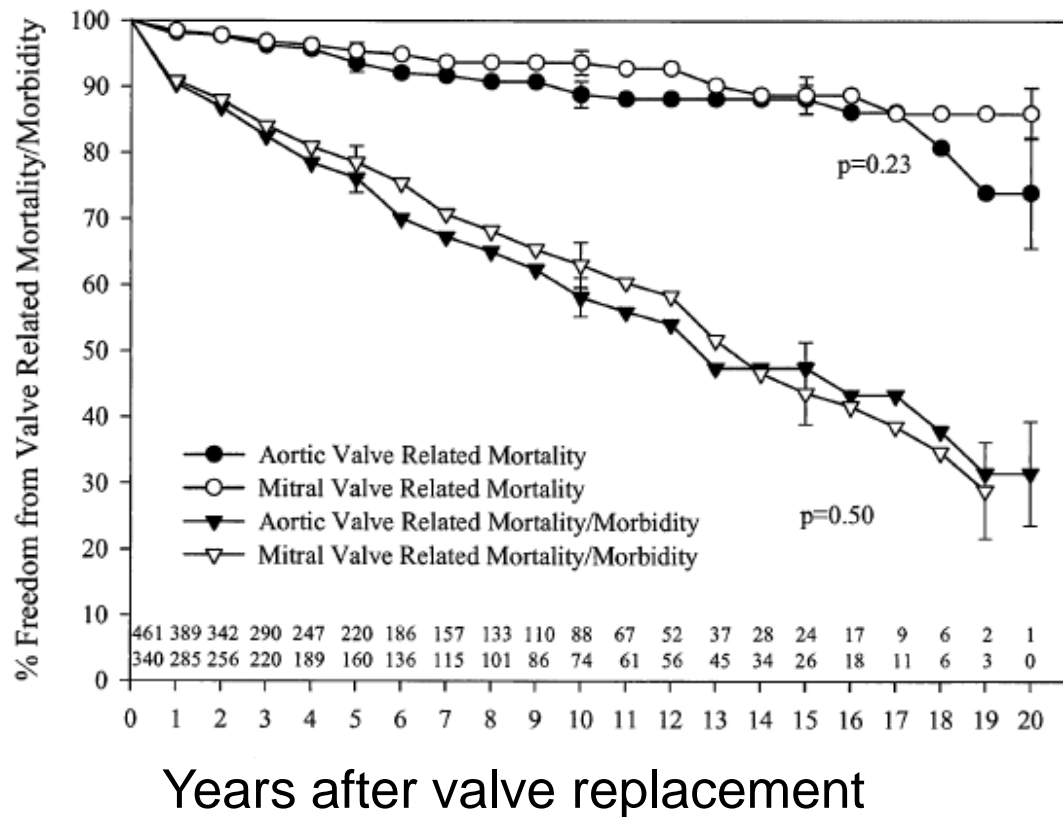


Thromboembolism
Anticoagulation/Hemorrhage
Structural failure
PV endocarditis

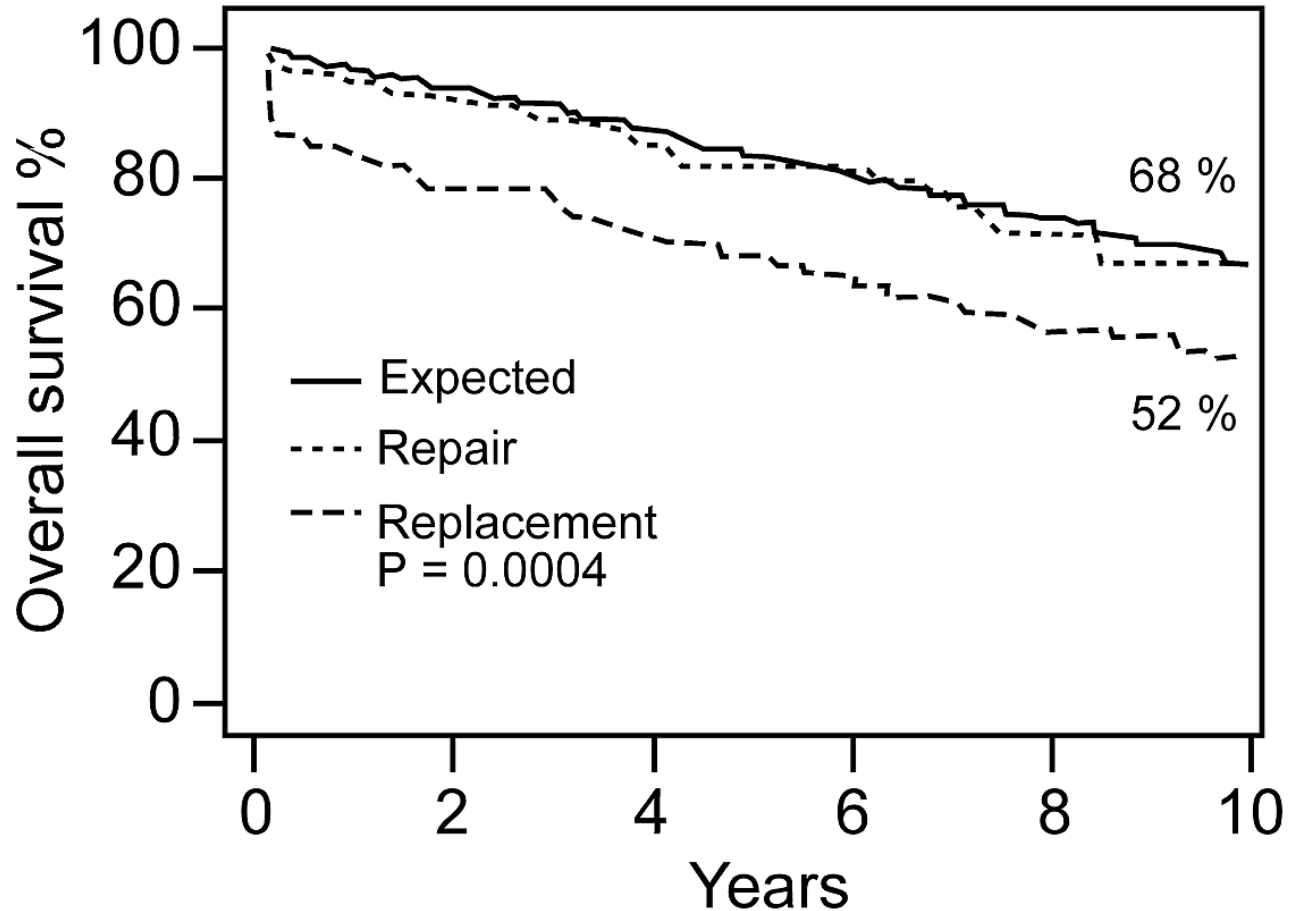


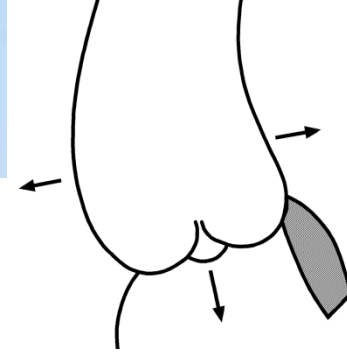
Hammermeister et al, JACC 2000

AVR - Mechanical Prosthesis-related Complications



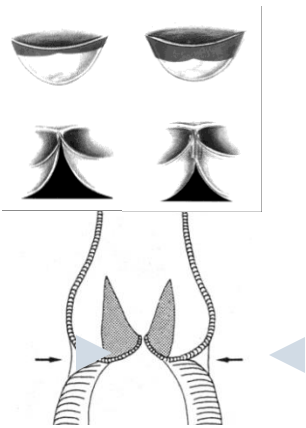
Repair vs. Replacement (Mitral)





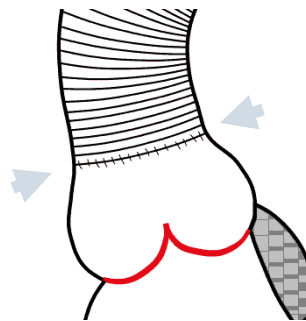
Root Repair – Technical Options

Subcommissural Plication



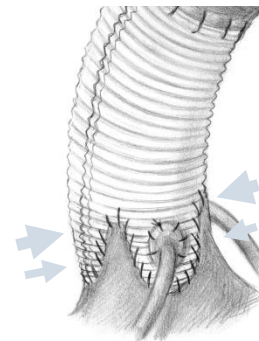
(Cabrol 1966)
(STJ < 33mm
AVJ > 25mm)

ST Junction Remodelling



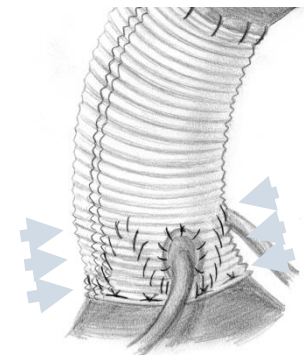
(Frater 1986)
(Sinus < 45 mm,
STJ ≤ 32 (39) mm)

Root Remodeling



(Yacoub 1993)
(Sinus > 45 mm (TEE),
AVJ < 30 mm)

Reimplantation of Aortic Valve



(David 1992)
(AVJ ≥ 30 mm)





Aortic Valve Repair

Valve-Sparing Operation in Aortic Root Ectasia

Hans-Joachim Schäfers and Hans G. Borst

Aortic valve regurgitation caused by aortic root ectasia is a common finding.^{1,2} The most common cause for this pathological complex is a diffuse degenerative process of connective tissue involving the media of the aortic wall, such as in Marfan's syndrome. Fragmentation and disarray of elastic fibers, formally described as cystic media necrosis, leads to hyperelasticity and decreased mechanical stress resistance. In addition to Marfan's syndrome, root ectasia has also been observed in other patients with or without apparent association to connective tissue disease.³

The risk of dissection or rupture of the ascending aorta and left ventricular volume overload caused by aortic regurgitation define the need for surgical intervention in patients with advanced stages of the disease. Insertion of a valved conduit is still regarded the gold standard for treatment of root ectasia.^{4,5} However, despite favorable perioperative results, the typical long-term risks of allprosthetic valve replacement

ated fibrous parts of the aortic root are preserved and resuspended within a vascular graft. Compared with mechanical prostheses, the long-term risks and disadvantages of anticoagulation are avoided. Originally, this operation was proposed for elective correction of root ectasia. We have also used it in root ectasia in conjunction with acute or chronic type I aortic dissection.

Indications for Surgery

In most patients, the decision for surgical intervention is made on the basis of the diameters of the aortic root and/or ascending aorta. A diameter of more than 5 cm has been shown to be associated with an increased risk of perforation or dissection and has been the standard cut-off point for decision making in replacement of the ascending aorta. Clinical observations indicate that, in patients with connective tissue disease (eg, Marfan syndrome) or familial history of aortic dissection, an

Operative Techniques in Cardiac & Thoracic Surgery

— A Comparative Atlas —

Editors - James L. Cox, MD Thoralf M. Sundt III, MD

Vol 1, No 1

July 1996

Aortic Valve Repair

- 1 **Operative Techniques in Cardiac & Thoracic Surgery: A Comparative Atlas**
- 2 **Introduction**
- 3 **Surgical and Pathological Anatomy of the Aortic Valve and Root**
Anton E. Becker
- 15 **Aortic Valve Repair and Reconstruction**
Carlos M.G. Duran
- 30 **Aortic Valve Repair**
Delos M. Cosgrove and Charles D. Fraser
- 38 **Valve-Sparing Operation in Aortic Root Ectasia**
Hans-Joachim Schäfers and Hans G. Borst
- 44 **Remodeling the Aortic Root and Preservation of the Native Aortic Valve**
Tirone E. David
- 57 **Valve-Conserving Operation for Aortic Root Aneurysm or Dissection**
Sir Magdi Yacoub
- 68 **Technique of Aortic Valve Preservation in Acute Type A Aortic Dissection**
Kwok L. Yun and D. Craig Miller



Aortic Valve Repair

VALVE-PRESERVING REPLACEMENT OF THE ASCENDING AORTA: REMODELING VERSUS REIMPLANTATION

H.-J. Schäfers, MD, PhD^a
R. Fries, MD^b
F. Langer, MD^a
N. Nikoloudakis, MD^a
T. Graeter, MD^a
U. Grundmann, MD^c

Objective: Aortic valve regurgitation in combination with dilatation of the ascending aorta and root requires a combined procedure to restore valve function and eliminate pathologic dilatation of the proximal aorta. Two techniques have been proposed for this purpose; the aortic root may be either remodeled with an especially configured vascular graft or replaced with reimplantation of the aortic valve within the graft. We have used both techniques depending on the individual pathologic condition of the aortic root. **Methods:** Of 107 patients undergoing operation for proximal aortic disease between October 1995 and November 1997, 40 patients had morphologically intact aortic valve leaflets in conjunction with dilatation of the aortic root. Of these, 15 patients underwent an operation as a surgical emergency for acute aortic dissection type A.

(J Thorac Cardiovasc Surg 1998;116:990-6)



Aortic Valve Repair

Valve-preserving aortic replacement: Does the additional repair of leaflet prolapse adversely affect the results?

Frank Langer, MD
Thomas Graeter, MD
Nikolaous Nikoloudakis, MD
Diana Aicher, MD
Olaf Wendler, MD
Hans-Joachim Schäfers, MD, PhD

Objective: Valve-preserving aortic replacement has evolved into an accepted therapeutic option for aortic ectasia with morphologically intact leaflets. Some patients, however, exhibit additional leaflet prolapse. We compared the results of established valve-preserving techniques with those of the combination of valve-preserving aortic surgery and additional repair of leaflet prolapse.

The Journal of Thoracic and Cardiovascular Surgery • August 2001

Comparison of Aortic Valve Gradient During Exercise After Aortic Valve Reconstruction*

Thomas P. Graeter, MD; Michael Kindermann, MD; Roland Fries, MD;
Frank Langer, MD; and Hans-Joachim Schäfers, MD, FCCP

Purpose: Aortic valve preservation is a promising alternative to conventional composite replacement of aortic valve and ascending aorta. This approach may have a physiologic benefit compared with valve replacement similar to that seen in mitral valve reconstruction. We investigated aortic valve gradients at rest and during exercise in patients who had undergone valve-preserving aortic replacement and compared them with composite replacement of valve and aorta.

Methods: Four groups were studied: nine patients underwent composite valve replacement (group A: valve diameter, 23 to 27 mm), eight patients underwent remodeling of the aortic root (group B), and another nine patients had reimplantation of the aortic valve (group C). Healthy volunteers were studied as a control group (group D). Using continuous-wave Doppler echocardiography, all patients were examined on a bicycle ergometer for aortic valve gradients (0 to 75 W).

Results: There were no differences among the groups with respect to age, body surface, left ventricular end-diastolic diameter, fractional shortening, or left ventricular mass. Maximum resting gradients were significantly elevated in group A compared with groups B, C, and D (group A: 21.3 ± 7.1 mm Hg; group B: 9.0 ± 4.5 mm Hg; group C: 8.6 ± 3.7 mm Hg; group D: 4.9 ± 1.6 mm Hg; $p < 0.05$). At 75 W, group A exhibited significantly higher gradients than all other groups (group A: 31.3 ± 7.5 mm Hg; group B: 13.9 ± 6.6 mm Hg; group C: 12.8 ± 3.5 mm Hg; group D: 9.2 ± 1.9 mm Hg; $p < 0.05$). There was no significant difference among the other groups. Both valve-preserving groups had only insignificantly higher gradients than the control group.

Conclusion: Our data strongly support the suggestion that preserving the aortic valve restores nearly normal hemodynamic function of the aortic valve. Long-term observations will have to prove the clinical relevance of restoring physiologic aortic valve hemodynamics.

(CHEST 2000; 118:1271–1277)

In vitro comparison of aortic valve movement after valve-preserving aortic replacement

Roland Fries, MD,^a Thomas Graeter, MD,^b Diana Aicher, MD,^b Helmut Reul, MD,^c Christoph Schmitz,^c Michael Bickel, MD,^d and Hans-Joachim Schäfers, MD^b

Objective: In aortic valve regurgitation and aortic dilatation, preservation of the aortic valve is possible by means of root remodeling (Yacoub procedure) or aortic valve reimplantation (David procedure). In vivo studies suggest that these procedures substantially influence aortic valve-motion characteristics. Evaluation of aortic valve movement in vivo, however, is technically limited and is difficult to standardize. We evaluated the aortic valve-motion pattern by echocardiography after reimplantation and remodeling.

The Journal of Thoracic and Cardiovascular Surgery • July 2006

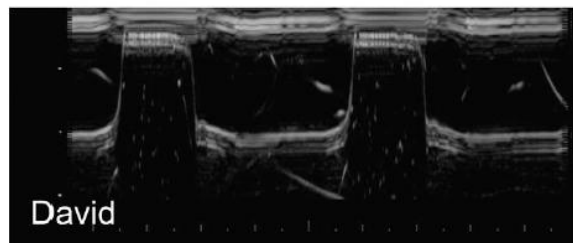
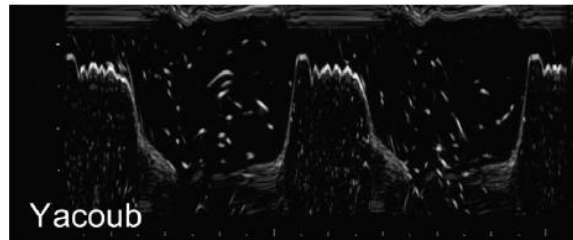


Figure 3. Typical M-mode recording of aortic valve motion after reimplantation (David) and remodeling (Yacoub).

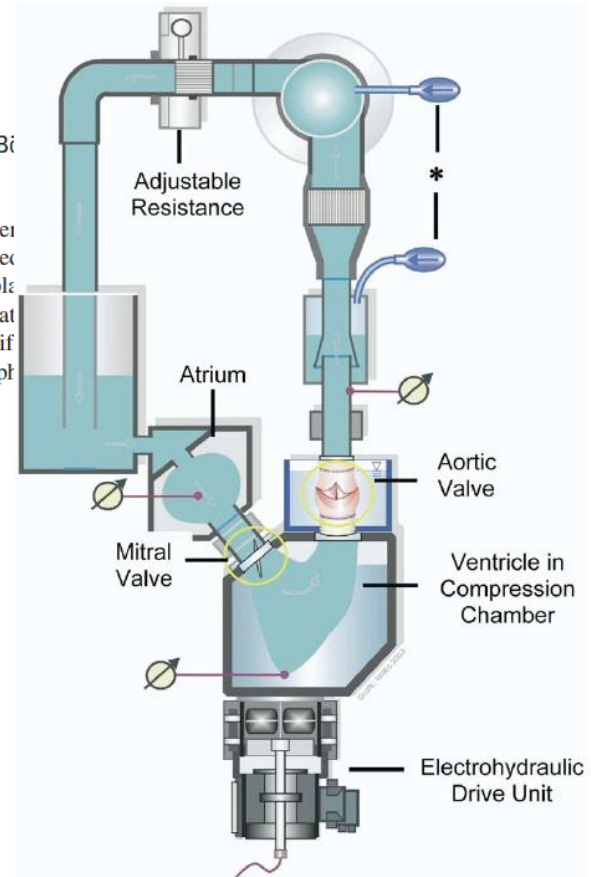
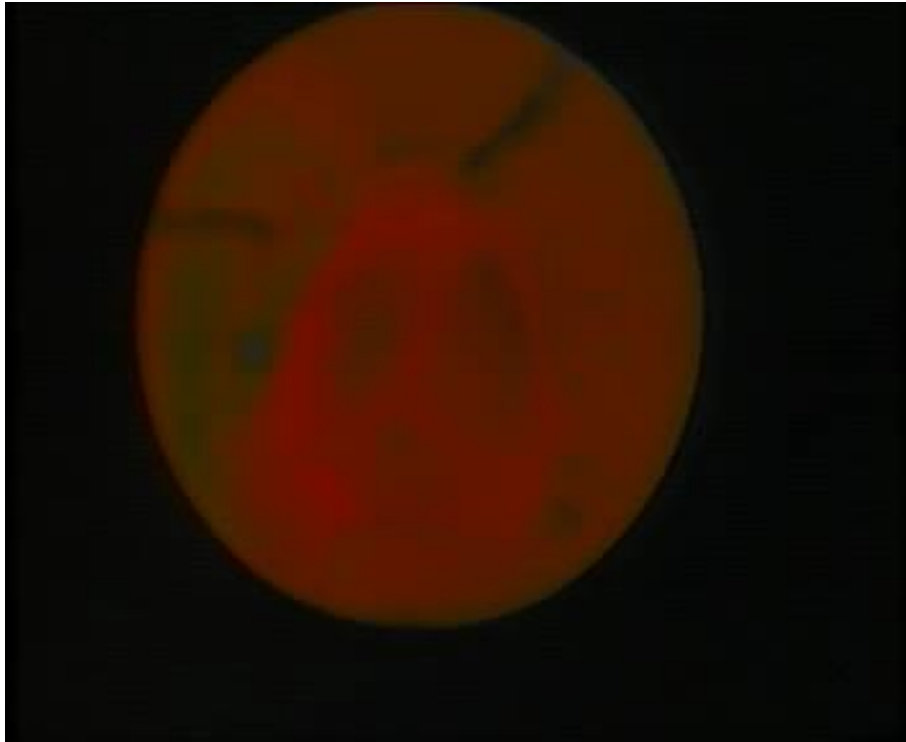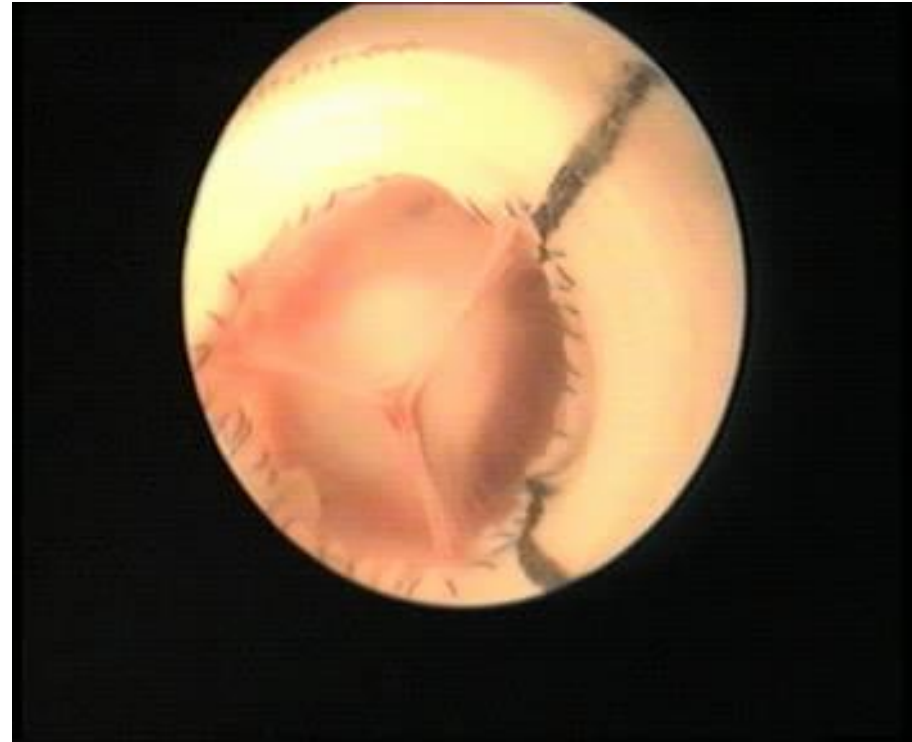


Figure 1. Schematic of the pulse duplicator. *Adjustable compliances.

Reimplantation



Remodeling



2 l/min

Remodeling of the Aortic Root and Reconstruction of the Bicuspid Aortic Valve

Hans-Joachim Schäfers, MD, PhD, Frank Langer, MD, Diana Aicher, MD, Thomas P. Graeter, MD, and Olaf Wendler, MD

Department of Thoracic and Cardiovascular Surgery, University Hospitals Homburg, Homburg, Germany

Background. Currently, isolated reconstruction of a regurgitant bicuspid aortic valve can be performed with adequate early results. Dilatation of the proximal aorta is known to be associated with this valve anomaly and may be partially responsible for the development of primary regurgitation or secondary failure of valve repair. We have used repair of the bicuspid valve with remodeling of the aortic root as an alternative to insertion of a composite graft.

Methods. Between October 1995 and May 1999, 16 patients (12 men, 4 women, aged 35 to 73 years) were seen with a regurgitant bicuspid aortic valve and dilatation of the proximal aorta of more than 50 mm. All patients underwent repair of the valve using either coapting

sutures alone (n = 12) or in combination with triangular resection of a median raphe (n = 4). Using a Dacron graft, the aortic root was remodeled and the ascending aorta (n = 16) and proximal arch (n = 4) replaced.

Results. No patient died. The postoperative degree of aortic regurgitation was less than grade II in all patients. Valve function has remained stable in all patients between 2 and 43 months postoperatively.

Conclusions. Reconstruction of the regurgitant bicuspid valve in the presence of proximal aortic dilatation is feasible with good results by combining the root remodeling technique with valve repair.

(Ann Thorac Surg 2000;70:542-6)

© 2000 by The Society of Thoracic Surgeons

Aortic root remodeling: Ten-year experience with 274 patients

Diana Aicher, MD, Frank Langer, MD, Henning Lausberg, MD, Benjamin Bierbach, MD, and Hans-Joachim Schäfers, MD

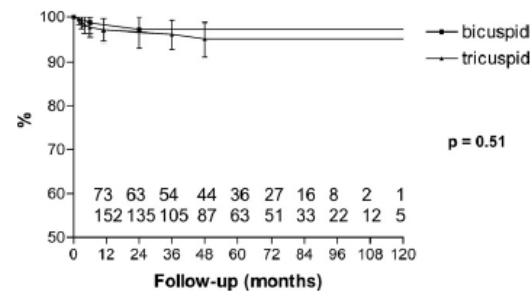



Figure 3. Actuarial freedom from reoperation of patients after remodeling analyzed by bicuspid and tricuspid valve anatomy including subjects at risk (bottom) and 95% confidence intervals (P = .51).

The Journal of Thoracic and Cardiovascular Surgery • October 2007



Aortic Valve Reimplantation in Ascending Aortic Aneurysm: Risk Factors for Early Valve Failure

Klaus Pethig, MD, Andrea Milz, Christian Hagl, MD, Wolfgang Harringer, MD, and Axel Haverich, MD

Department of Thoracic and Cardiovascular Surgery, Division of Surgery, Hannover Medical School, Hannover, Germany

Background. Aortic root reconstruction by reimplantation of the native valve represents a new therapeutic option for ascending aortic aneurysms. Information about long-term follow-up is limited, and possible predictors for failure of reconstruction have not been evaluated so far.

Methods. After aortic valve reimplantation 101 patients were followed in a prospective observational study. From this cohort the first 75 consecutive patients with a complete 1-year follow-up were chosen for further analysis. Clinical and echocardiographic data were obtained preoperatively, intraoperatively, and early postoperatively, as well as after 1 year of follow-up.

Results. No mortality was observed within the first 30 days. There were 52 male patients, mean age was 49.1 ± 20.6 years, observation period was 35.6 ± 20.6 months, and Marfan's syndrome was present in 22 patients. Although in 67 patients a stable valve function could be

demonstrated, 5 patients presented with mild aortic insufficiency or had to be operated on again for secondary valve failure ($n = 3$). Analyzing possible demographic, disease-related, and procedure-related risk factors in a multivariable approach, only level of coaptation within the graft (as assessed by echocardiography) could be identified as being related to the subsequent development of aortic insufficiency. Coaptation level within the tube graft (type A) resulted in a mean aortic regurgitation grade of 0.3 ± 0.5 as compared with a mean grade of 2.5 ± 0.6 for a coaptation type C (below the prosthesis; $p < 0.001$).

Conclusions. Aortic valve reimplantation is a promising alternative to aortic composite replacement. A level of coaptation within the tube graft is essential to achieve valve competence.

(Ann Thorac Surg 2002;73:29–33)

© 2002 by The Society of Thoracic Surgeons

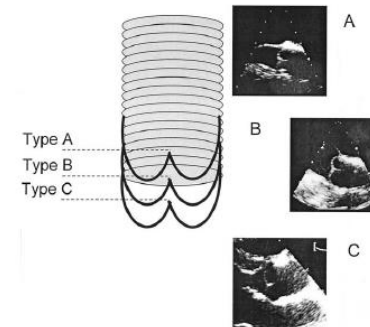


Fig 1. Type of coaptation of the aortic valve as assessed by echocardiography. Type A has the coaptation point ≥ 2 mm within the prosthesis. Type B has coaptation close to the lower border of the Dacron graft. Type C has coaptation ≈ 2 mm below the prosthesis.

Preservation of the Bicuspid Aortic Valve

Hans-Joachim Schäfers, MD, PhD, Diana Aicher, MD, Frank Langer, MD, and Henning F. Lausberg, MD

Department of Thoracic and Cardiovascular Surgery, University Hospitals of Saarland, Homburg/Saar, Germany

Background. Bicuspid anatomy of the aortic valve is a common reason for aortic regurgitation and is associated with aortic dilatation in more than 50% of patients. We have observed different patterns of aortic dilatation and used different approaches preserving the valve.

Methods. Between October 1995 and February 2006, a regurgitant bicuspid valve was repaired in 173 patients. The aorta was normal in 57 patients who underwent isolated repair. Aortic dilatation mainly above commissural level ($n = 38$) was treated by separate valve repair plus supra commissural aortic replacement. In 78 patients, aortic dilatation involved the root and was treated by root remodeling.

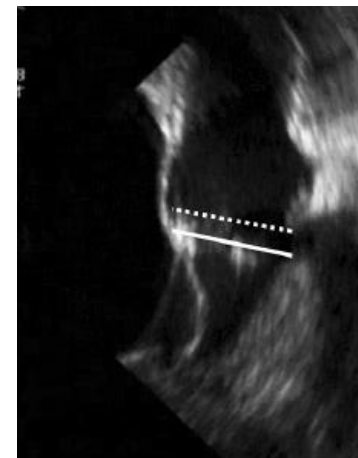
Results. Hospital mortality and perioperative morbidity were low in all three groups. Myocardial ischemia was significantly shorter in repair plus aortic replace-

ment than remodeling ($p < 0.001$). Freedom from aortic regurgitation II or greater at 5 years varied between 91% and 96%. Freedom from reoperation at 5 years was 97% after remodeling, but only 53% after repair plus aortic replacement ($p = 0.33$). Symmetric prolapse was the most frequent cause for reoperation.

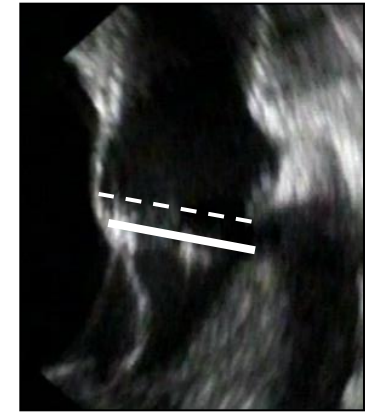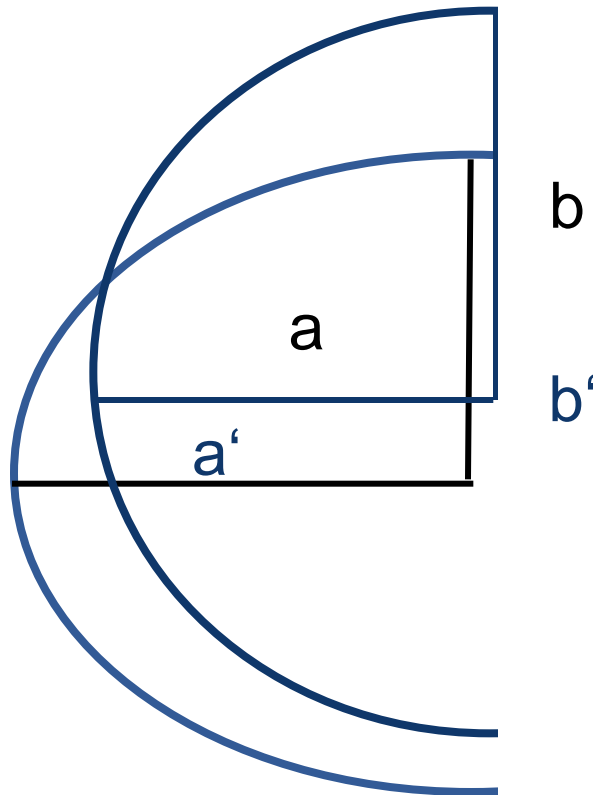
Conclusions. The long-term stability of bicuspid aortic valve repair is excellent in the absence of aortic pathology. In the presence of aortic dilatation, root remodeling leads to equally stable valve durability. In patients with less pronounced root dilatation, separate valve repair plus aortic replacement may be a less complex alternative. Symmetric prolapse should be avoided if the ascending aorta is replaced.

(Ann Thorac Surg 2007;83:S740–5)

© 2007 by The Society of Thoracic Surgeons



Reduction of STJ and Cusp Prolapse



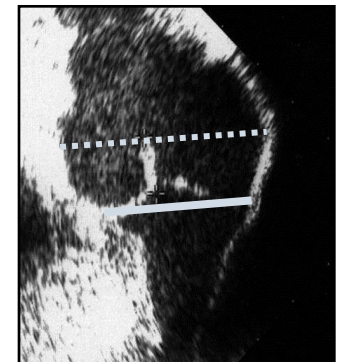
$$C_E = \pi \times [3/2 \times (a+b) - \sqrt{a \times b}]$$

$$b \approx r_{\text{aorta}}$$

$$a \approx r_{\text{cusp}}$$


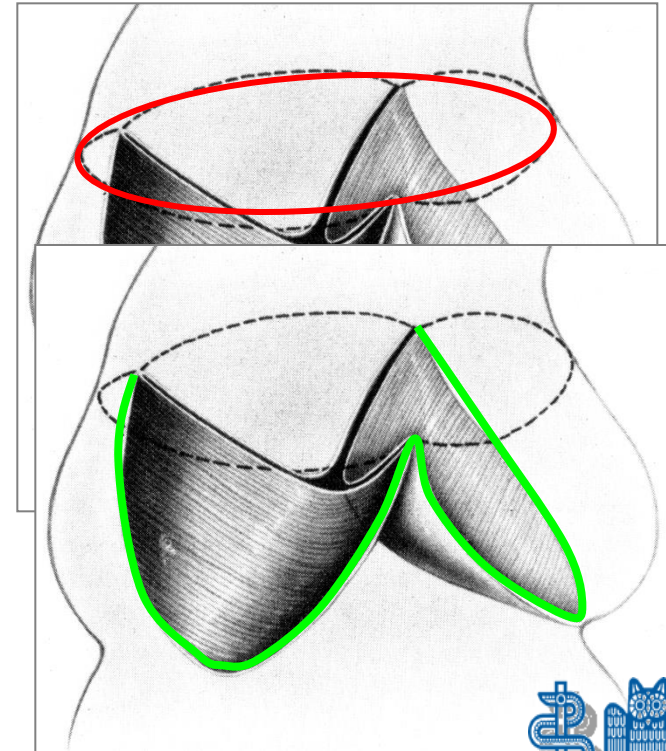


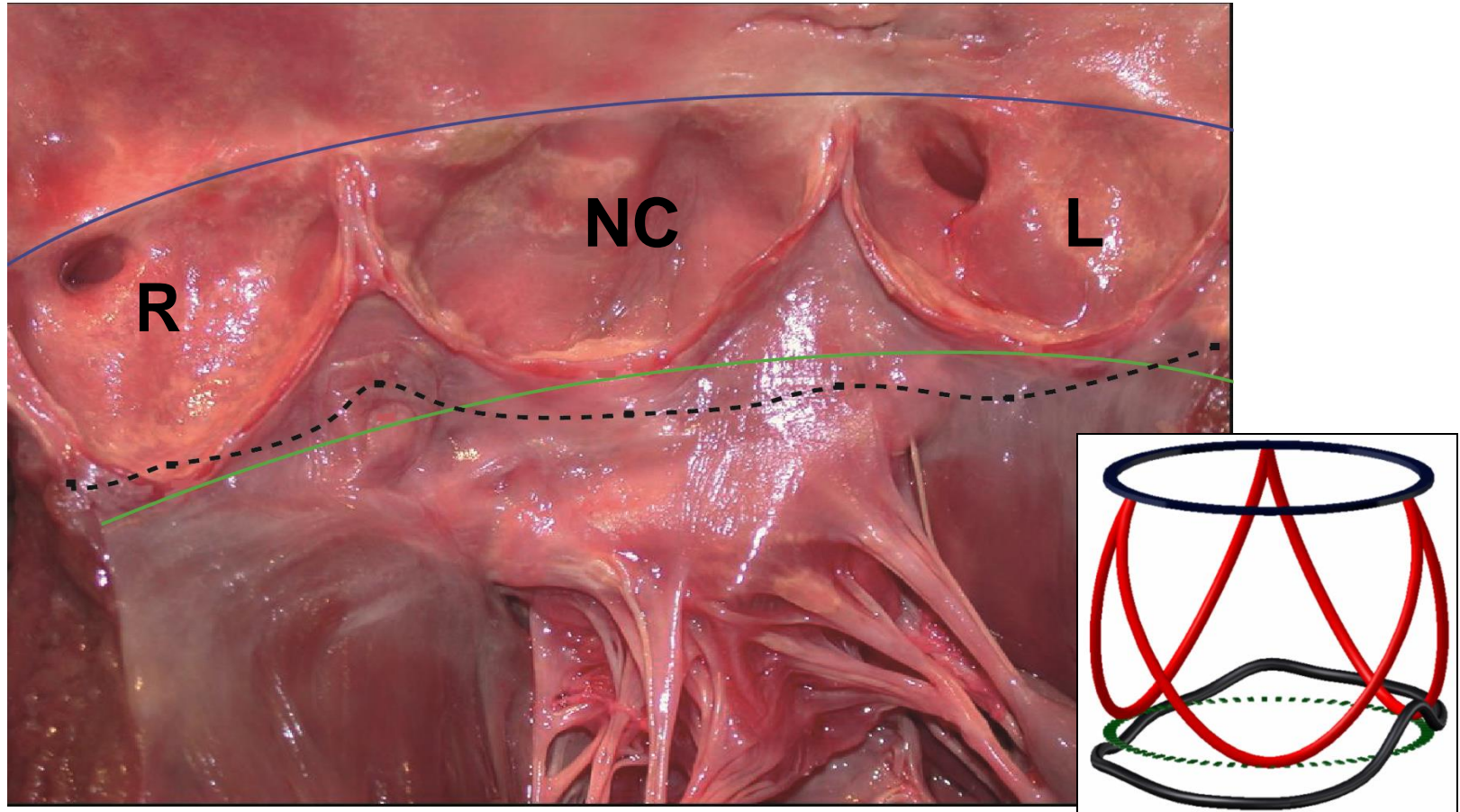
$$r_{\text{cusp}} \approx 1 / r_{\text{aorta}}$$



Aortic Valve Repair - Difficulties

Dimensions- of aortic root/(ring)



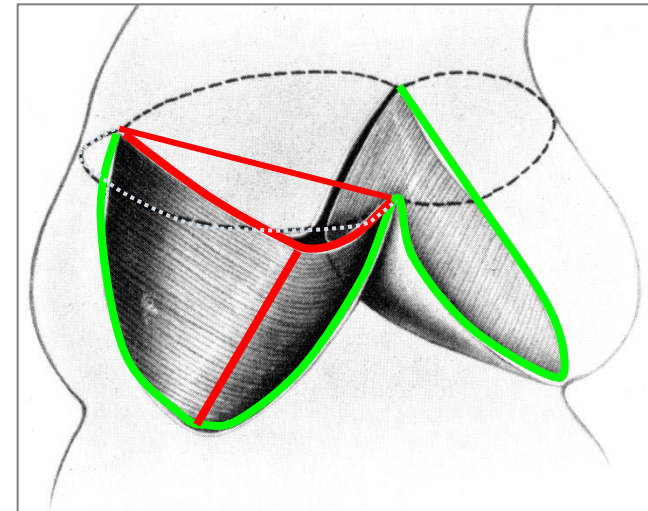


Courtesy of E. Lansac

Aortic Valve Repair - Difficulties


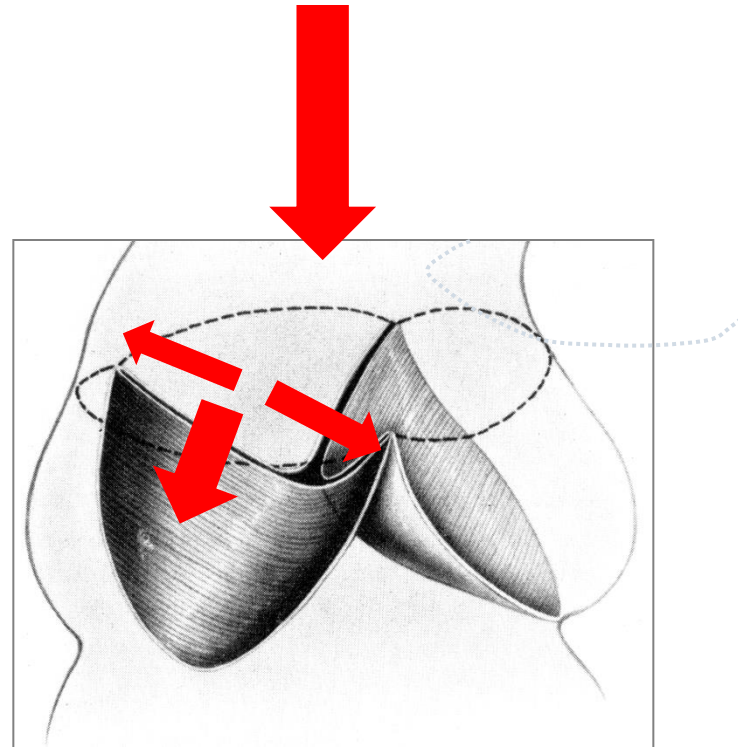
Configuration/coaptation of cusps

Vision from outflow



Aortic Valve Repair - Difficulties

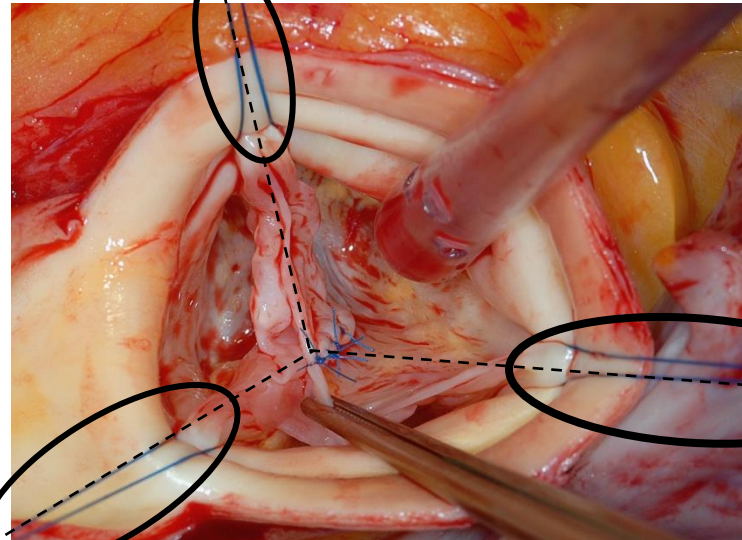
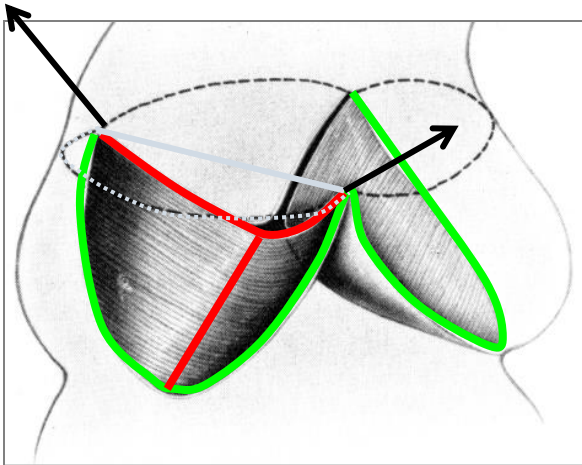
Geometry altered by
non-pressurized state



Solutions

Geometry altered by non-pressurized state!

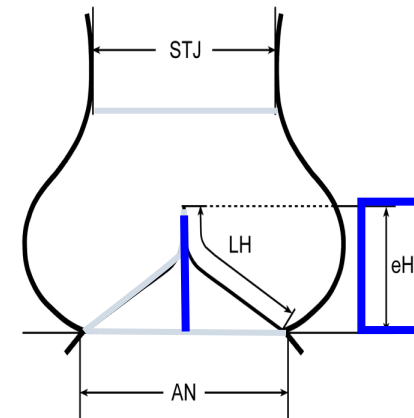
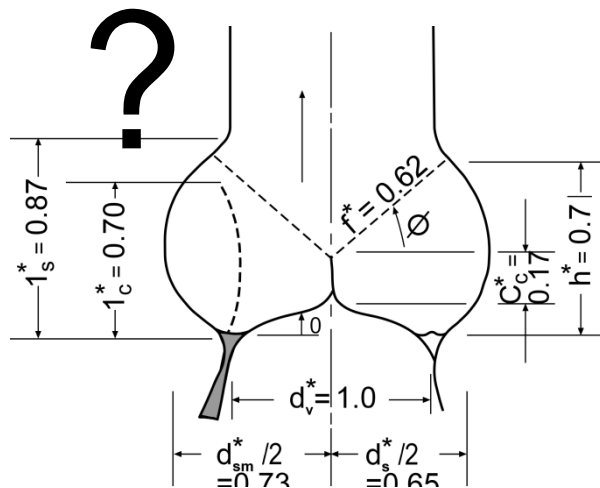
Stay sutures!



Aortic Valve Repair - Assessment

Solutions

Configuration/coaptation of cusps



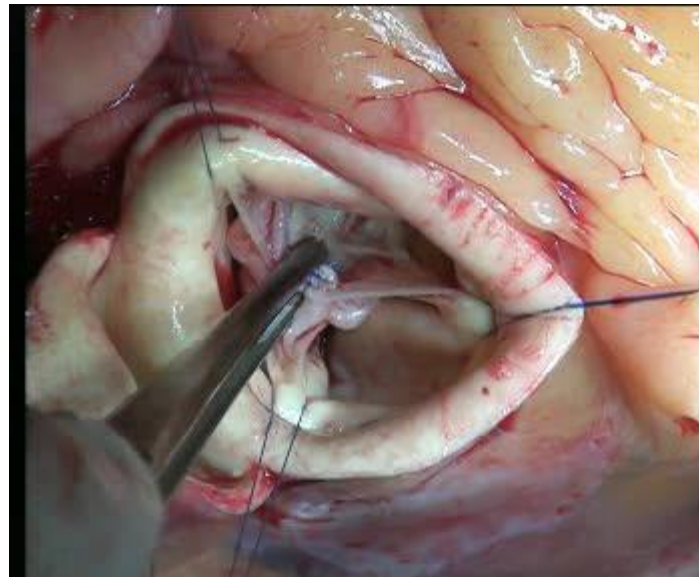
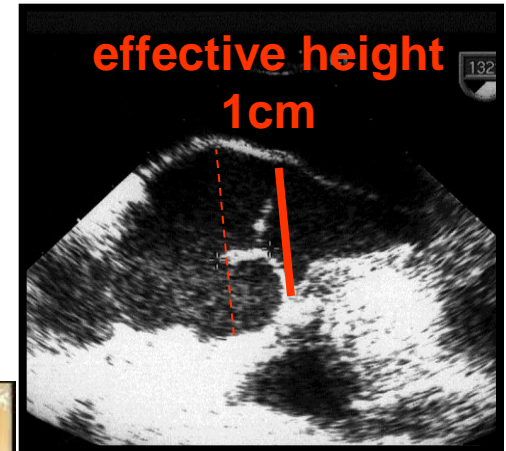
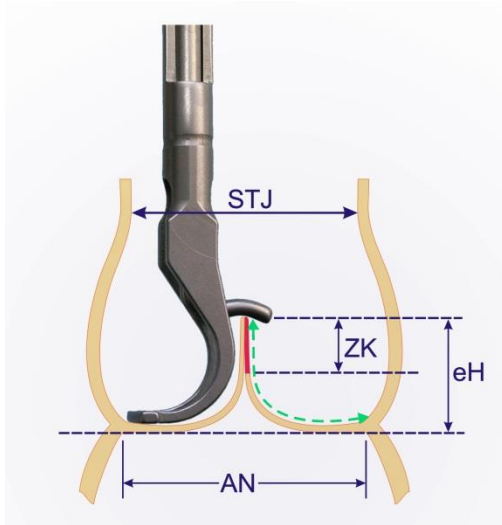
Swanson, Circ Res 1974

A new approach to the assessment of aortic cusp geometry

Hans-Joachim Schäfers, MD, PhD, Benjamin Bierbach, MD, and Diana Aicher, MD, Homburg/Saar, Germany



Cusp Configuration



Schäfers HJ et al, JTCVS 2006

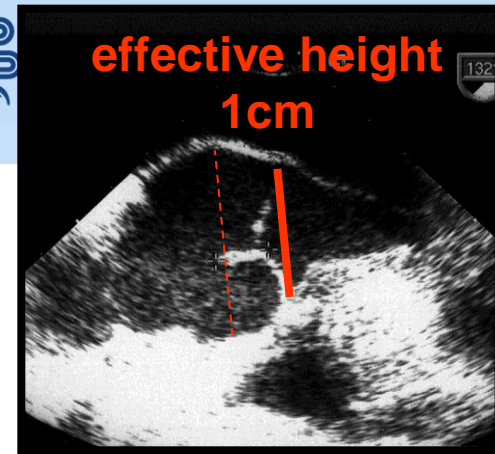


Effective Height



Aortic Repair – Introduction

H.-J. Schäfers



European Journal of Cardio-thoracic Surgery 38 (2010) 400–406

CARDIO-THORACIC
SURGERY

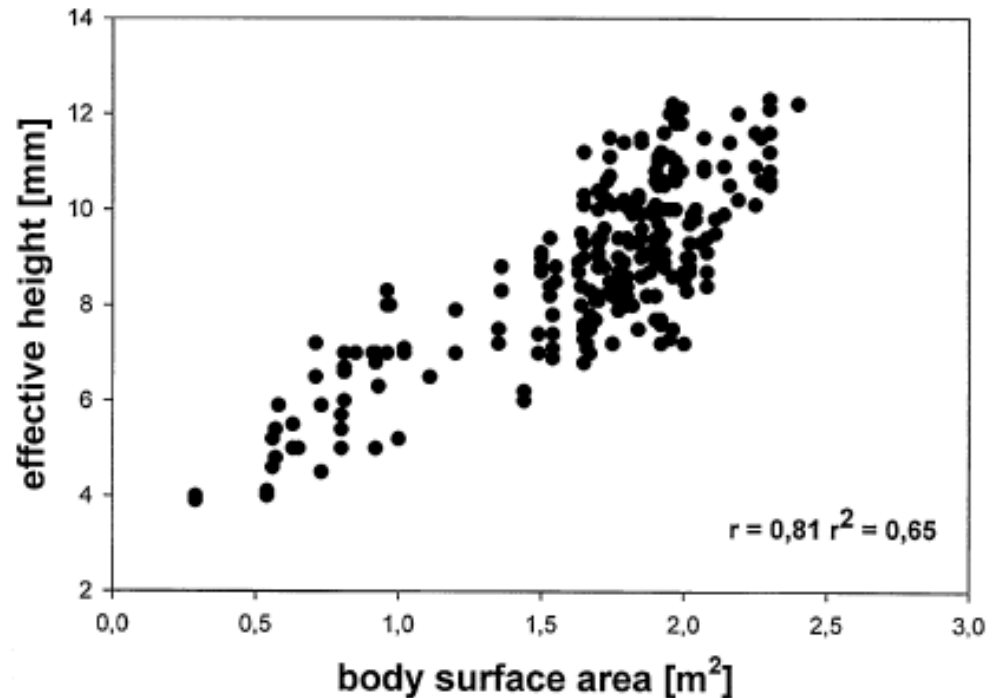
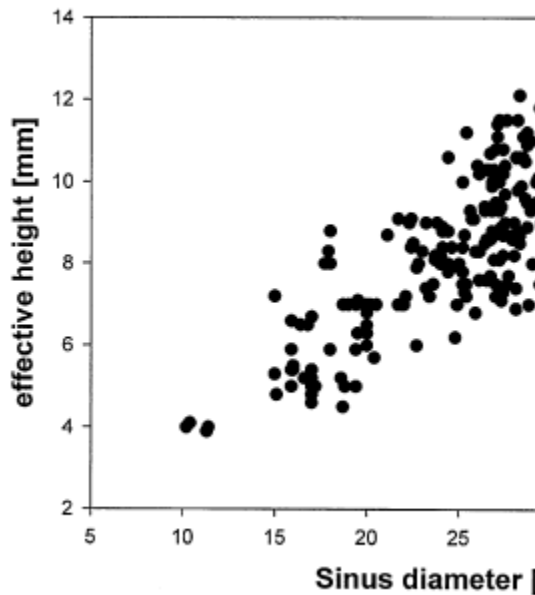
www.elsevier.com/locate/ejcts

Aortic root and cusp configuration determine aortic valve function[☆]

Benjamin Oliver Bierbach^a, Diana Aicher^a, Omar Abu Issa^a, Hagen Bomberg^a,
Stefan Gräber^b, Petra Glombitza^a, Hans-Joachim Schäfers^{a,*}

^aDepartment of Thoracic and Cardiovascular Surgery, University Hospitals of Saarland, Kirrbergerstrasse 1, 66421 Homburg/Saar, Germany

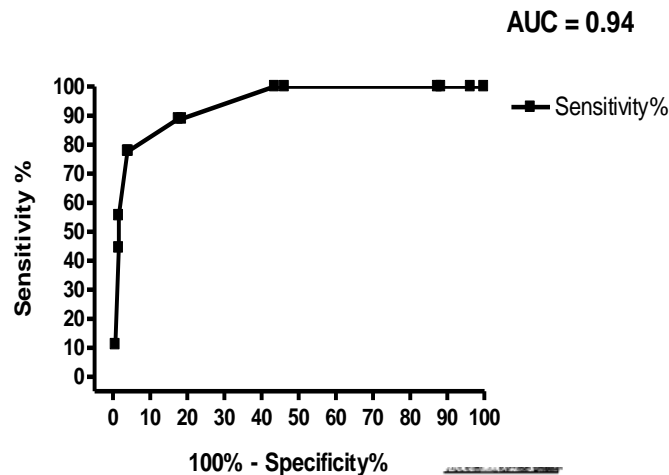
^bInstitute for Medical Biometry, Epidemiology and Inj



Aortic Valve Repair

Hypothesis: $eH \geq 9\text{mm}$ = predictor of near-normal av function

Receiver Operating Characteristic Curve



497 patients with $eH \geq 9\text{mm}$

No / trivial AR:	235 patients
Mild AR:	186 patients
Moderate AR:	2 patients

ELSEVIER

European Journal of Cardio-thoracic Surgery 38 (2010) 400–406

www.elsevier.com/locate/ejcts

Aortic root and cusp configuration determine aortic valve function[☆]

Benjamin Oliver Bierbach^a, Diana Aicher^a, Omar Abu Issa^a, Hagen Bomberg^a,
Stefan Gräber^b, Petra Glombitza^a, Hans-Joachim Schäfers^{a,*}

^aDepartment of Thoracic and Cardiovascular Surgery, University Hospitals of Saarland, Kirrbergerstrasse 1, 66421 Homburg/Saar, Germany
^bInstitute for Medical Biometry, Epidemiology and Informatics, University Hospitals of Saarland, Homburg/Saar, Germany

Ac

Mechanisms of Recurrent Aortic Regurgitation After Aortic Valve Repair

Predictive Value of Intraoperative Transesophageal Echocardiography

Table 3. Pre-Operative and Intraoperative TEE Measurements of the Study Population

	No/Trivial AR (n = 122)	1+ to 2+ AR (n = 23)	≥3+ AR (n = 41)	p Value (F or Chi-Square)
Pre-operative (mm)				
Aortic annulus	25.4 ± 4.1	23.7 ± 3.5	25.8 ± 5.9	0.27
Sinus of Valsalva	39.4 ± 7.6	39.0 ± 8.6	41.0 ± 13.4	0.61
Sino-tubular junction	34.8 ± 8.9	34.7 ± 8.6	34.1 ± 8.9	0.93
Ascending aorta	41.6 ± 11.4	39.5 ± 8.2	37.2 ± 12.6	0.14
Height of the sinus	25.3 ± 7.5	25.4 ± 5.8	27.3 ± 11.5	0.64
Symmetry of coaptation	1.9 ± 2.2	2.3 ± 1.9	2.2 ± 2.3	0.23
Post-operative				
Aortic annulus (mm)	21.4 ± 3.8	21.0 ± 3.5	25.7 ± 4.4	<0.001
Sinus of Valsalva (mm)	29.1 ± 5.3	29.6 ± 5.0	31.4 ± 5.4	0.04
Sino-tubular junction (mm)	25.6 ± 4.1	23.9 ± 3.7	27.2 ± 3.8	<0.01
Ascending aorta (mm)	27.4 ± 5.1	27.7 ± 5.2	28.4 ± 4.6	0.47
Coaptation length (mm)	6.6 ± 2.8	3.2 ± 1.4	2.2 ± 1.6	<0.001
Coaptation length <4 mm (%)	11	52	85	<0.001
Cusp to annulus distance (mm)	-1.2 ± 2.8	-1.5 ± 3.2	-3.9 ± 4.8	<0.001
Distance from tips to annulus (mm)	6.9 ± 4.3	3.0 ± 3.1	0.6 ± 4.2	<0.001
Tips below the aortic annulus (%)	4	13	49	<0.001
Vena contracta width (mm)	0.6 ± 1.1	2.4 ± 1.7	2.6 ± 1.4	<0.001
Eccentric jet (%)	9	30	73	<0.001

Aortic root numeric model: Correlation between intraoperative effective height and diastolic coaptation

Gil Marom, MSc,^a Rami Haj-Ali, PhD,^a Moshe Rosenfeld, DSc,^a Hans Joachim Schäfers, MD,^b and Ehud Raanani, MD,^c Tel Aviv and Tel Hashomer, Israel; and Homburg, Germany

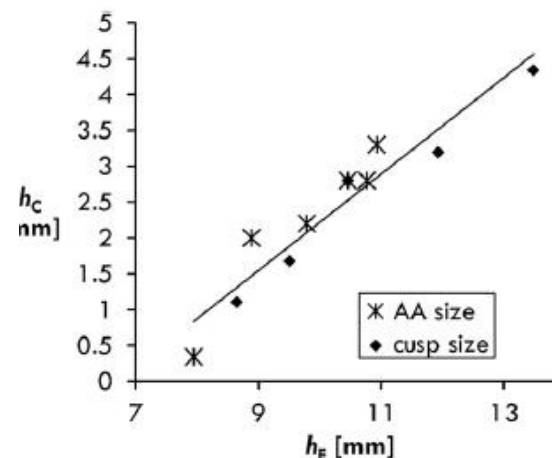
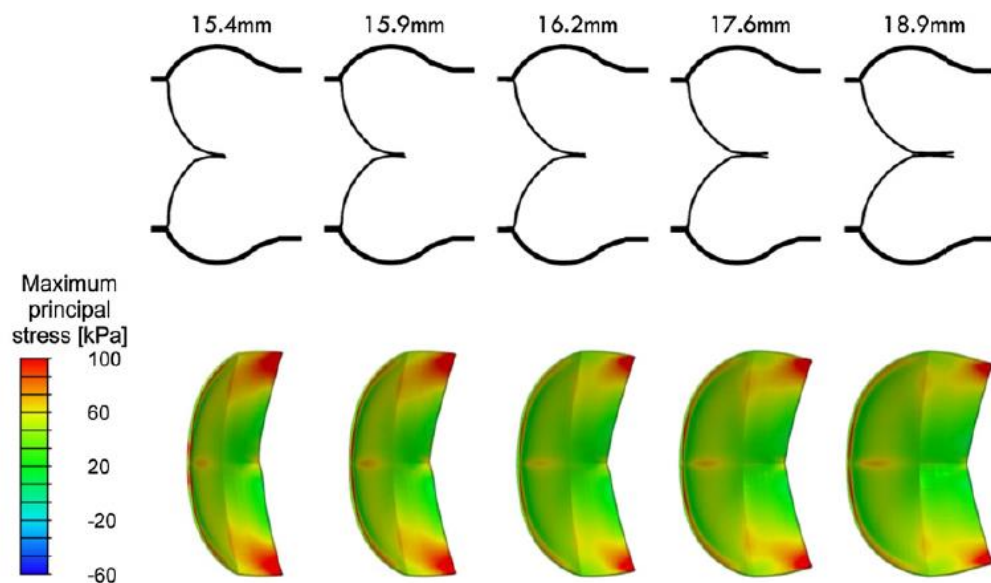
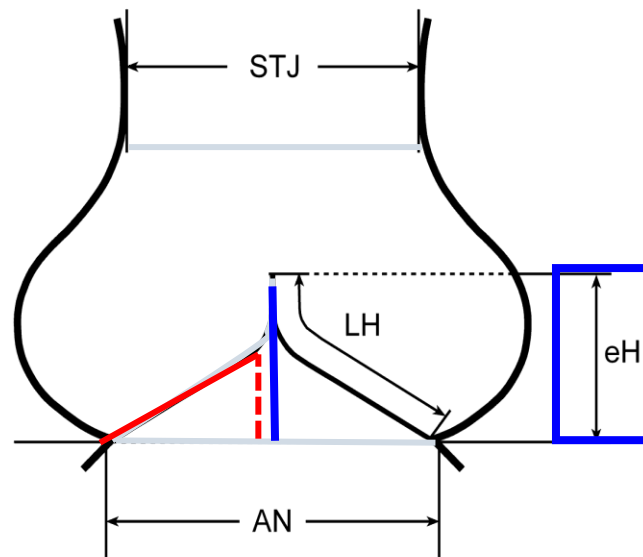
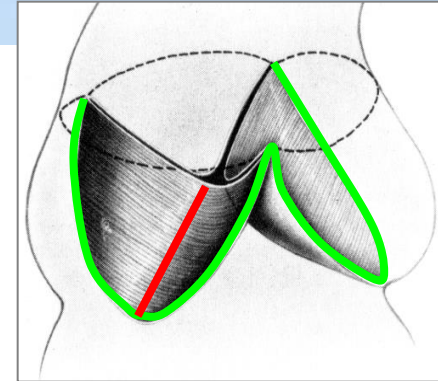


FIGURE 2. The average coaptation heights (h_C) as a function of the effective height (h_E). AA, Aortic annulus.

J Thorac Cardiovasc Surg 2013;145:303-4

Configuration/coaptation of cusps



Functional Anatomy of Aortic Regurgitation

Accuracy, Prediction of Surgical Repairability, and Outcome Implications of Transesophageal Echocardiography

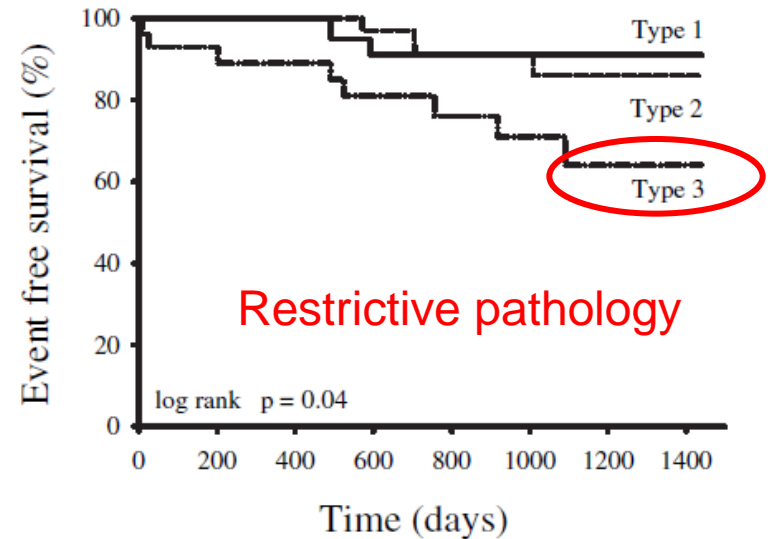
Jean-Benoît le Polain de Waroux, MD*; Anne-Catherine Pouleur, MD*; Céline Goffinet, MD; David Vancraeynest, MD; Michel Van Dyck, MD; Annie Robert, PhD; Bernhard L. Gerber, MD, PhD; Agnès Pasquet, MD, PhD; Gébrine El Khoury, MD; J

Background—For patients with aortic regurgitation (AR), aortic valve to valve replacement. In this setting, accurate preoperative de repairability is of paramount importance. The aim of the present st transesophageal echocardiography (TEE) in defining the mechani in predicting repairability, by using the final surgical approach as

Methods and Results—One hundred and sixty-three consecutive patie AR surgery were included. Mechanisms of AR were categorized aortic dilatation; type 2, cusp prolapse; and type 3, restrictive cusj AR were type 1 in 41 patients, type 2 in 62, and type 3 in 60. Agree ($\kappa=0.90$). Valve sparing or repair was performed in 125 patients predicted the final surgical approach in 108/125 (86%) patien undergoing replacement. The gross anatomic classification of AR l and postoperative outcome (4-year freedom from > grade 2 AR,

Conclusions—TEE provides a highly accurate anatomic assessment anatomy of AR defined by TEE is strongly and independently outcome. (*Circulation*. 2007;116[suppl I]:I-264–I-269.)

Key Words: echocardiography ■ surgery ■ valves ■



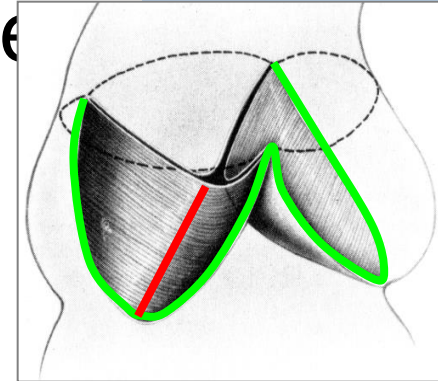
—	n = 36	22	16	8
—	n = 55	37	18	10
—	n = 30	24	14	8

Figure 4. Kaplan–Meier estimates of event-free survival in patients undergoing valve sparing or repair surgery, according to anatomic classification by TEE.

Aortic Valve Repair - Assessment

Solutions

Configuration/coaptation of cusps



Cusp height in aortic valve

Hans-Joachim Schäfers, MD,^a Wolfram S

Objectives: Successful aortic valve repair available on the normal dimensions of I

Methods: The cusp height was measure. A tricuspid anatomy was present in 329 height, weight, preoperative degree of a analyzed for possible interrelation betw

Results: In the bicuspid valves, the geom ± 2.0). Significant correlations were fo valves, the height of the noncoronary c left coronary cusp varied from 12 to 25 to 25 mm (mean, 20.0 ± 2.1). The nonco cusp ($P = .000$). No difference was fou between the geometric height and clini degree of aortic regurgitation.

Conclusions: We found the cusp height correlates with the clinical variables. Tl repair. (*J Thorac Cardiovasc Surg* 2012;

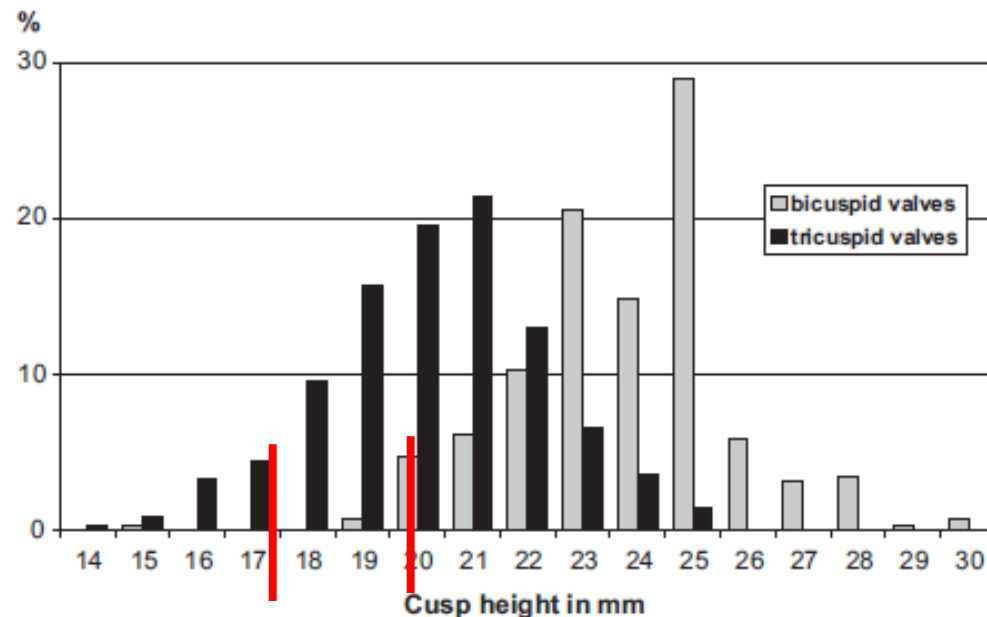
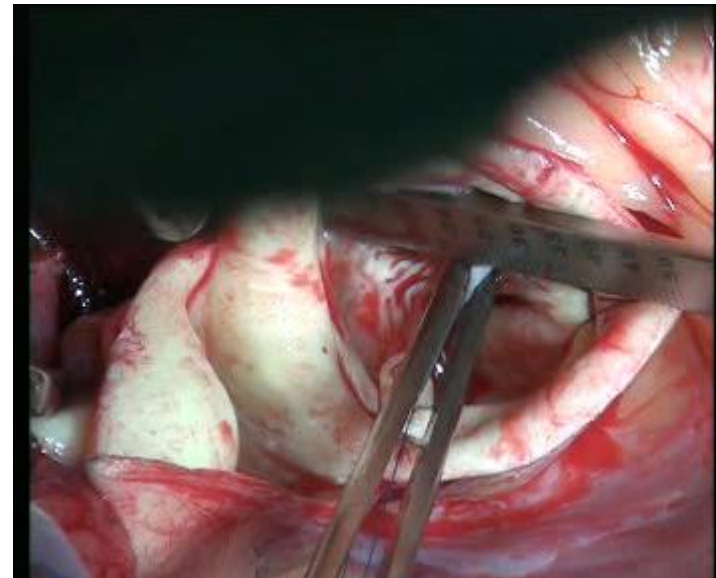
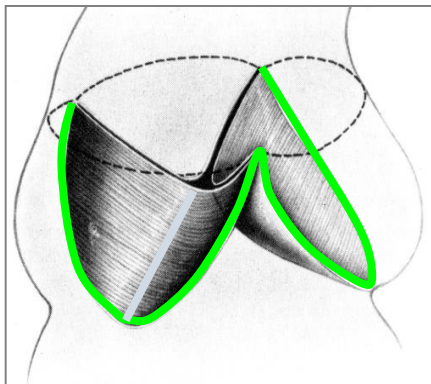


FIGURE 3. Distribution of geometric height in bicuspid (n = 289; nonfused cusps) and tricuspid (n = 332; mean of all 3 cusps) aortic valves.

Aortic Valve Repair - Assessment

Configuration/coaptation of cusps



TAV: 17-22 mm
BAV: 20-25 mm

Prolapse $n=606/826 \approx 73\%$

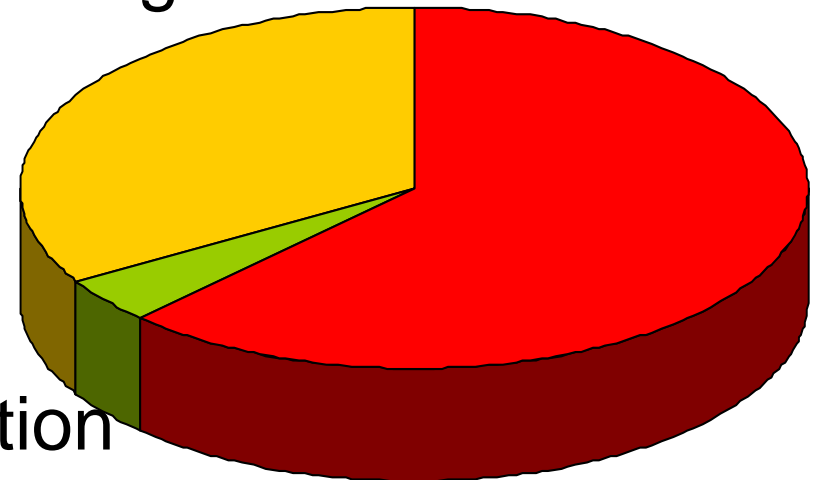
(right > non > left-coronary cusp)

Congenital malformation

- bicuspid $n=276$
- unicuspid $n=50$
- quadricuspid $n=3$

Retraction / Calcium $n=42$


Congenital

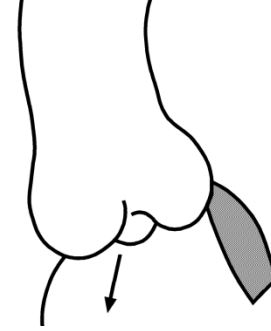


Retraction

Prolapse

Aortic valve – stress distribution

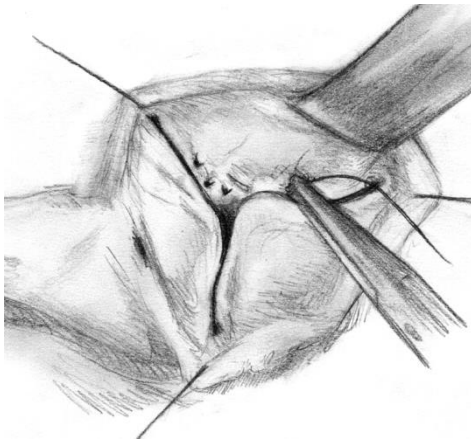




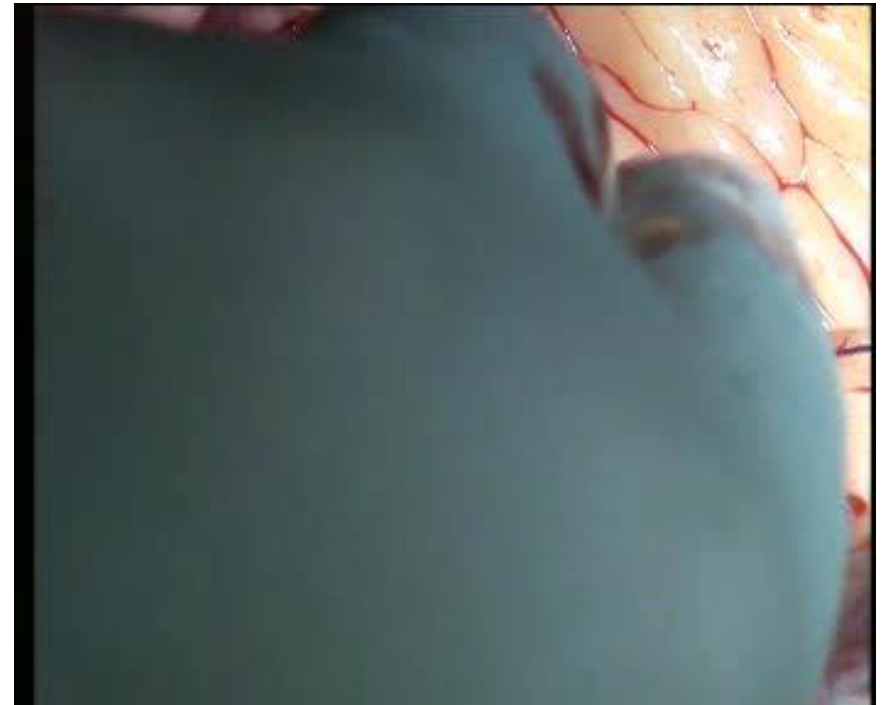Reconstructive Techniques

Cusp Pathology

Prolapse

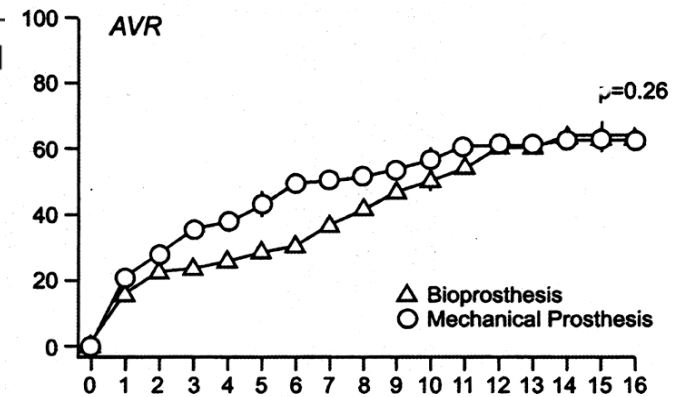
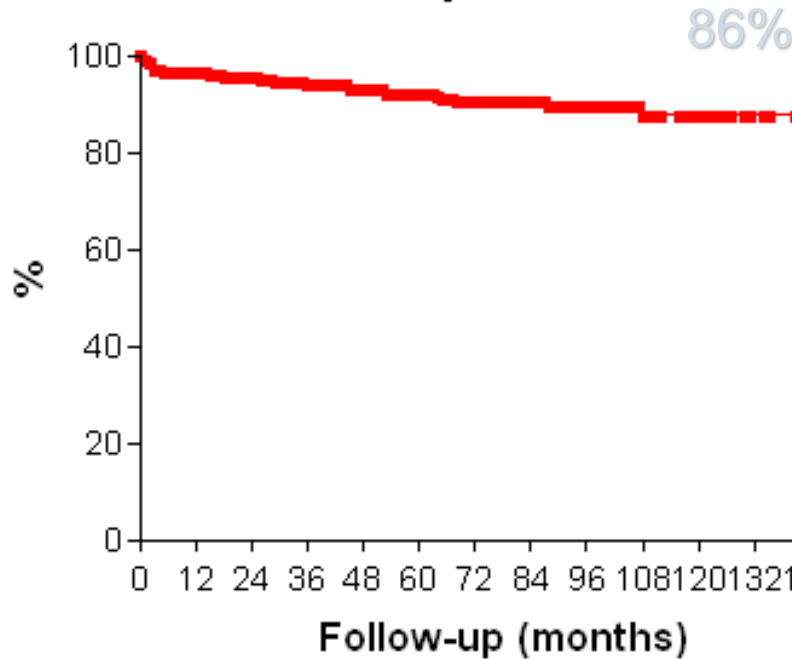


Plication of
Cusp Margin



Aortic Valve Repair

Freedom from Valve-related Complications



Hammermeister et al, JACC 2000

Valve Configuration Determines Long-Term Results After Repair of the Bicuspid Aortic Valve

Diana Aicher, Takashi Kunihara, Omar Abou Issa, Brigitte Brittner, Stefan Gräber and Hans-Joachim Schäfers

Circulation. 2011;123:178-185; originally published online January 3, 2011;
doi: 10.1161/CIRCULATIONAHA.109.934679

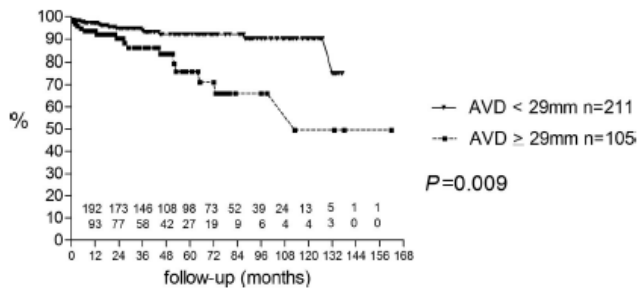
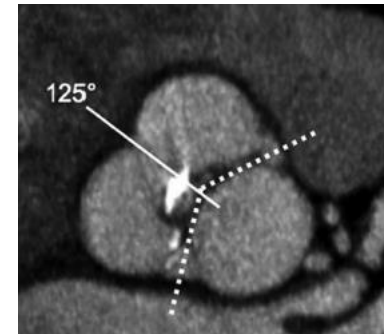
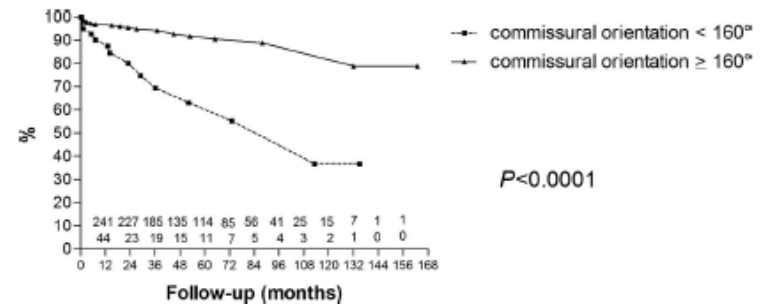


Figure 3. Actuarial freedom from reoperation after aortic valve repair in patients with a BAV depending on pre-operative AVD.



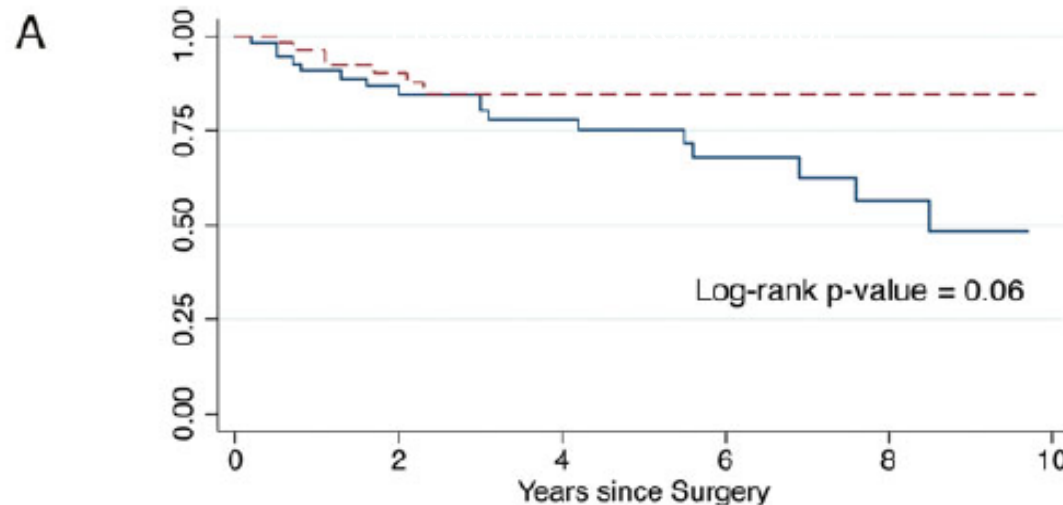
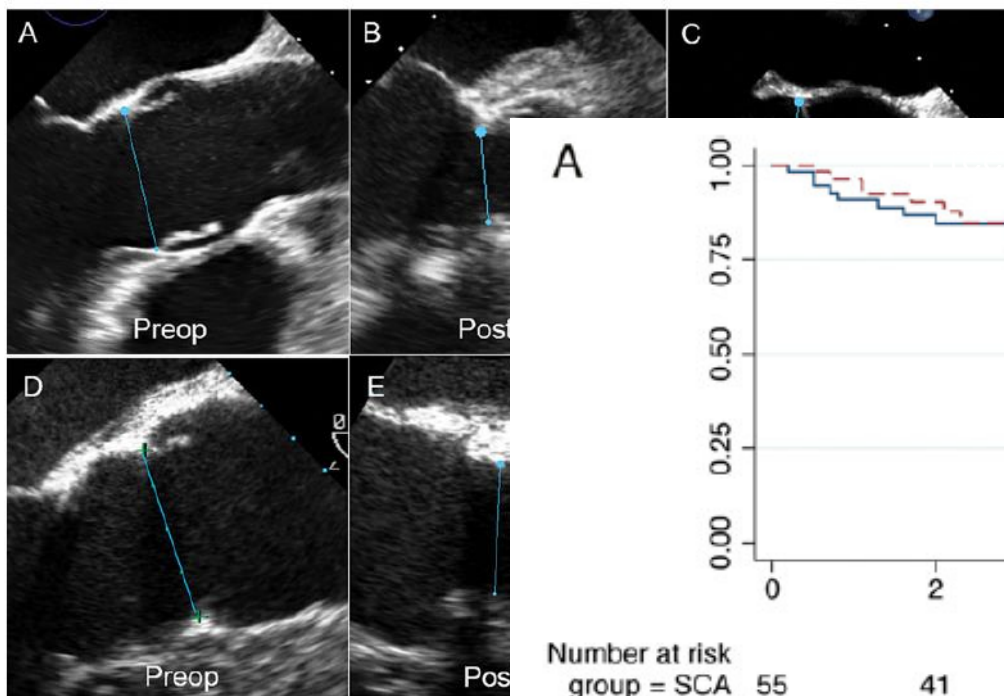
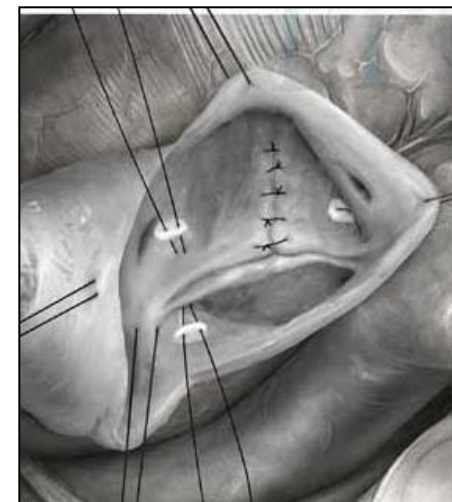
F
E
F
C

Cite this article as: de Kerchove L, Mastrobuoni S, Boodhwani M, Astarci P, Rubay J, Poncelet A *et al.* The role of annular dimension and annuloplasty in tricuspid aortic valve repair. *Eur J Cardiothorac Surg* 2016;49:428–38.

The role of annular dimension and annuloplasty in tricuspid aortic valve repair[†]

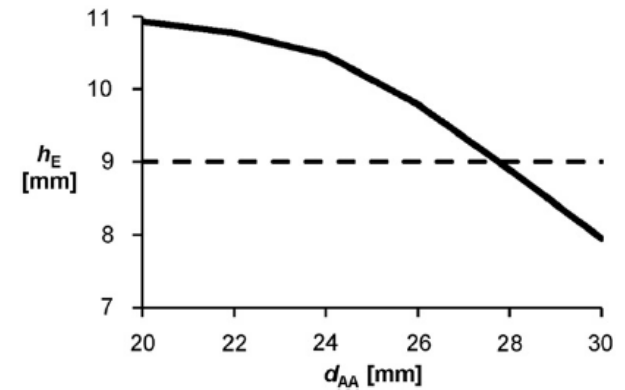
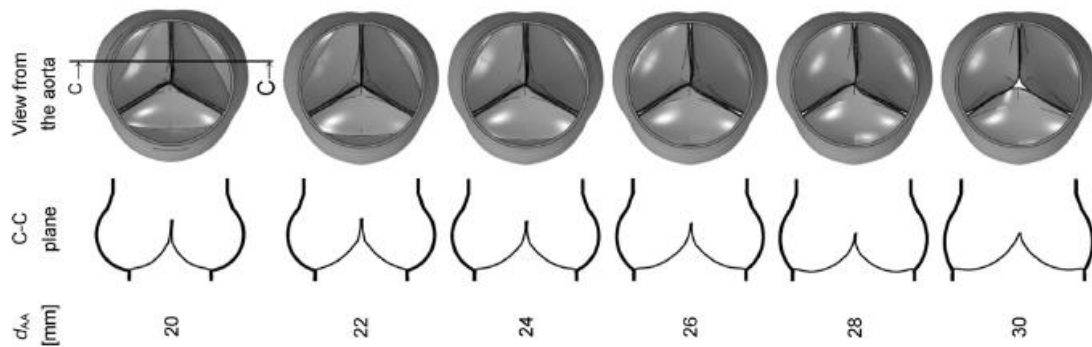
Laurent de Kerchove^{a,*}, Stefano Mastrobuoni^a, Munir Boodhwani^b, Parla Astarci^a, Jean Rubay^a, Alain Poncelet^a, Jean-Louis Vanoverschelde^{a,c}, Philippe Noirhomme^a and Gebrine El Khoury^a

^a Pôle de Recherche Cardiovasculaire, Institut de Recherche Expérimentale et Clinique, Université Catholique de Louvain and Division of Cardiothoracic and Vascular Surgery, Brussels, Belgium

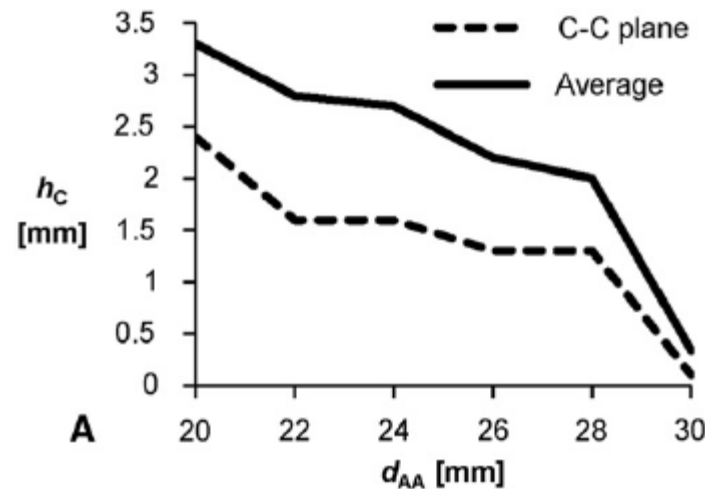


Aortic root numeric model: Annulus diameter prediction of effective height and coaptation in post-aortic valve repair

Gil Marom, MSc,^a Rami Haj-Ali, PhD,^a Moshe Rosenfeld, DSc,^a Hans Joachim Schäfers, MD,^b and Ehud Raanani, MD^c



E 2. The effective height (h_E) as a function of annulus diameter under a pressure load of 3 mm Hg.



Remodeling root repair with an external aortic ring annuloplasty

Emmanuel Lansac, MD, PhD,^a Isabelle Di Centa, MD,^b Ghassan Sleilaty, MD,^a Stephanie Lejeune, MS,^a Alain Berrebi, MD,^a Pavel Zacek, MD, PhD,^c and Mathieu Debauchez, MD^a



TABLE 3. Influence of different parameters on late outcomes

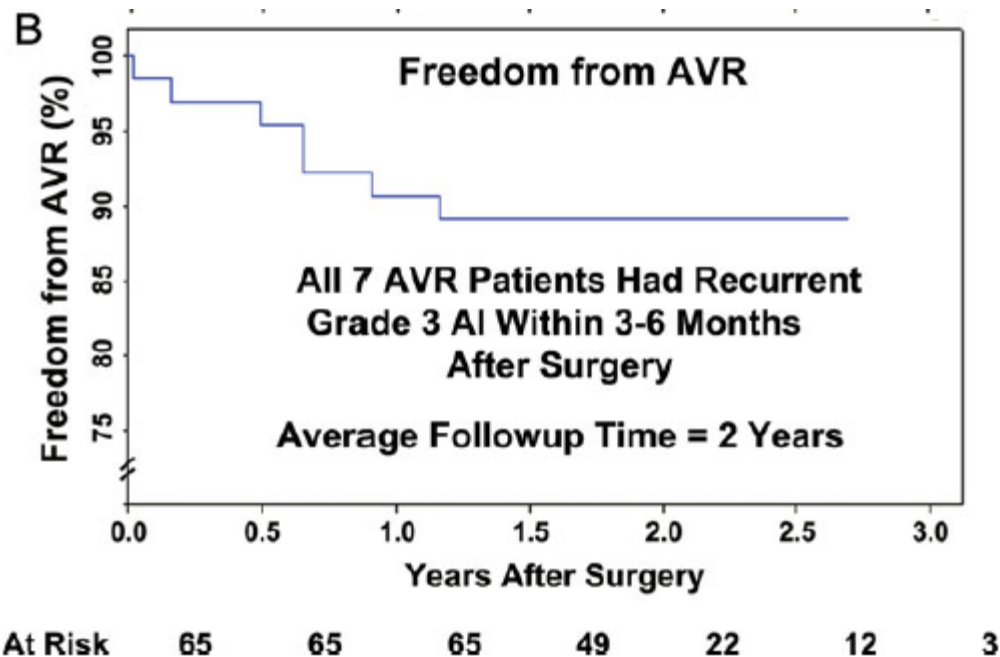
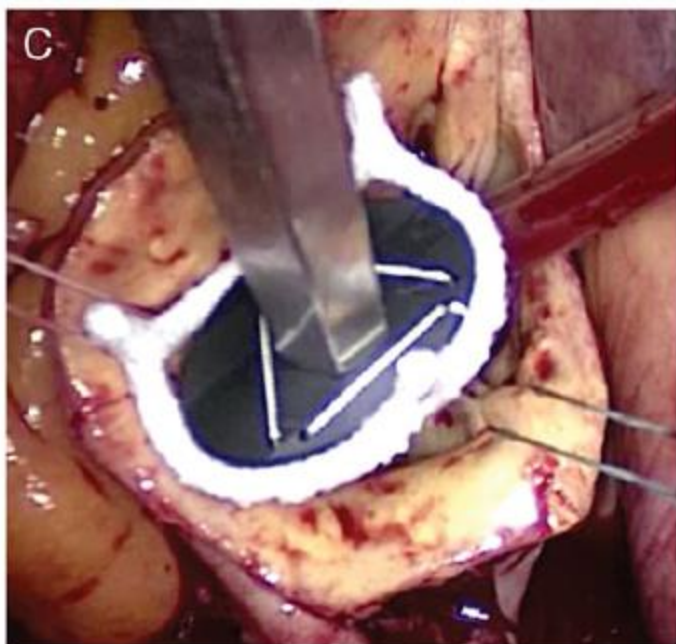
Outcome Factor	Freedom from AI ≥ 2		Freedom from AI ≥ 3		AV reintervention		MAVRE	
	HR, 95% CI	P value	HR, 95% CI	P value	HR, 95% CI	P value	HR, 95% CI	P value
Cusp effective height assessment	0.96 (0.37-2.50)	.939	-†	.043	0.13 (0.02-1.06)	.057	0.20 (0.05-0.76)	.018
Cusp repair	1.23 (0.47-3.25)	.676	0.46 (0.08-2.53)	.374	0.43 (0.10-1.84)	.257	0.52 (0.17-1.57)	.243
Extra-Aortic ring (Extra-Aortic, CORONEO, Inc, Montreal, QC, Canada)	1.5 (0.57-3.96)	.414	-†	.026	0.11 (0.01-0.95)	.044	0.29 (0.09-0.98)	.046
Leaflet anatomy		.281	†	.149		.151		.262
Tricuspid	Reference	-	Reference	-	Reference	-	Reference	-
Bicuspid	0.82 (0.26-2.57)	.737	-†		-†		0.18 (0.02-1.4)	.102
Unicuspid	3.07 (0.68-13.75)	.143	3.37 (0.39-28.9)	.267	-†		0	.983
Preoperative AI*	1.66 (1.1-2.51)	.016	1.63 (0.78-3.44)	.196	0.94 (0.53-1.65)	.824	0.98 (0.64-1.5)	.939
Intraoperative Aortic annulus diameter	1.02 (0.91-1.15)	.693	0.84 (0.51-1.38)	.493	0.88 (0.59-1.3)	.516	0.85 (0.62-1.16)	.303
Valsalva diameter	0.99 (0.94-1.05)	.853	1.00 (0.92-1.09)	.987	1.03 (0.98-1.09)	.268	1.02 (0.97-1.07)	.527
STJ diameter	1.03 (0.99-1.08)	.122	1.01 (0.93-1.1)	.778	1.01 (0.93-1.09)	.883	1.01 (0.95-1.07)	.676
Preoperative LVEF	0.97 (0.93-1.02)	.248	1.04 (0.93-1.16)	.462	1.04 (0.94-1.15)	.461	1.09 (1.00-1.18)	.042

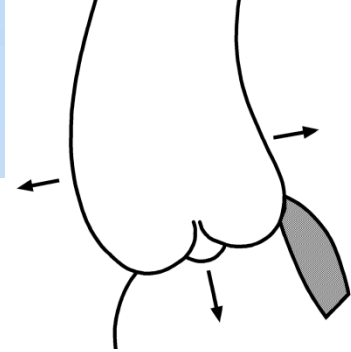
(J Thorac Cardiovasc Surg 2017; ■:1-10)

Cite this article as: Mazzitelli D, Fischlein T, Rankin JS, Choi Y-H, Stamm C, Pfeiffer S *et al.* Geometric ring annuloplasty as an adjunct to aortic valve repair: clinical investigation of the HAART 300 device. *Eur J Cardiothorac Surg* 2016;49:987–93.

Geometric ring annuloplasty as an adjunct to aortic valve repair: clinical investigation of the HAART 300 device

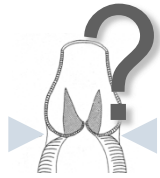
Domenico Mazzitelli^a, Theodor Fischlein^b, J. Scott Rankin^{c,*}, Yeong-Hoon Choi^d, Christof Stamm^e, Steffen Pfeiffer^b, Jan Pirk^f, Christian Detter^g, Johannes Kroll^h, Friedhelm Beyersdorf^h, Charles D. Griffinⁱ, Malakh Shrestha^j, Christian Nöbauer^a, Philip S. Crooke^k, Christian Schreiber^a and Rüdiger Lange^a





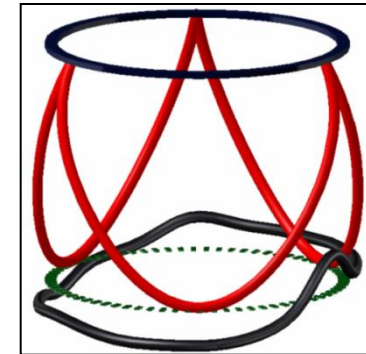
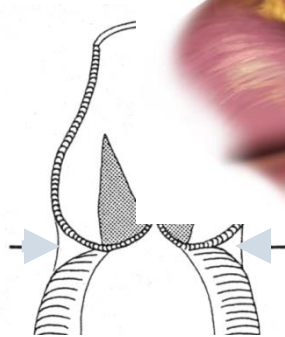
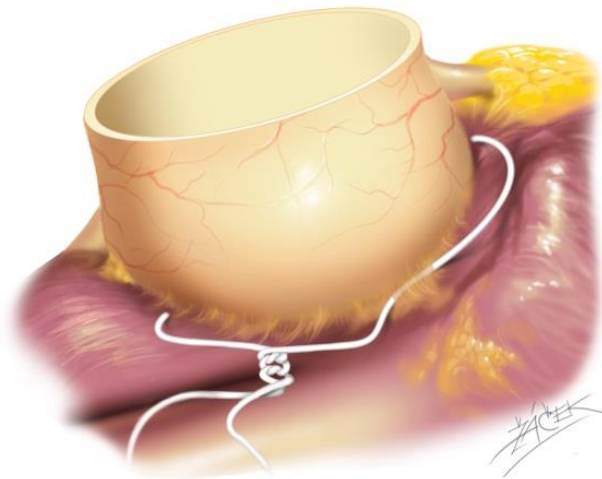
Root Repair – Technical Options

Subcommissural Plication



(Cabrol 1966)

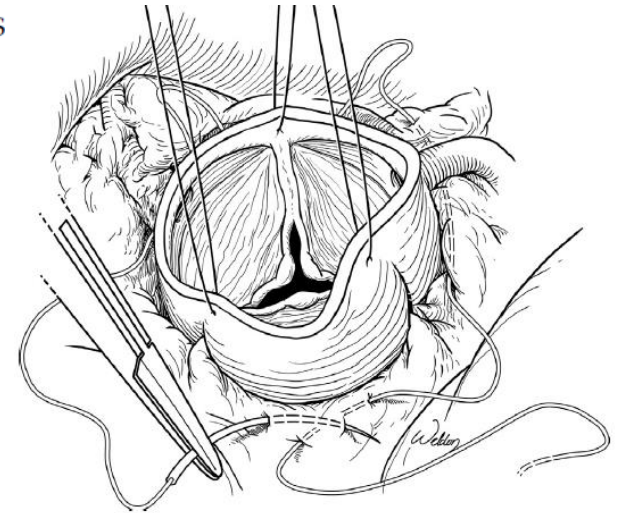
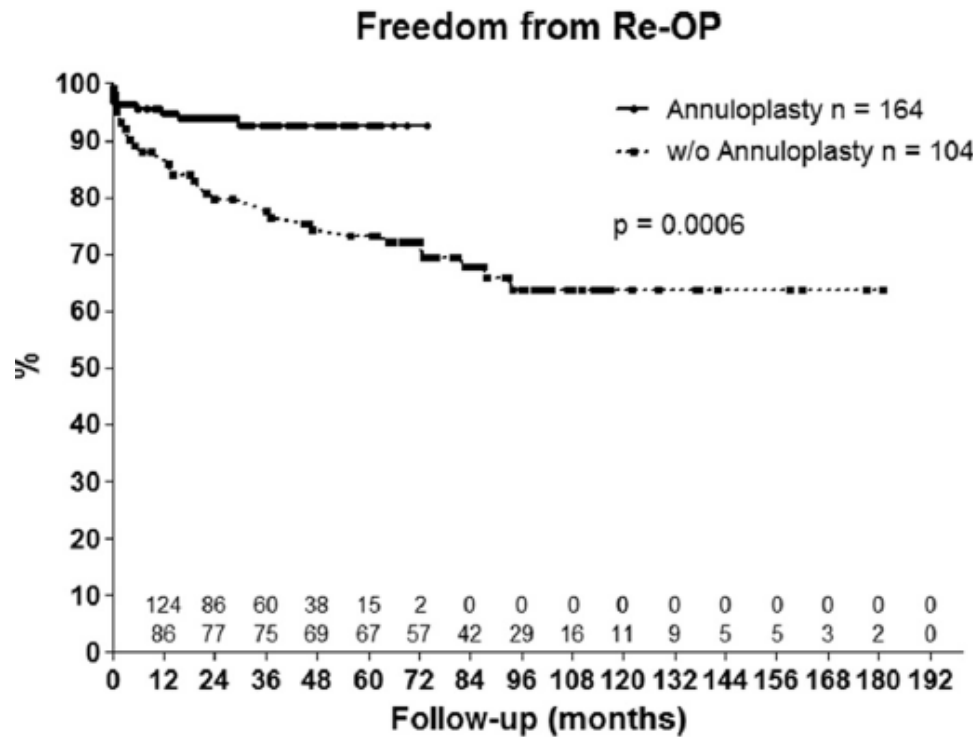
Aortic Annuloplasty (AVJ > 25-27mm)

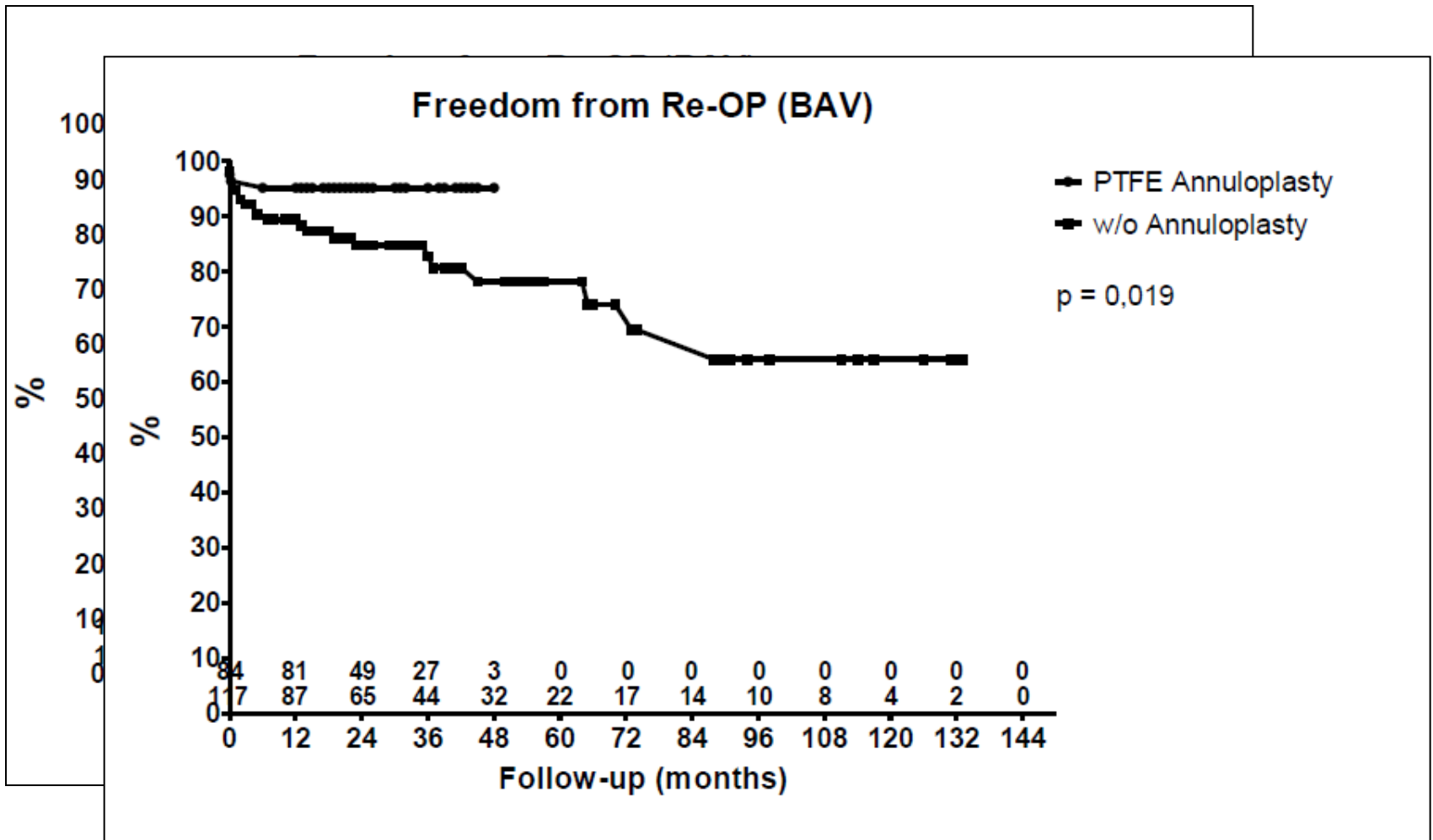


Suture Annuloplasty Significantly Improves the Durability of Bicuspid Aortic Valve Repair

Ulrich Schneider, MD, Christopher Hofmann, Diana Aicher, MD, Hiroaki Takahashi, MD, Yujiro Miura, MD, and Hans-Joachim Schäfers, MD

Department of Thoracic and Cardiovascular Surgery, Saarland University Medical Center, Homburg/S





Freedom from Reoperation – all BAV

Predictors of Failure

	p univar.	p multivar.
Patient age < 40 yrs.	0.0051	0.001
Orientation of comm. (<160°)	0.0001	0.002
Non-root replacement	0.0018	
Cabrol suture	0.04	
Pericardial patch	0.0001	0.0001
AV diameter (>28 mm)	0.0005	0.007
ST diameter (≤ 30 mm)	0.0142	
Effective height < 9mm	0.0013	0.002
Preop AR > III	0.0029	



Aortic Valve Reconstruction

AV reconstruction is on its way to a rational and reproducible approach (A + B + C + ? = functioning AV)

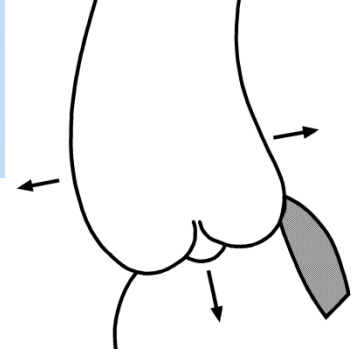
Scientific basis is becoming clearer

Valve-related complications are rare if repair is stable

AV reconstruction should be considered in every patient with AR

Thank you for your attention





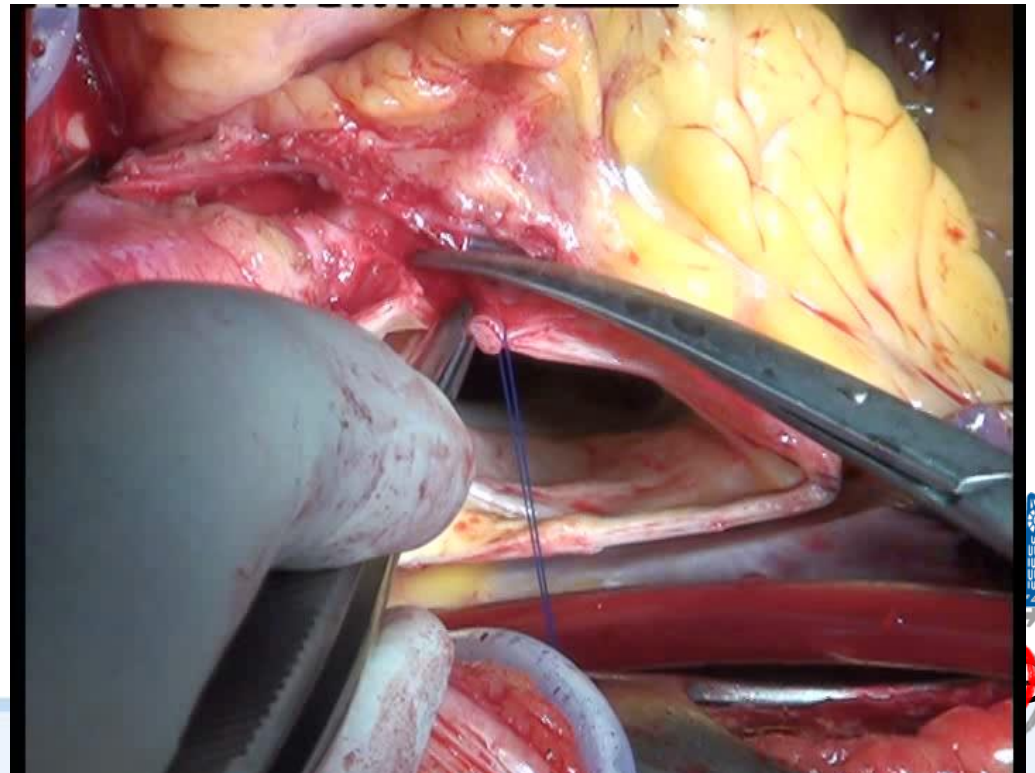
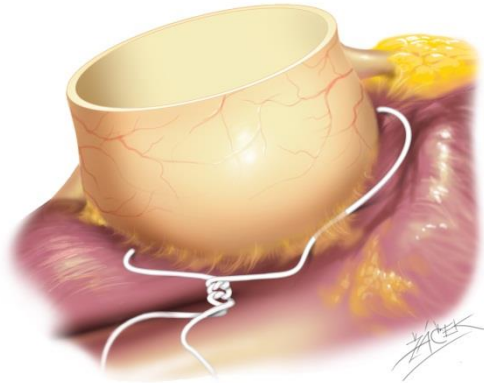
Root Repair – Technical Options

Aortoventricular Stabilisation (AVJ > 27mm)

Subcommissural Plication



(Cabrol 196)



Aortic root numeric model: Annulus diameter prediction of effective height and coaptation in post-aortic valve repair

Gil Marom, MSc,^a Rami Haj-Ali, PhD,^a Moshe Rosenfeld, DSc,^a Hans Joachim Schäfers, MD,^b and Ehud Raanani, MD^c

Objective: The aim of the present study was to determine the influence of the aortic annulus (AA) diameter in order to examine the performance metrics, such as maximum principal stress, strain energy density, coaptation area, and effective height in the aortic valve.

Methods: Six cases of aortic roots with an AA diameter of 20 and 30 mm were numerically modeled. The coaptation height and area were calculated from 3-dimensional fluid structure interaction models of the aortic valve and root. The structural model included flexible cusps in a compliant aortic root with material properties similar to the physiologic values. The fluid dynamics model included blood hemodynamics under physiologic diastolic pressures of the left ventricle and ascending aorta. Furthermore, zero flow was assumed for effective height calculations, similar to clinical measurements. In these no-flow models, the cusps were loaded with a transvalvular pressure decrease. All other parameters were identical to the fluid structure interaction models.

Results: The aortic valve models with an AA diameter range of 20 to 26 mm were fully closed, and those with an AA diameter range of 28 to 30 mm were only partially closed. Increasing the AA diameter from 20 to 30 mm decreased the averaged coaptation height and normalized cusp coaptation area from 3.3 to 0.3 mm and from 27% to 2.8%, respectively. Increasing the AA diameter from 20 to 30 mm decreased the effective height from 10.9 to 8.0 mm.

Conclusions: A decreased AA diameter increased the coaptation height and area, thereby improving the effective height during procedures, which could lead to increased coaptation and better valve performance. (J Thorac Cardiovasc Surg 2012; ■:1-6)

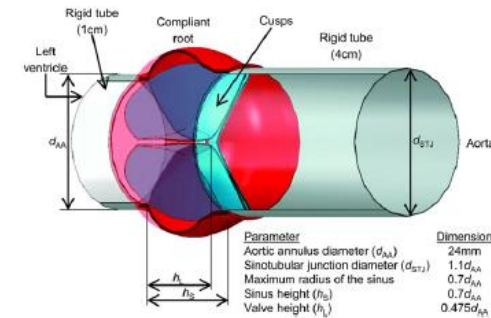


FIGURE 1. A schematic view of the aortic valve healthy model showing the compliant region and the added rigid tubes.

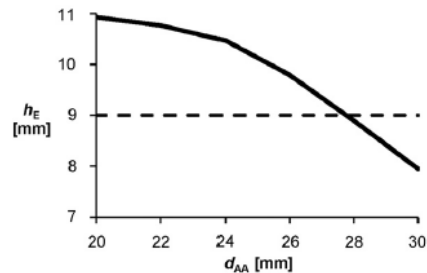


FIGURE 2. The effective height (h_E) as a function of annulus diameter (d_{AA}) under a pressure load of 3 mm Hg.

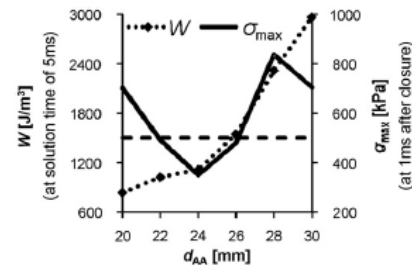
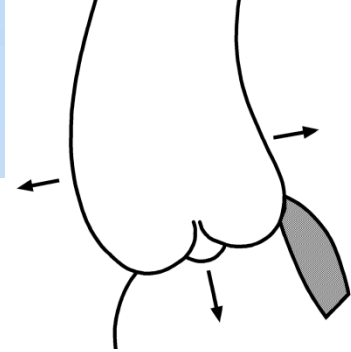


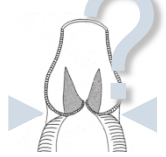
FIGURE 5. Comparison of energy density (W) and the maximum principal stress (σ_{max}) for the various annulus diameters (d_{AA}). The dashed line indicates the $\sigma_{max} = 500$ kPa.



Root Repair – Technical Options

Aortoventricular Plication (AVJ > 27mm)

Subcommissural Plication



(Cabrol 1966)

