



UKS
Universitätsklinikum
des Saarlandes

Root Remodeling should be Preferred over Valve Reimplantation

28.04.2016

H.-J. Schäfers

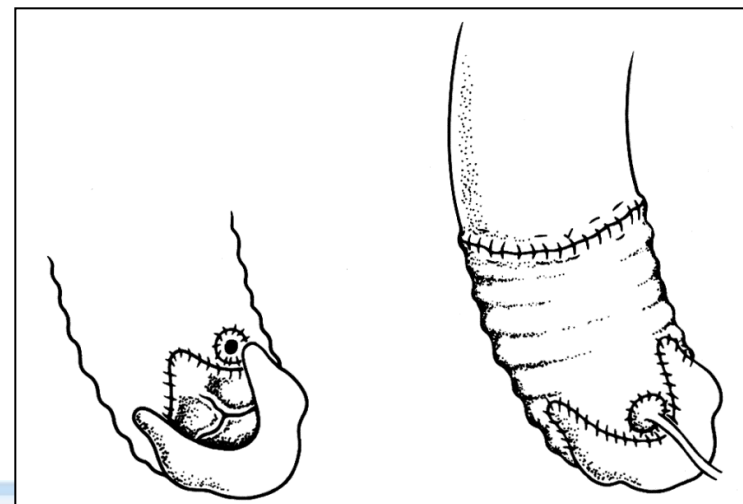
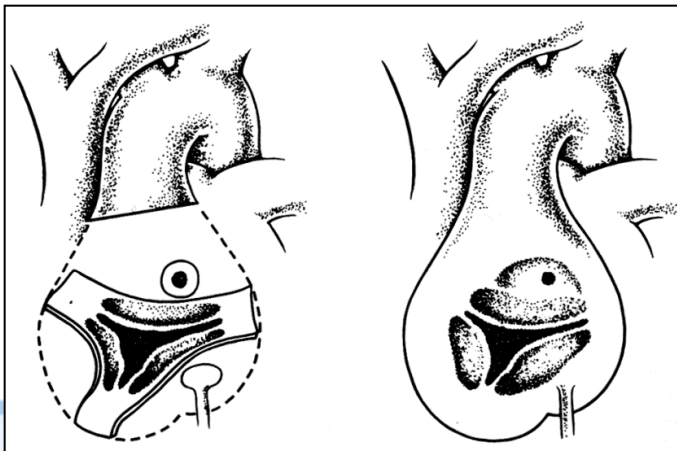
Dept. of Thoracic and Cardiovascular Surgery
Saarland University Medical Center
Homburg/ Saar, Germany

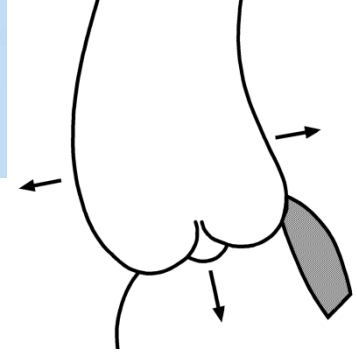
Titel des Vortrags und Verfasser (bitte im Folienmaster anpassen)

Remodeling of the aortic valve anulus

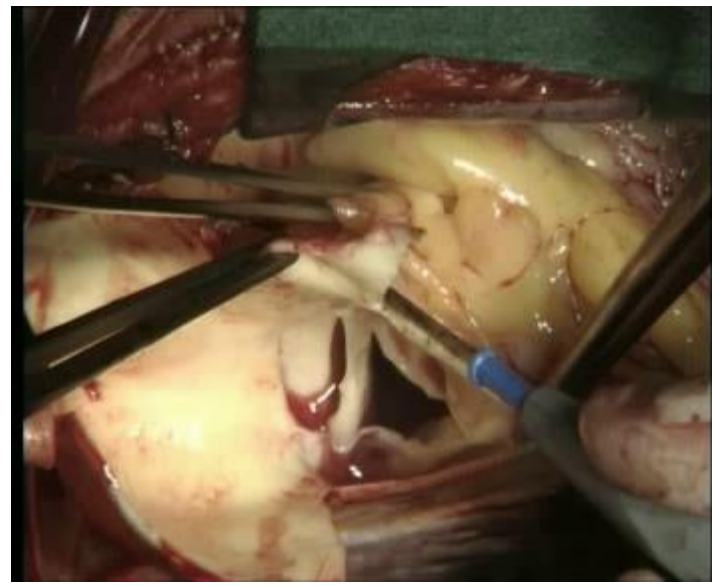
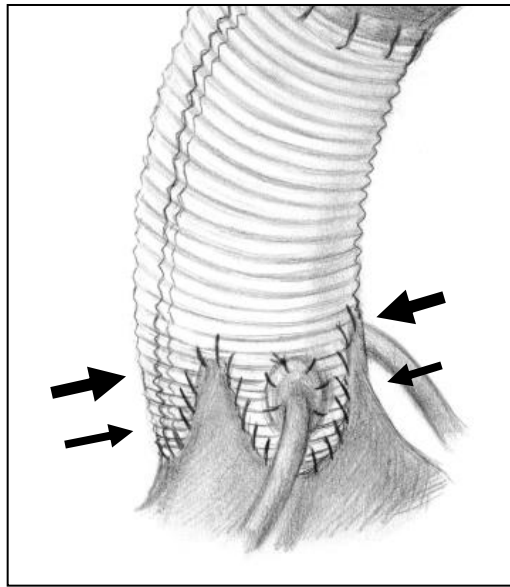
Isolated aortic valve regurgitation that results from disease that primarily affects the aortic wall can be repaired by remodeling of the aortic anulus to restore its normal geometry. This involves excision of the aortic wall to within 2 to 3 mm of the leaflet attachments, detachment of the coronary ostia, reshaping of the anulus with the aid of a Dacron graft, and then reimplantation of the coronary arteries. Increases in the surface area of the leaflet that are caused by root dilatation are often present and can be accommodated in the repair procedure. In this study we describe our experience with 10 patients with annuloaortic ectasia who underwent the remodeling procedure at the National Heart Hospital and the Royal Brompton Hospital from 1982 to 1990. (J THORAC CARDIOVASC SURG 1993;105:435-8)

Mazin A. I. Sarsam, FRCS, and Magdi Yacoub, FRCS,* *London, England*





Root Remodeling



(Yacoub 1988)
(Sinus > 45 mm TEE)

Titel des Vortrags und Verfasser (bitte im Folienmaster anpassen)

Valve-sparing surgery: Long-term results

David JTCVS 2006

	Freedom from AR > II (10 years)	Freedom from reoperation (10 years)
Reimplantation (n=167)	94%	96%
Remodeling (n=53)	75%	93%

Yacoub JTCVS 1998

	Freedom from AR \geq II (10 years)	Freedom from reoperation (10 years)
Remodeling (n=158)	64%	89%



Aortic Valve Repair

Valve-Sparing Operation in Aortic Root Ectasia

Hans-Joachim Schäfers and Hans G. Borst

Aortic valve regurgitation caused by aortic root ectasia is a common finding.^{1,2} The most common cause for this pathological complex is a diffuse degenerative process of connective tissue involving the media of the aortic wall, such as in Marfan's syndrome. Fragmentation and disarray of elastic fibers, formally described as cystic media necrosis, leads to hyperelasticity and decreased mechanical stress resistance. In addition to Marfan's syndrome, root ectasia has also been observed in other patients with or without apparent association to connective tissue disease.³

The risk of dissection or rupture of the ascending aorta and left ventricular volume overload caused by aortic regurgitation define the need for surgical intervention in patients with advanced stages of the disease. Insertion of a valved conduit is still regarded the gold standard for treatment of root ectasia.^{4,5} However, despite favorable perioperative results, the typical long-term risks of allprosthetic valve replacement

ated fibrous parts of the aortic root are preserved and resuspended within a vascular graft. Compared with mechanical prostheses, the long-term risks and disadvantages of anticoagulation are avoided. Originally, this operation was proposed for elective correction of root ectasia. We have also used it in root ectasia in conjunction with acute or chronic type I aortic dissection.

Indications for Surgery

In most patients, the decision for surgical intervention is made on the basis of the diameters of the aortic root and/or ascending aorta. A diameter of more than 5 cm has been shown to be associated with an increased risk of perforation or dissection and has been the standard cut-off point for decision making in replacement of the ascending aorta. Clinical observations indicate that, in patients with connective tissue disease (eg, Marfan syndrome) or familial history of aortic dissection, an

Operative Techniques in Cardiac & Thoracic Surgery —A Comparative Atlas—

Editors - James L. Cox, MD Thoralf M. Sundt III, MD

Vol 1, No 1

July 1996

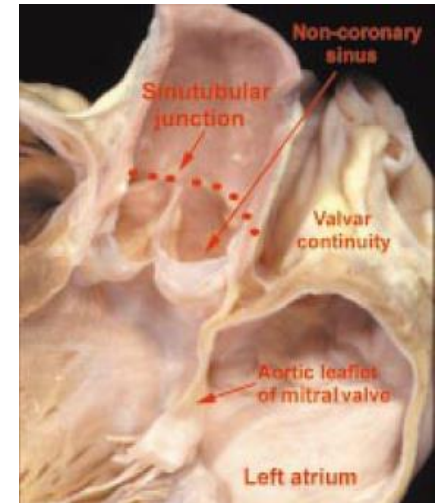
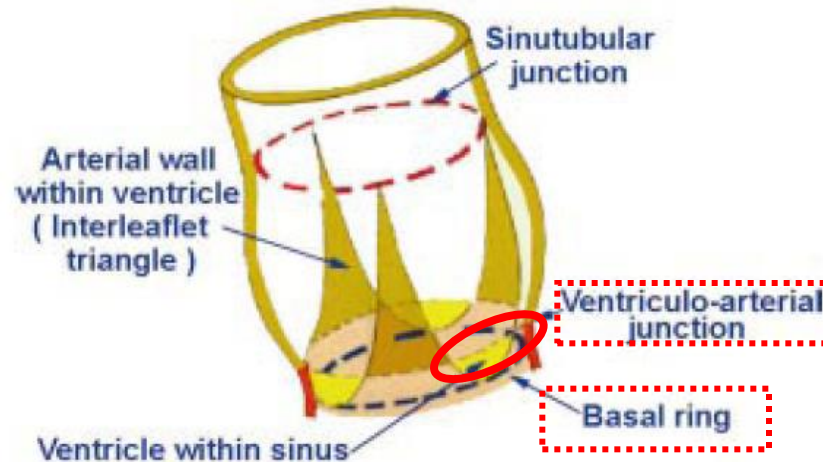
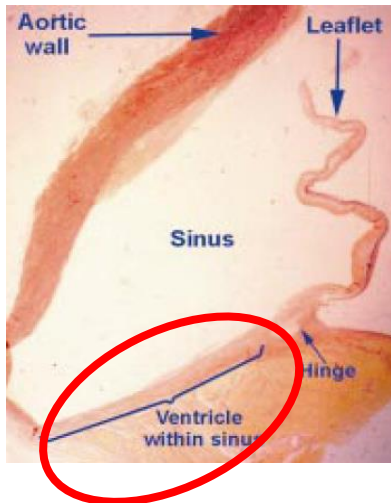
Aortic Valve Repair

- 1 **Operative Techniques in Cardiac & Thoracic Surgery:
A Comparative Atlas**
- 2 **Introduction**
- 3 **Surgical and Pathological Anatomy of the Aortic Valve and Root**
Anton E. Becker
- 15 **Aortic Valve Repair and Reconstruction**
Carlos M.G. Duran
- 30 **Aortic Valve Repair**
Delos M. Cosgrove and Charles D. Fraser
- 38 **Valve-Sparing Operation in Aortic Root Ectasia**
Hans-Joachim Schäfers and Hans G. Borst
- 44 **Remodeling the Aortic Root and Preservation of the Native
Aortic Valve**
Tirone E. David
- 57 **Valve-Conserving Operation for Aortic Root Aneurysm or
Dissection**
Sir Magdi Yacoub
- 68 **Technique of Aortic Valve Preservation in Acute Type A Aortic
Dissection**
Kwok L. Yun and D. Craig Miller



Aortic Sinus Anatomy

Titel des Vortrags und Verfasser (bitte im Folienmaster anpassen)



Crescents of LV muscle at base of (left and) right sinus (variable)

Aortic Valve Repair

VALVE-PRESERVING REPLACEMENT OF THE ASCENDING AORTA: REMODELING VERSUS REIMPLANTATION

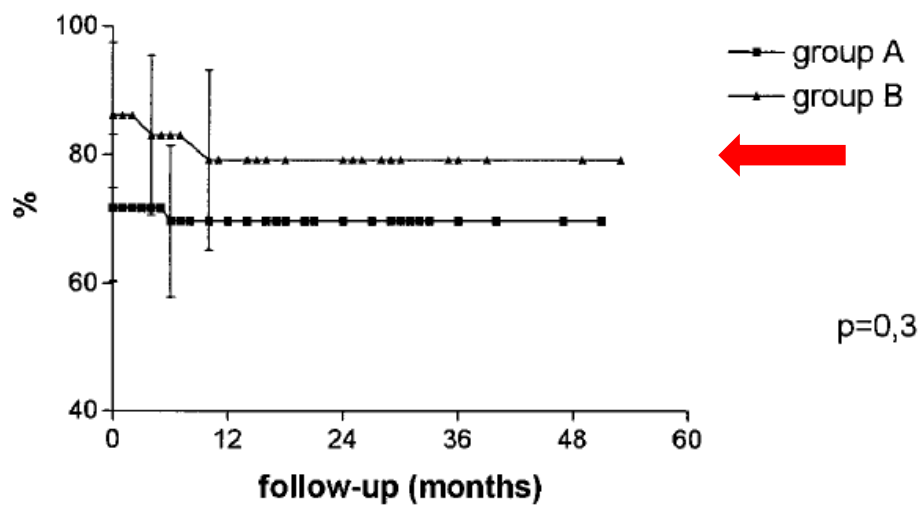
H.-J. Schäfers, MD, PhD^a
R. Fries, MD^b
F. Langer, MD^a
N. Nikoloudakis, MD^a
T. Graeter, MD^a
U. Grundmann, MD^c

Objective: Aortic valve regurgitation in combination with dilatation of the ascending aorta and root requires a combined procedure to restore valve function and eliminate pathologic dilatation of the proximal aorta. Two techniques have been proposed for this purpose; the aortic root may be either remodeled with an especially configured vascular graft or replaced with reimplantation of the aortic valve within the graft. We have used both techniques depending on the individual pathologic condition of the aortic root. **Methods:** Of 107 patients undergoing operation for proximal aortic disease between October 1995 and November 1997, 40 patients had morphologically intact aortic valve leaflets in conjunction with dilatation of the aortic root. Of these, 15 patients underwent an operation as a surgical emergency for acute aortic dissection type A.

(J Thorac Cardiovasc Surg 1998;116:990-6)



Titel des Vortrags und Verfasser (bitte im Folienmaster anpassen)



Individuals at risk

A:	60	30	18	8	2
B:	36	18	12	4	2

Figure 4. Freedom from aortic regurgitation of grade 1 or greater. *Error bars* represent 95% confidence intervals ($P > .2$).

Preserv

Hans-Joach
and Hennir

Department of T

Background. A common reason for aortic dilation after valve repair has been observed. We have observed that different repair techniques used different

Methods. Between 1990 and 2000, 100 patients with regurgitant bicuspid aortic valve were treated. The aorta was repaired with an isolated repair. The aortic root was replaced at the supra-annular level (n = 50) or at the sub-annular level (n = 50). In 50 patients, aortic dilation was observed by root remodeling.

Results. Hospital mortality was low. Aortic dilation was significant

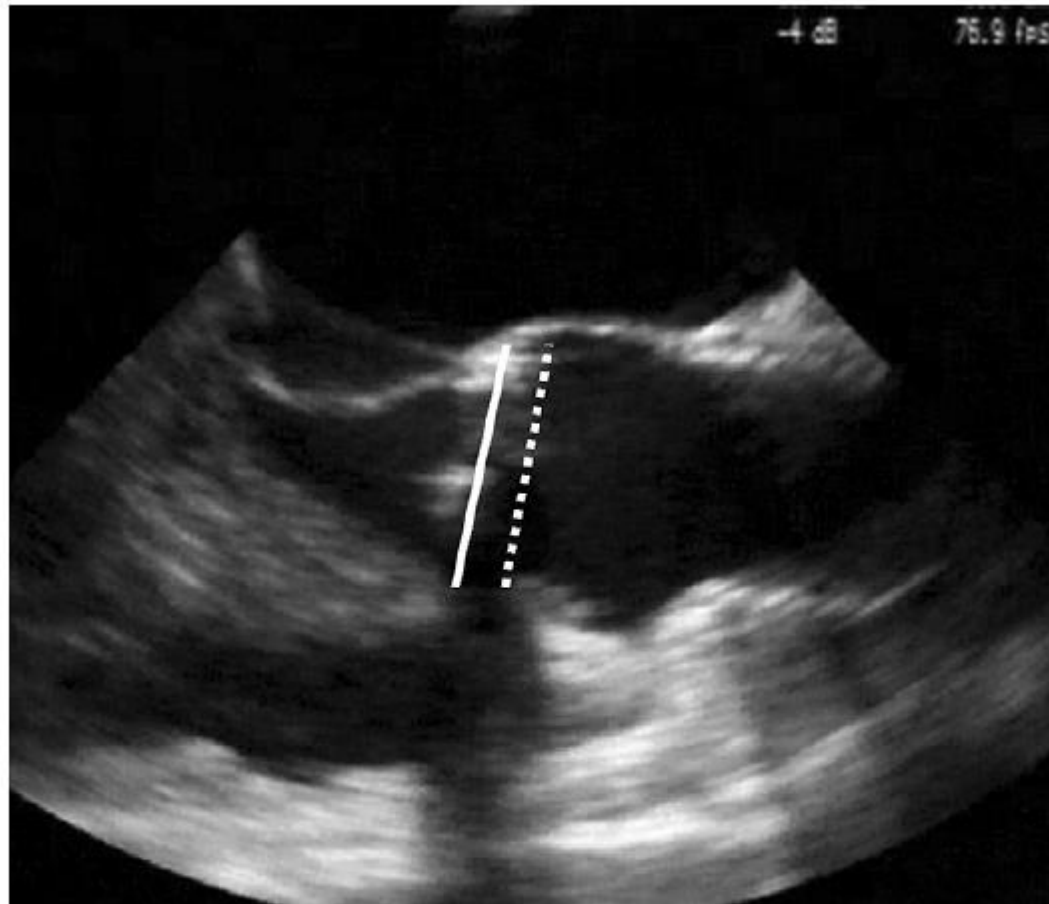


Fig 5. Typical echocardiogram of a patient with symmetric prolapse after separate valve repair and aortic replacement. The dotted line marks the coaptation level of the free margins, the solid line, the level of the aortic insertion. The most striking finding is an abnormally low height difference of 4 mm between central cusps and aortic insertion.

Outcome from aortic replacement between 91% and 97% at 5 years was 97% survival plus aortic valve repair plus aortic valve replacement was the most

Outcome from bicuspid aortic valve repair of aortic pathologic root remodeling in patients with bicuspid aortic valve repair complex alternated if the as-

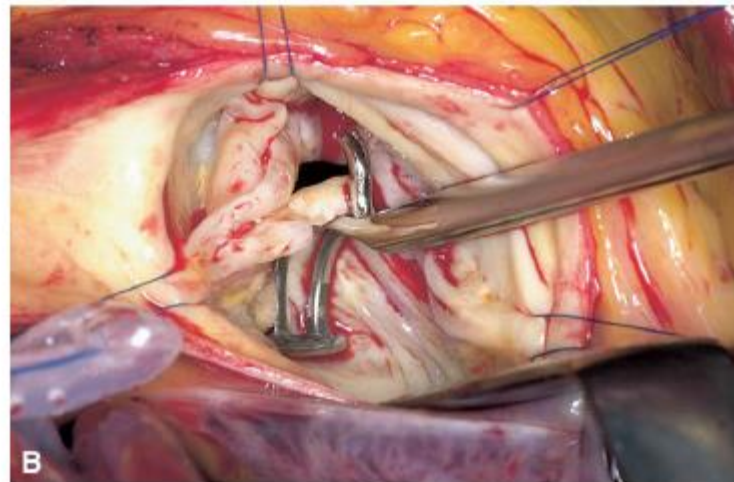
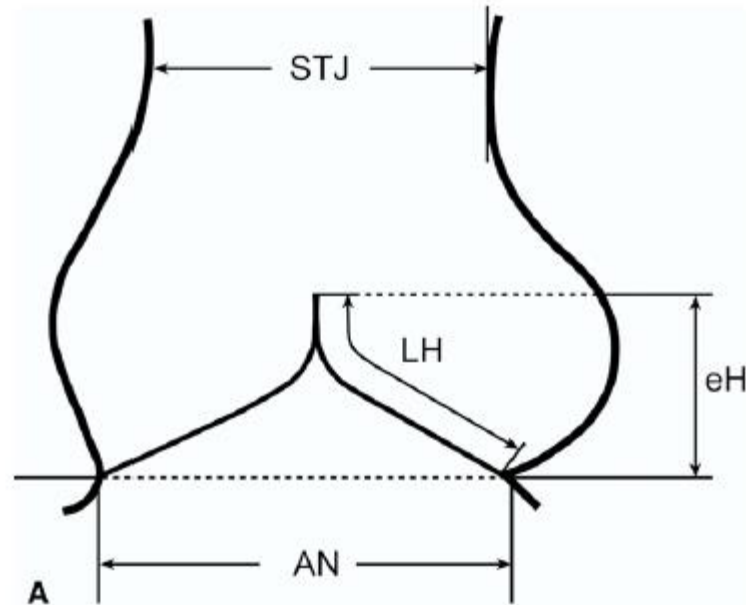
Annals of Thoracic Surgeons 2007;83:S740-5)

A new approach to

Hans-Joachim Schäfers, MD, PhD

Repair of the aortic valve is the treatment of aortic regurgitation. The aortic valve can be repaired by dilatation, or a combination of reconstruction, all pathologic conditions addressed. Good results have been achieved with aortic replacement,¹ but isolated aortic cusp repair (for prolapse) still remains a challenge.

The main problem in repair of aortic valve pathology is the repair result. Results can be quantified preoperatively by means of echocardiographic measurements. Cusp geometry is an important factor in



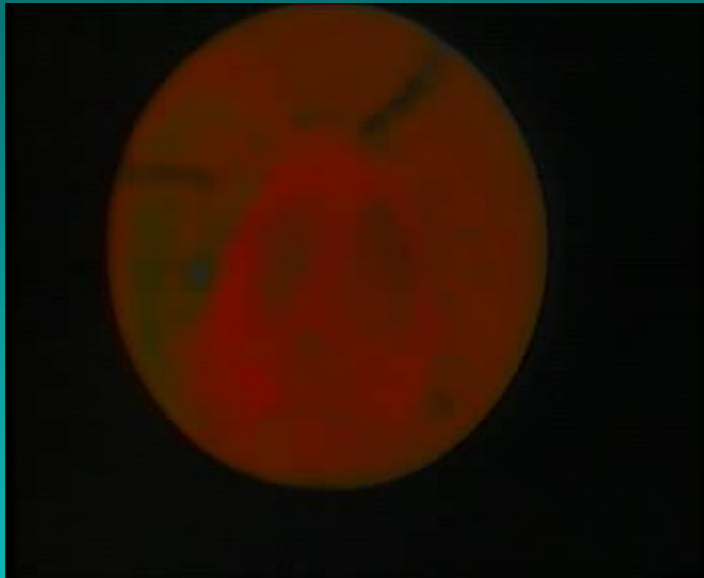metry

rg/Saar, Germany

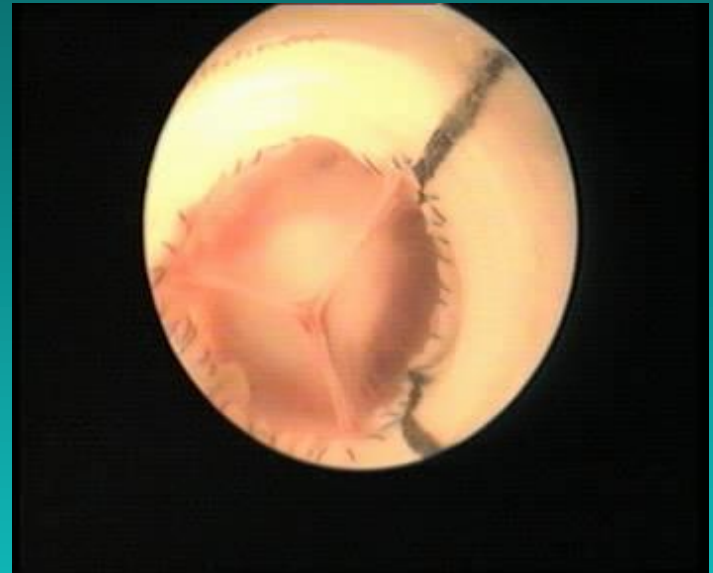
Standardize intraoperatively, and these measurements are only in conjunction with

a normal aortic valve is not only a function of the leaflet height but also the configuration of the cusps. A slight difference between the central lines (Figure 1, A).³ We have developed a simple and reproducible measurement method we call *effective height* as opposed to the traditional measurement. This measurement allows for identification of individual cusps and assessment of pro-

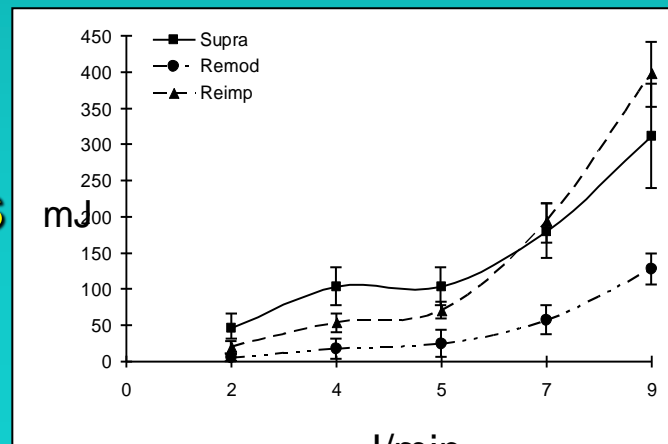
Reimplantation



Remodeling



Systolic Energy Loss



2 l/min

In vitro comparison of aortic valve movement after valve-preserving aortic replacement

Roland Fries, MD,^a Thomas Graeter, MD,^b Diana Aicher, MD,^b Helmut Reul, MD,^c Christoph Schmitz,^c Michael Böhm, MD,^a and Hans-Joachim Schäfers, MD^b

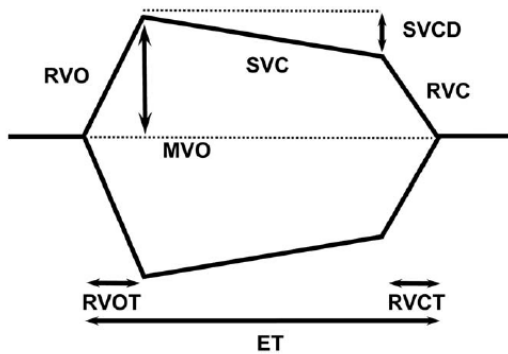


Figure 2. Schematic of the valve-motion pattern. *RVO*, Rapid valve opening; *SVC*, slow valve closing; *SVCD*, slow valve-closing displacement; *RVC*, rapid valve closing; *MVO*, maximum valve opening; *RVOT*, rapid valve-opening time; *RVCT*, rapid valve-closing time; *ET*, ejection time.

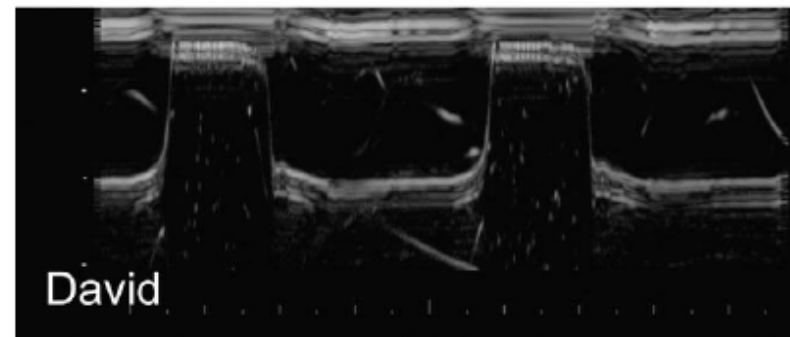



Figure 3. Typical M-mode recording of aortic valve motion after reimplantation (*David*) and remodeling (*Yacoub*).

Titel des Vortrags und Verfasser (bitte im Folienmaster anpassen)

	Remodeling (N=494)	Reimplantation (N=29)
Age (yrs)	58 ± 15	42 ± 16
Sex (m/f)	372 / 122	20 / 9
Tricuspid AV	333	27
BAV/UAV	154/7	2/-
Diagnosis: Aneurysm	428	23
AADA	59	6
CADA	7	-
Marfan	13	12

Titel des Vortrags und Verfasser (bitte im Folienmaster anpassen)

	Remodeling (N=494)	Reimplantation (N=29)
Concomitant procedures		
CABG	89*	1
MVR	16	1
part. arch	131*	8
tot. arch	26	2
Myoc. Ischemia (min)	82 ± 20*	112 ± 24

* p<0.05

Aortic root remodeling: Ten-year experience with 274 patients

Diana Aicher, MD, Frank Langer, MD, Henning Lausberg, MD, Benjamin Bierbach, MD, and Hans-Joachim Schäfers, MD

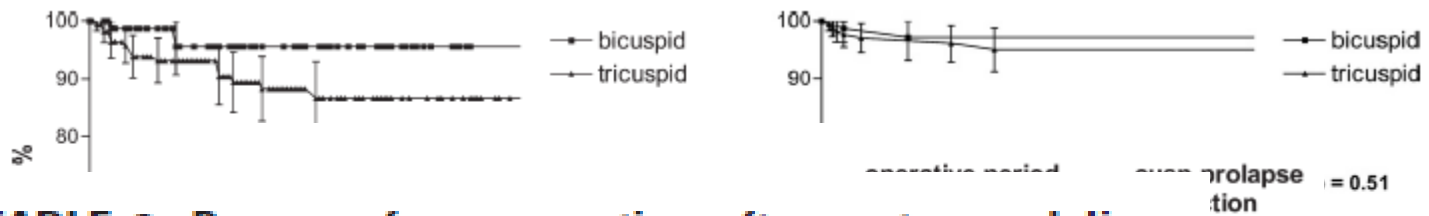


TABLE 3. Reasons for reoperation after root remodeling, stratified for aortic valve anatomy

Reasons for reoperation	BAV	TAV
Symmetric cusp prolapse	2	4
Dilatation at the aortoventricular level	0	1
Endocarditis	0	1
Secondary cusp retraction	0	1

BAV, Bicuspid aortic valve; TAV, Tricuspid aortic valve.



Valve-Sparing Surgery

Cusp Changes after Reimplantation

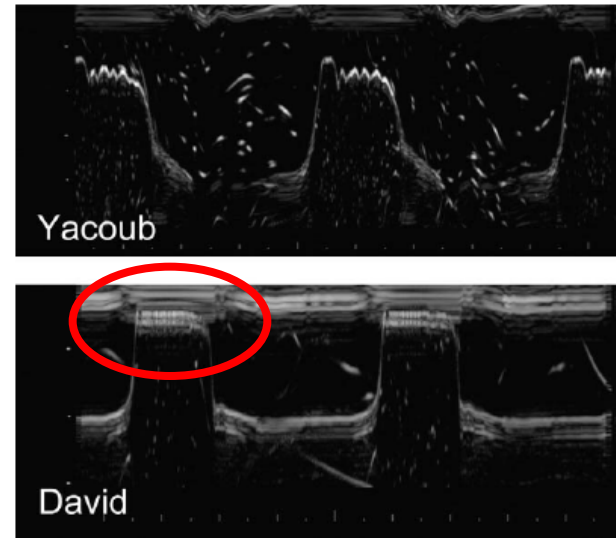
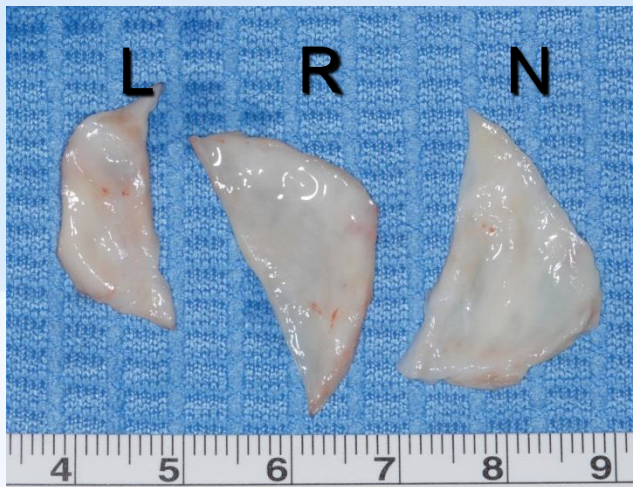


Figure 3. Typical M-mode recording of aortic valve motion after reimplantation (*David*) and remodeling (*Yacoub*).

In vitro comparison of aortic valve movement after valve-preserving aortic replacement

Roland Fries, MD,^a Thomas Graeter, MD,^b Diana Aicher, MD,^b Helmut Reul, MD,^c Christoph Schmitz,^c Michael Böhm, MD,^a and Hans-Joachim Schäfers, MD^b

Valve-Sparing Surgery

Cusp Changes after Reimplantation

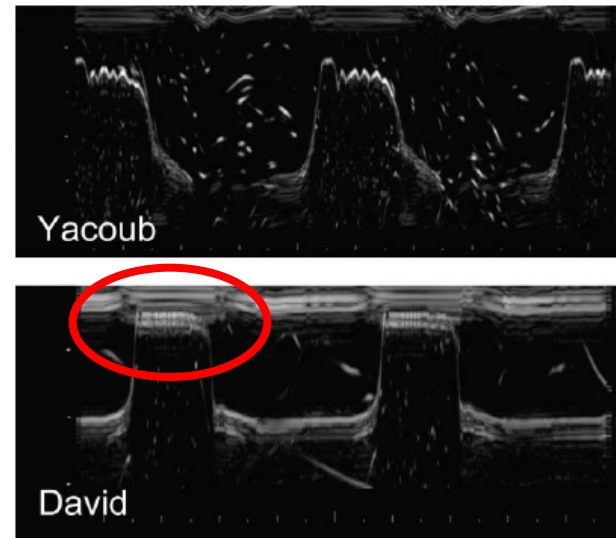

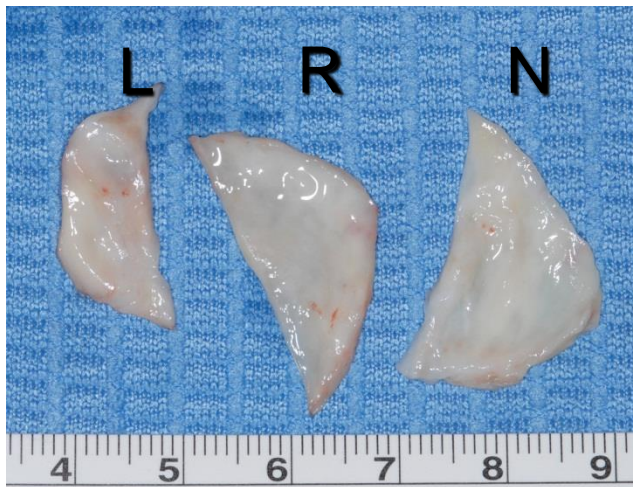


Figure 3. Typical M-mode recording of aortic valve motion after reimplantation (*David*) and remodeling (*Yacoub*).

In vitro comparison of aortic valve movement after valve-preserving aortic replacement

Roland Fries, MD,^a Thomas Graeter, MD,^b Diana Aicher, MD,^b Helmut Reul, MD,^c Christoph Schmitz,^c Michael Böhm, MD,^a and Hans-Joachim Schäfers, MD^b

Preoperative aortic root geometry and postoperative cusp

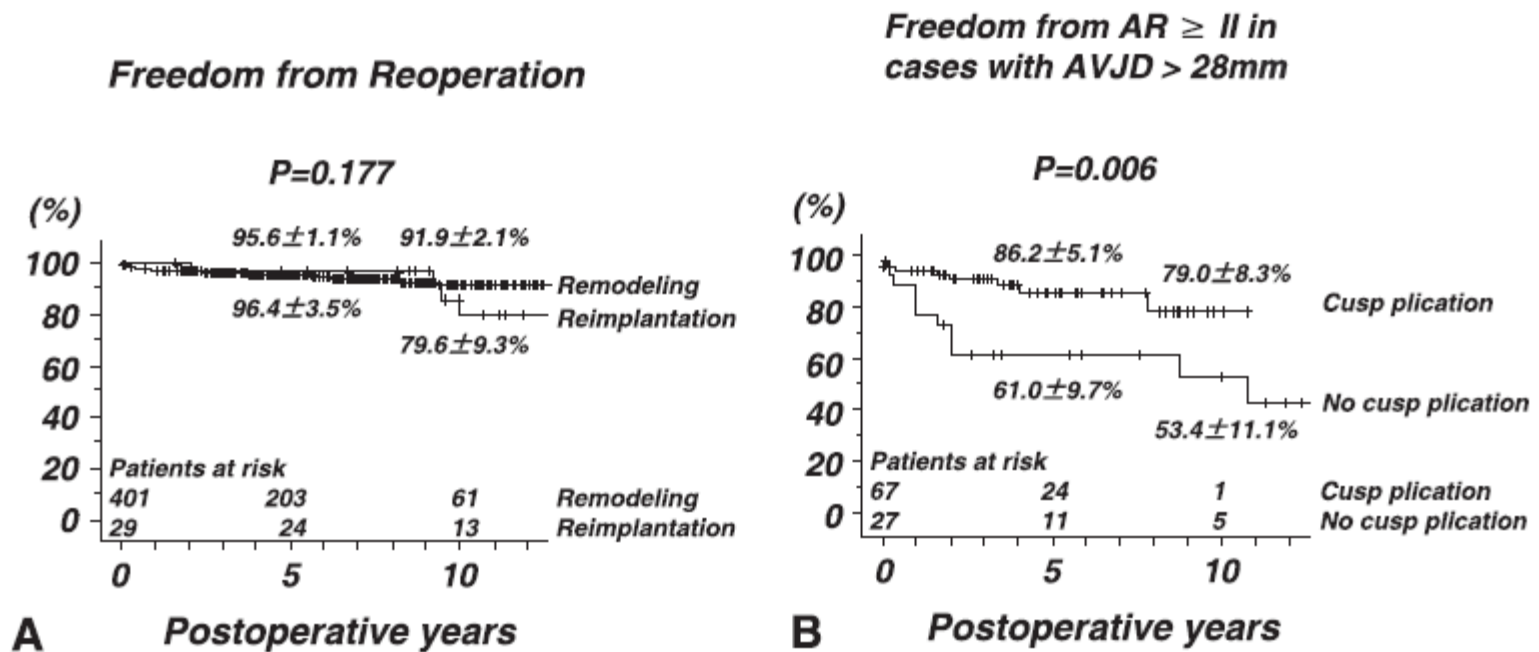
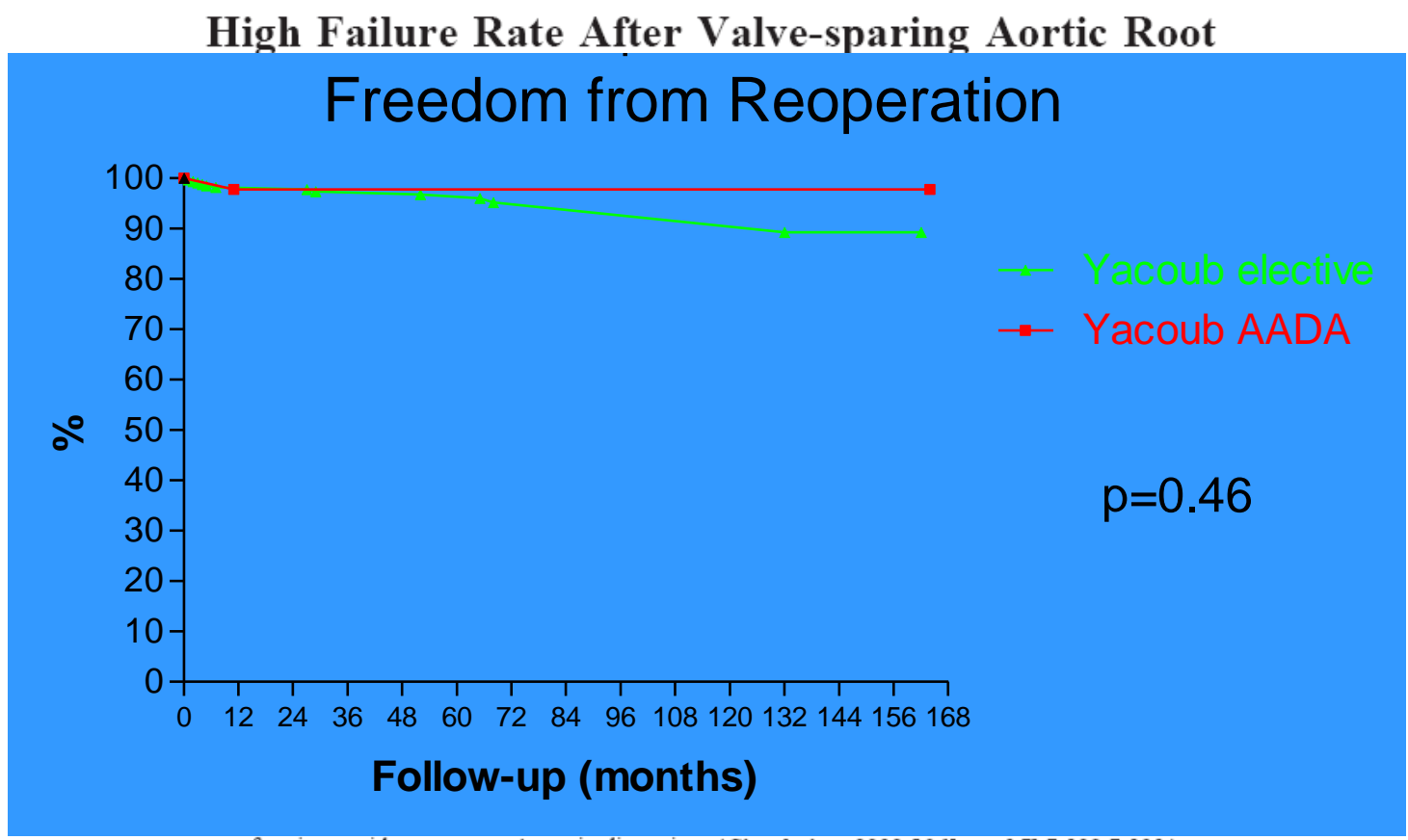


FIGURE 3. A and B, Freedom from reoperation of patients who underwent remodeling (*thin line*) or reimplantation (*bold line*).

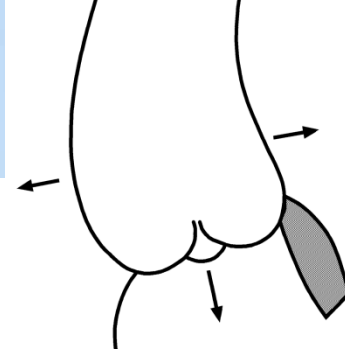
Failures (?)



treatment of patients with acute type A aortic dissection. (*Circulation*. 2002;106[suppl I]:I-229-I-233.)

Key Words: aneurysm ■ cardiovascular diseases ■ complications ■ valves

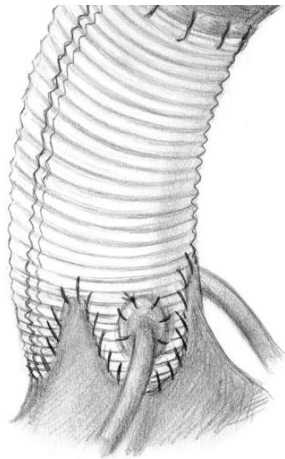
Root Repair – Technical Options



Subcommissural
Plication

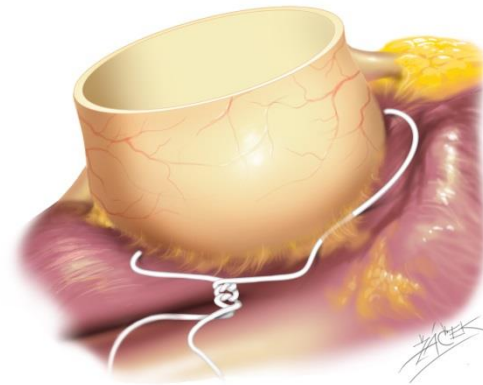


(Cabrol 1966)



Suture Annuloplasty
(AVJ > 27mm)

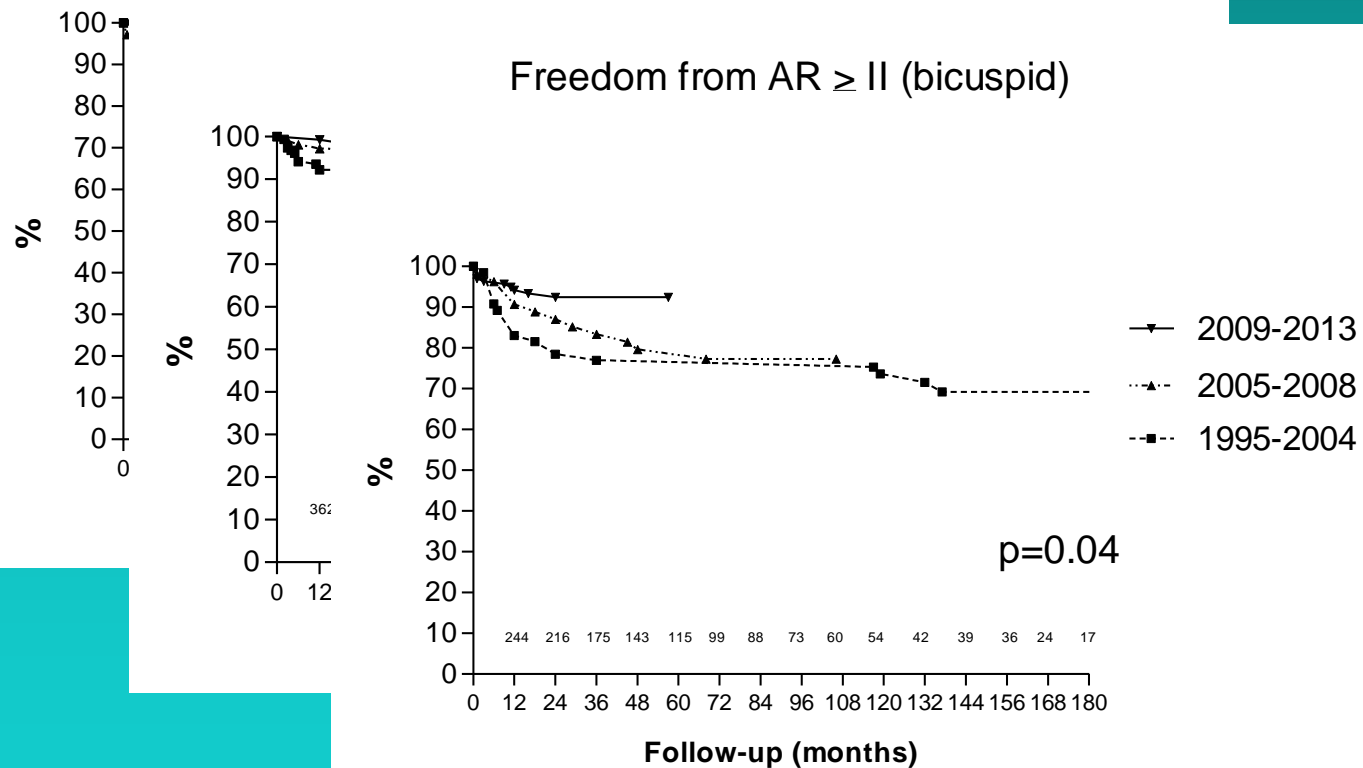
+



Root Remodeling - Long Term Results (>2004 eH, >2008 annuloplasty)

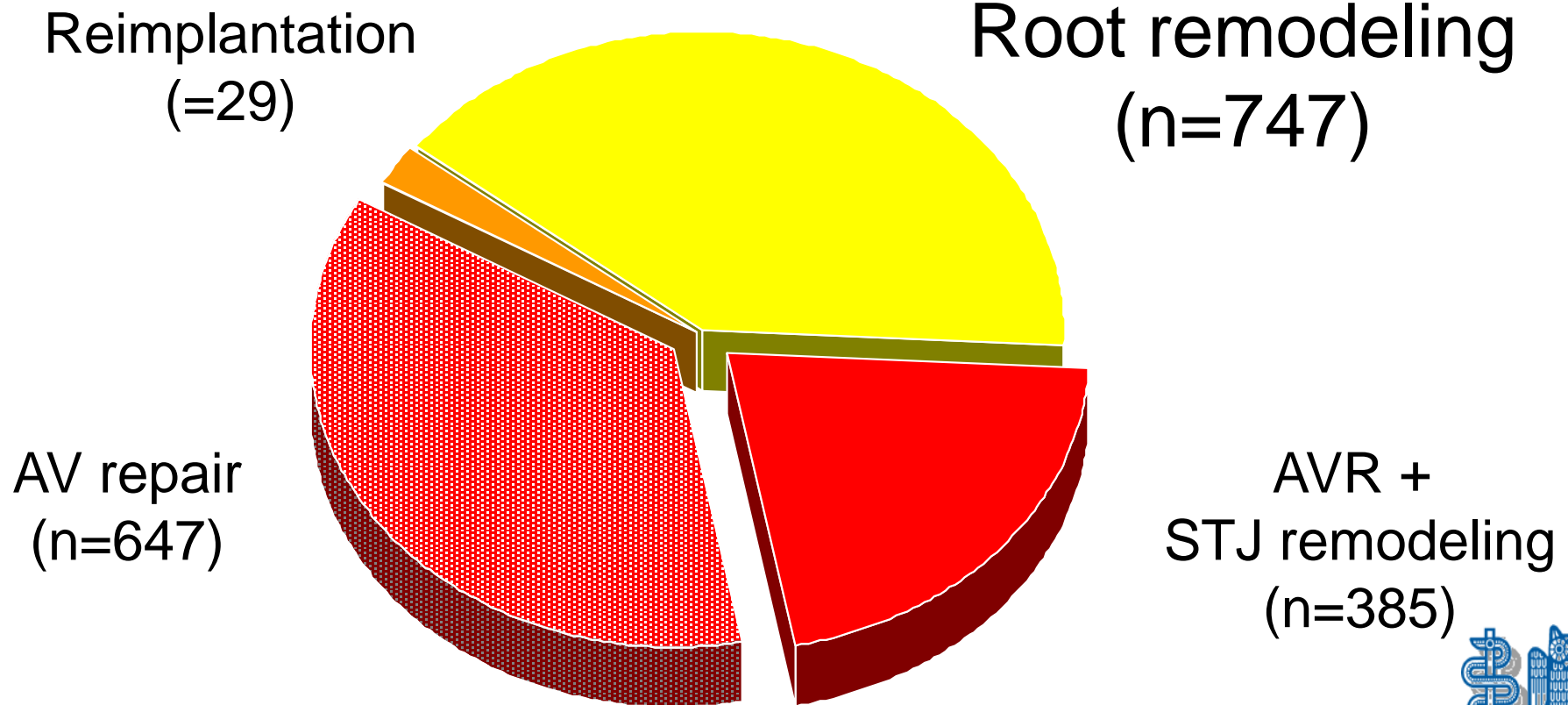
Freedom from Reoperation

Freedom from AR \geq II (tricuspid)



AORTIC VALVE REPAIR

n=1808



AV repair
(n=647)

Root remodeling
(n=747)

AVR +
STJ remodeling
(n=385)



Current Readings: Aortic Valve–Sparing Operations

Tirone E. David, MD^{*,†}

Semin Thoracic Surg 26:231–238 © 2014

aortic aneurysms and normal aortic annulus. Thus, both techniques are useful in preserving the aortic valve. With either technique, restoration of normal aortic annulus and cusp geometry is the single most important technical aspect of these operations. In addition to having a competent valve with no

this maneuver can correct the problem. Thus, selection of the size of the graft is a complex problem in aortic valve reimplantation. We have stated

in aortic valve reimplantation. We have stated numerous times that reimplantation of the aortic valve is a far more complex operation than remodel-

ing of the aortic root because it alters the geometry of root aneurysm associated with ascending aortic aneurysm and normal aortic annulus. Younger patients do very well after the remodeling procedure, which is technically less demanding than replacement of the aortic valve. Younger patients do very well after the remodeling procedure, which is technically less demanding than replacement of the aortic valve. Younger patients do very well after the remodeling procedure, which is technically less demanding than replacement of the aortic valve.

postoperatively.¹⁵ Finally, aortic valve–sparing operations are an alternative to composite replacement of the aortic valve and ascending aorta, and as there is no evidence of their superiority, the surgeon “has to have an open and receptive mind but a balanced view” of these operations and give the patient what is best in his or her hands.

Conclusions

Root remodeling requires shorter myocardial ischemia than valve reimplantation

RR can be applied in all instances (irrespective of sinus anatomy)

RR leads to near-physiologic cusp motion

RR may lead to more cusp prolapse (through smaller graft), but this can be detected and corrected easily (eH). Cusp configuration determines durability!

Addition of annuloplasty increases proportion of competent valves (durability?)

RR is my preferred form of valve-preserving root replacement, at least for all patients without connective tissue disease.